

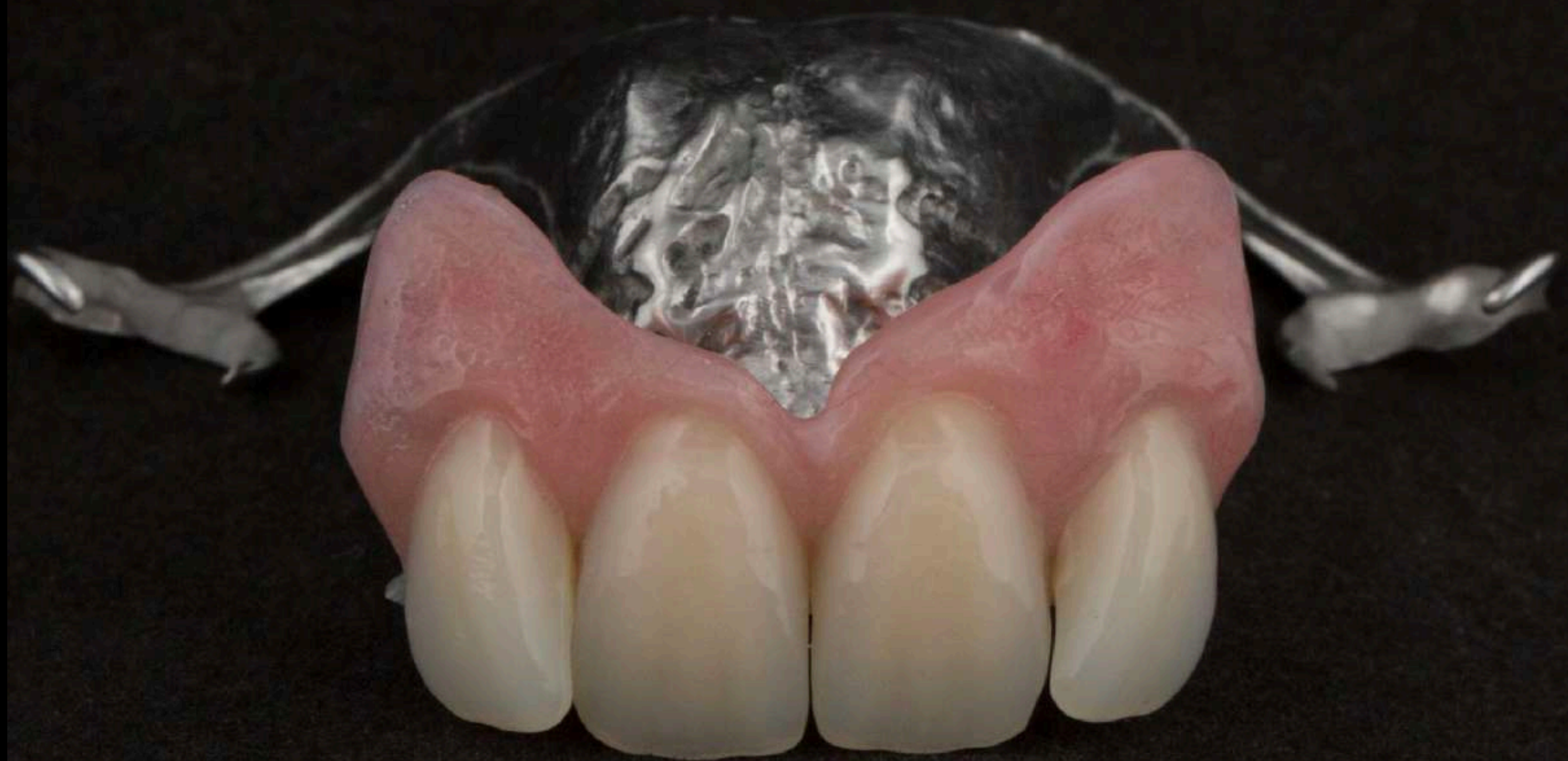The 7 top techniques

for making

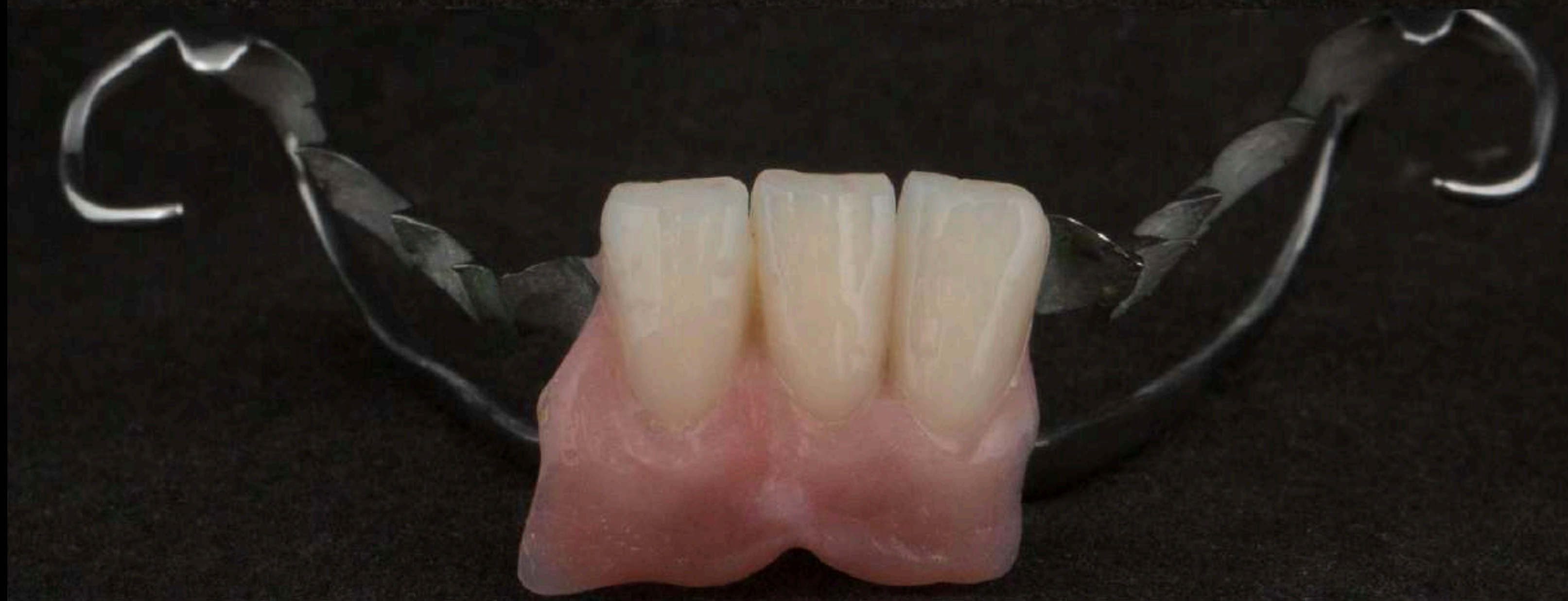superb dentures

Finlay Sutton

Life changing



Schottlander Enigmalign
teeth



Impressions

Occlusion

Aesthetics

RPD design

Denture fitting

Reviews

Patient management

I hated making dentures

Removable prosthodontics

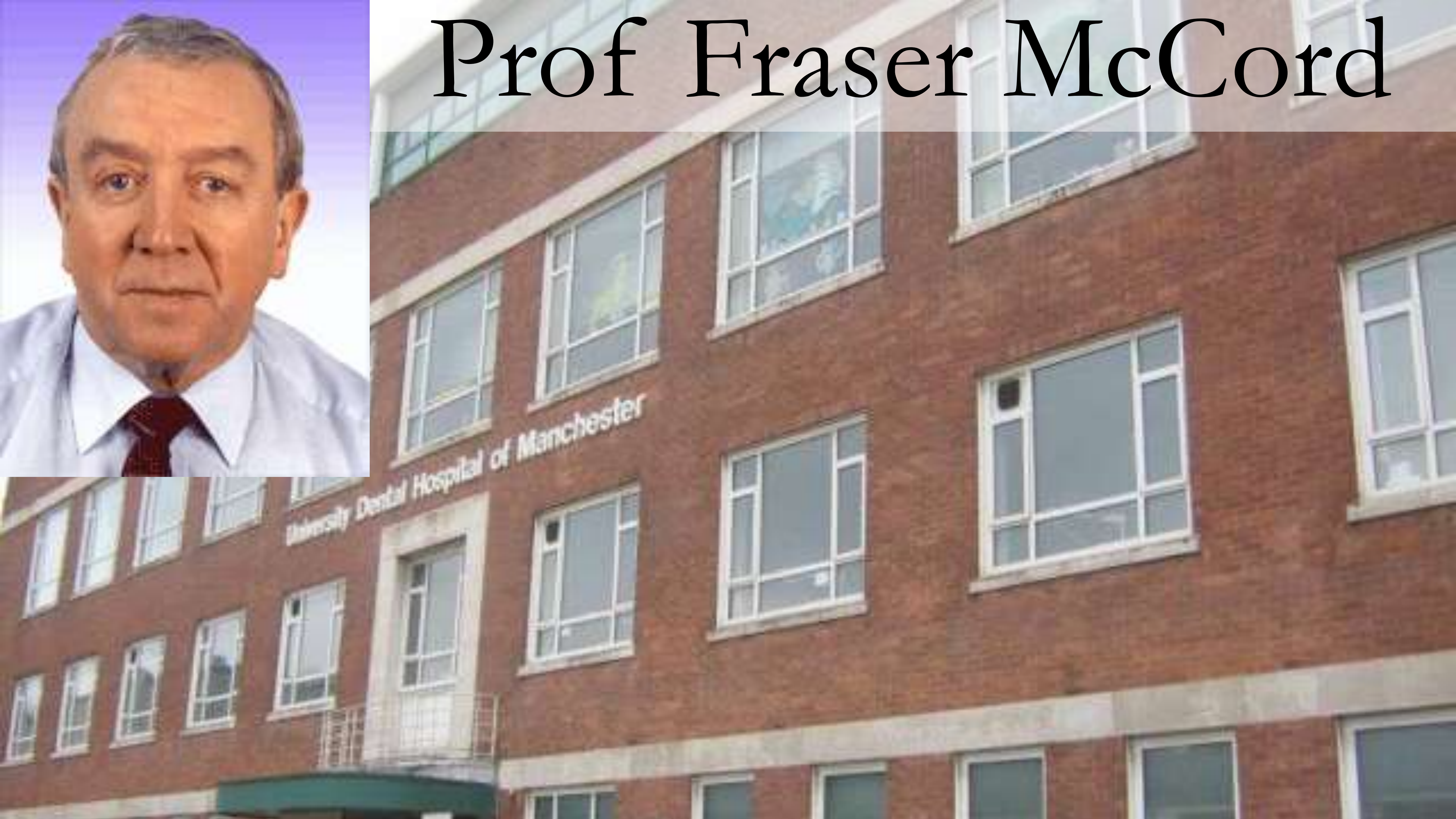is difficult

Dentistry

is difficult



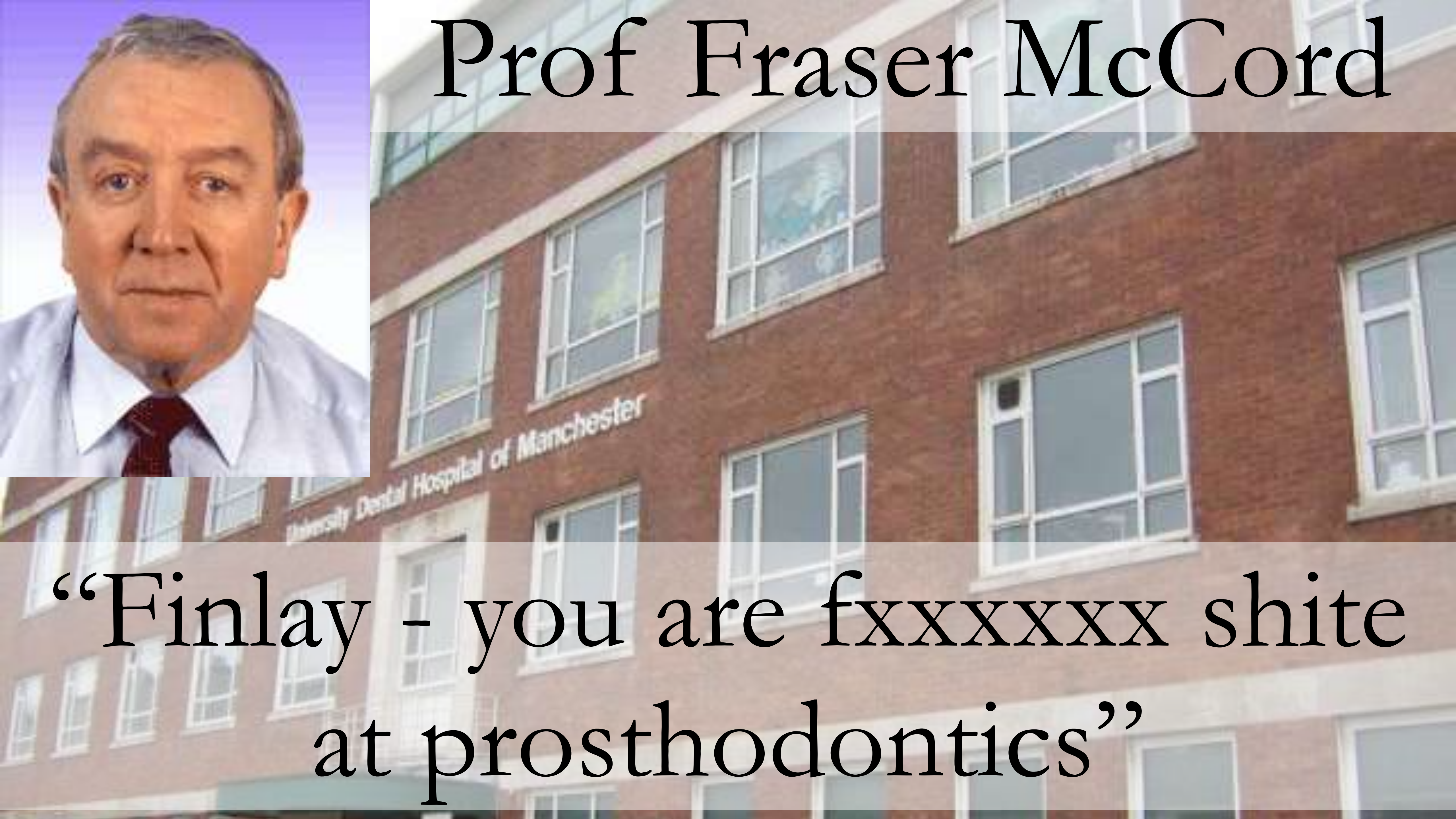
Prof Fraser McCord





Prof Fraser McCord

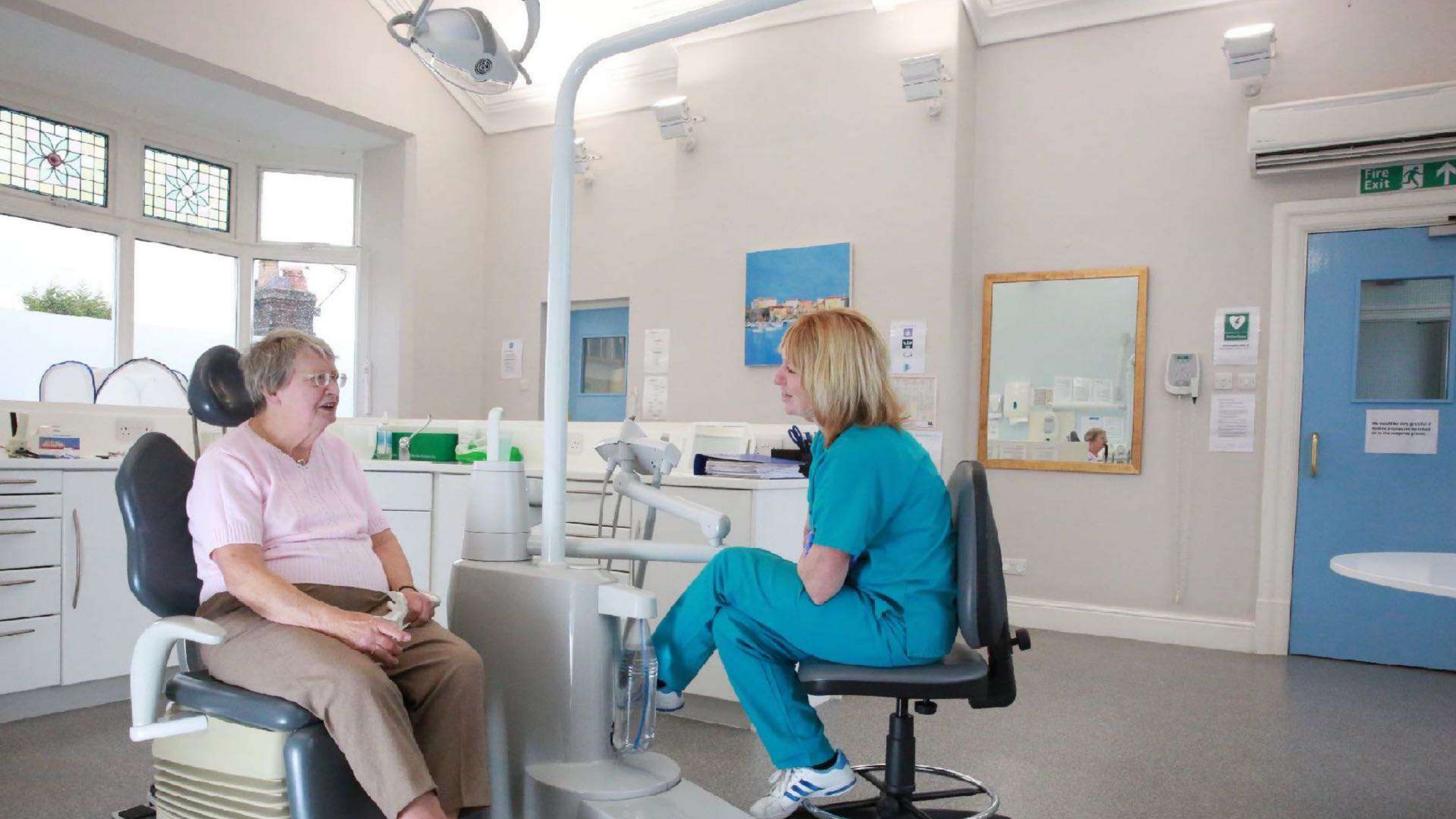“Finlay - you are fxxxxxx shite
at prosthodontics”

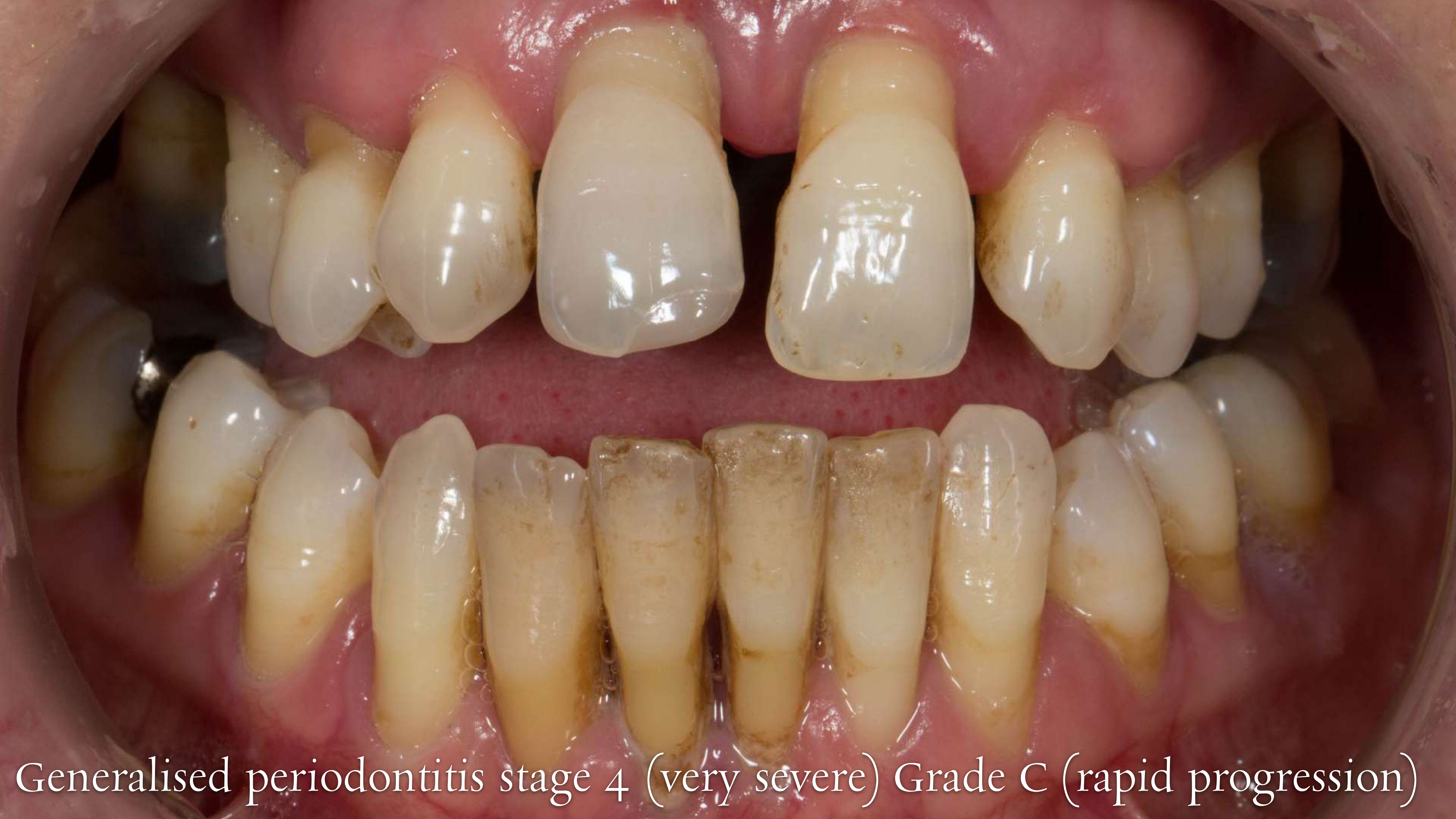



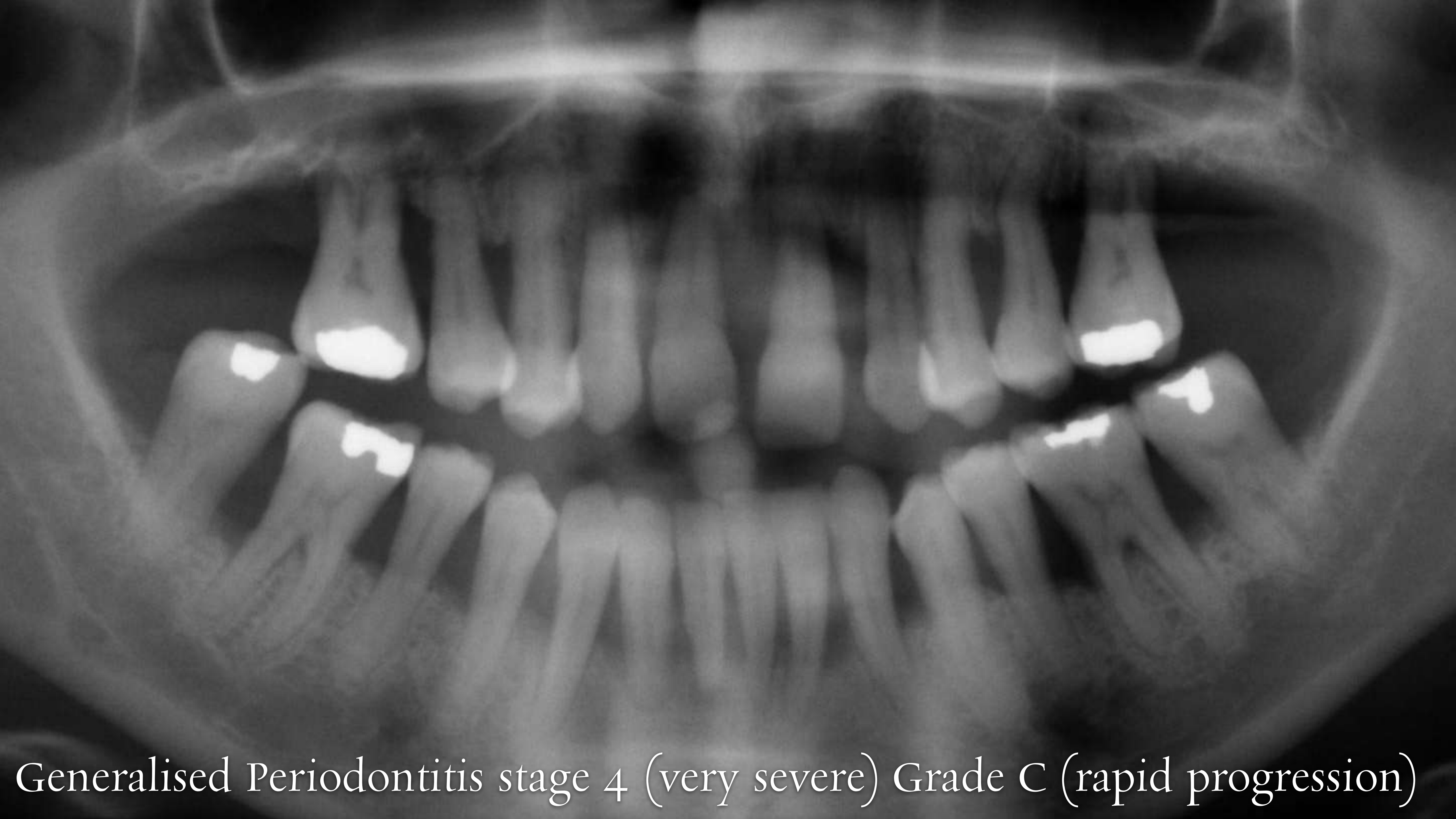Rowan Garstang
Technician



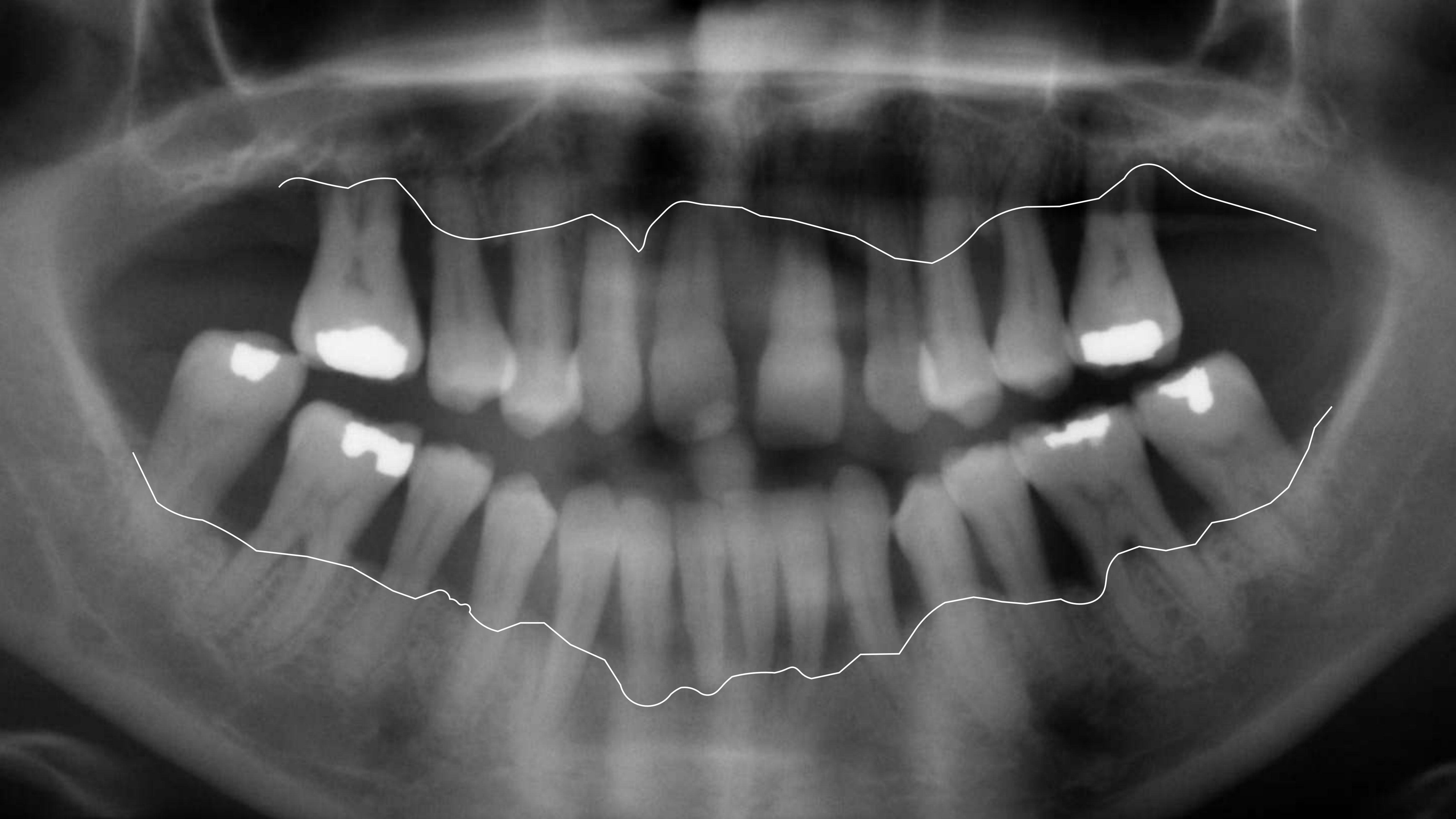


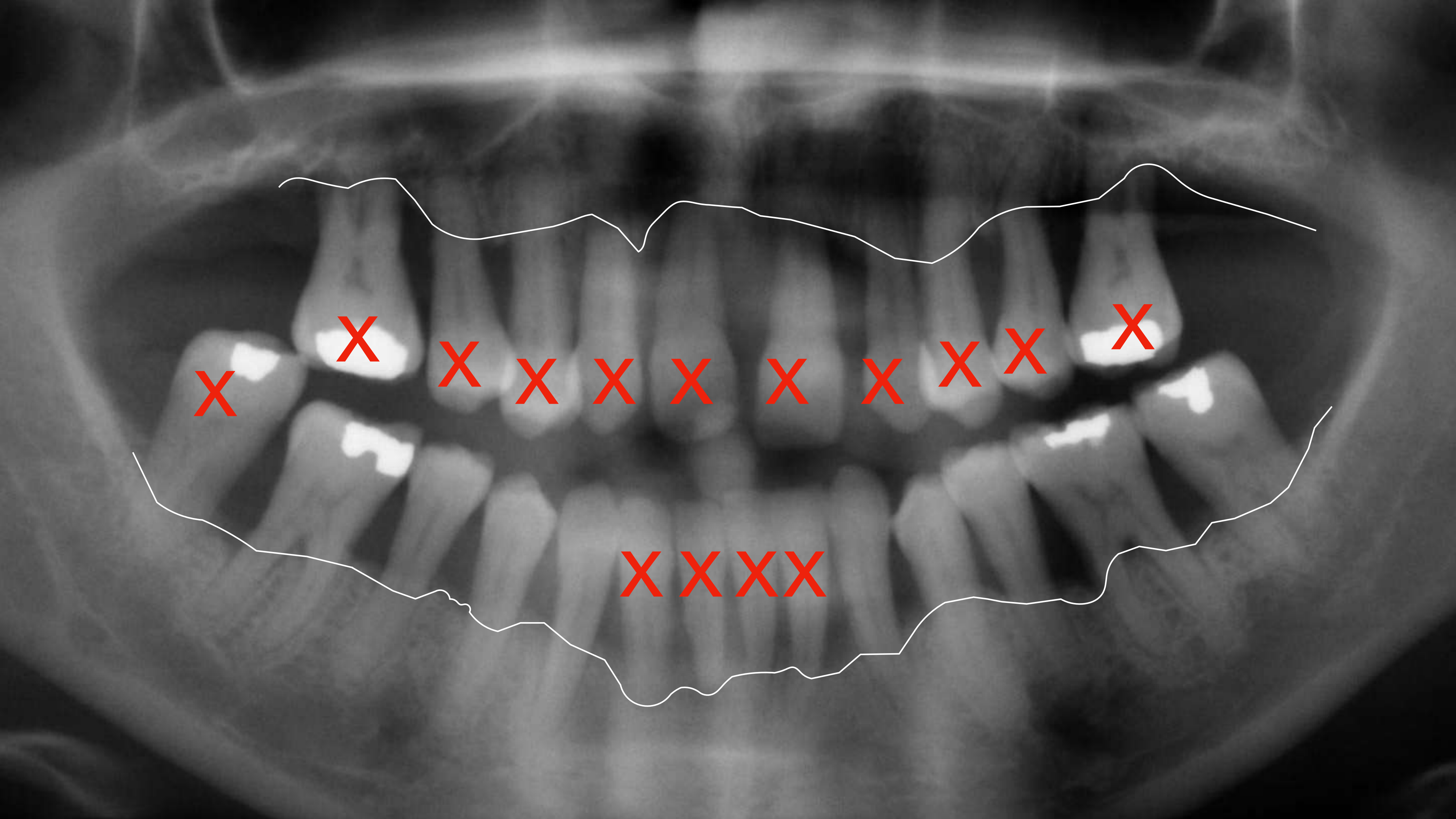


Generalised periodontitis stage 4 (very severe) Grade C (rapid progression)



Generalised Periodontitis stage 4 (very severe) Grade C (rapid progression)





X

X

X

X

X

X

X

X

X

X

X

X

X

X

X

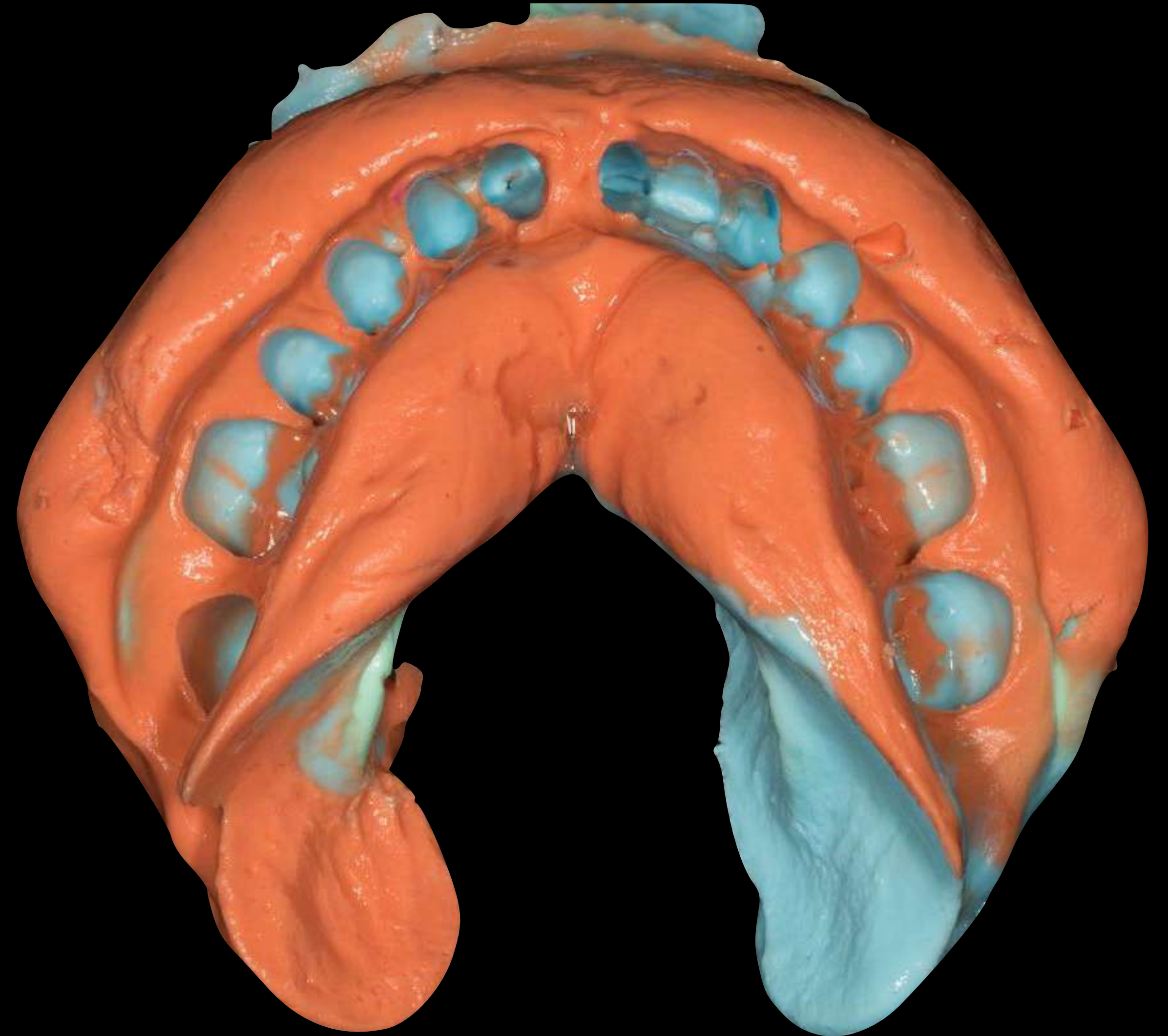
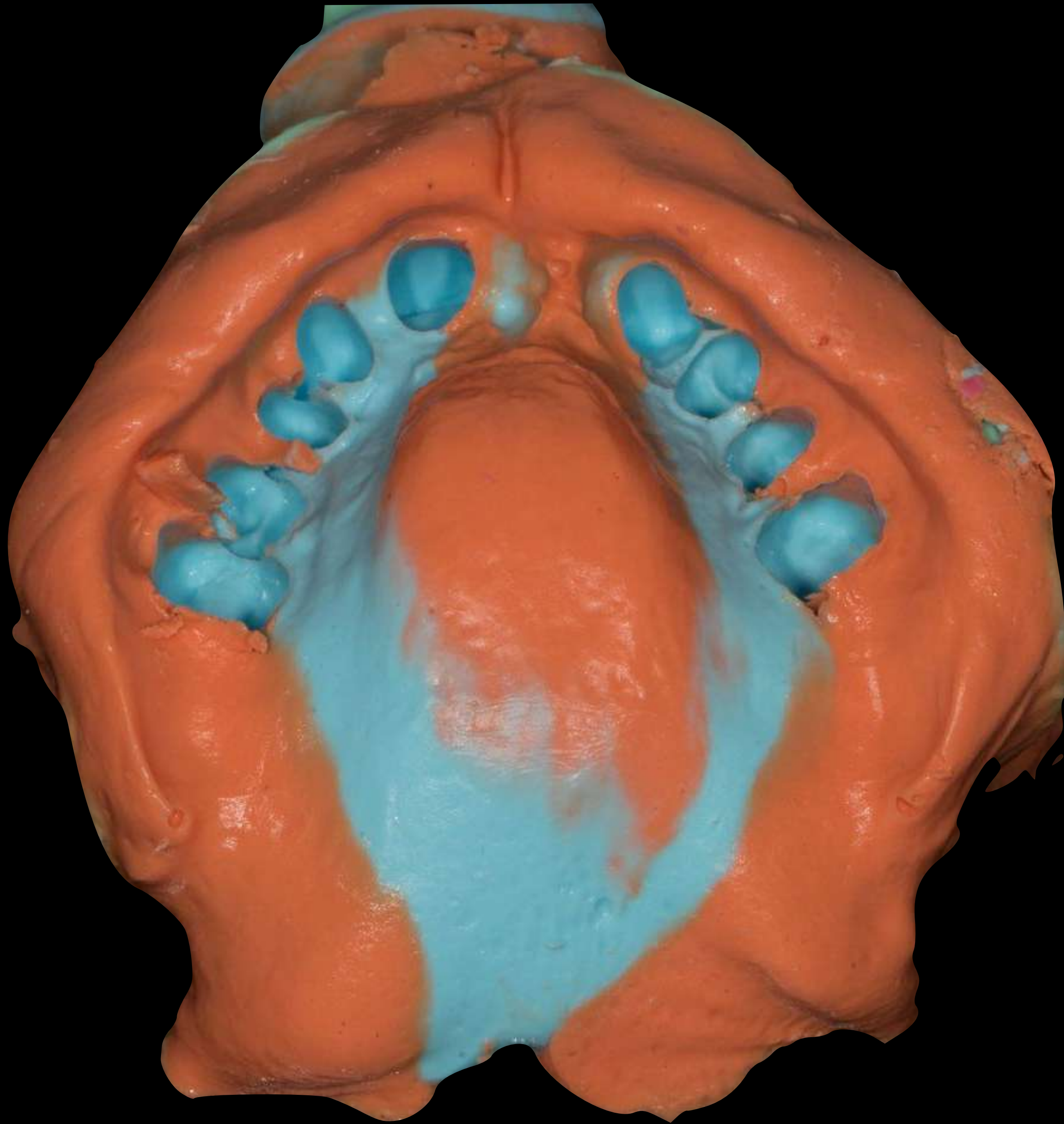

Stabilisation phase

C/P Immediates

NS periodontal therapy

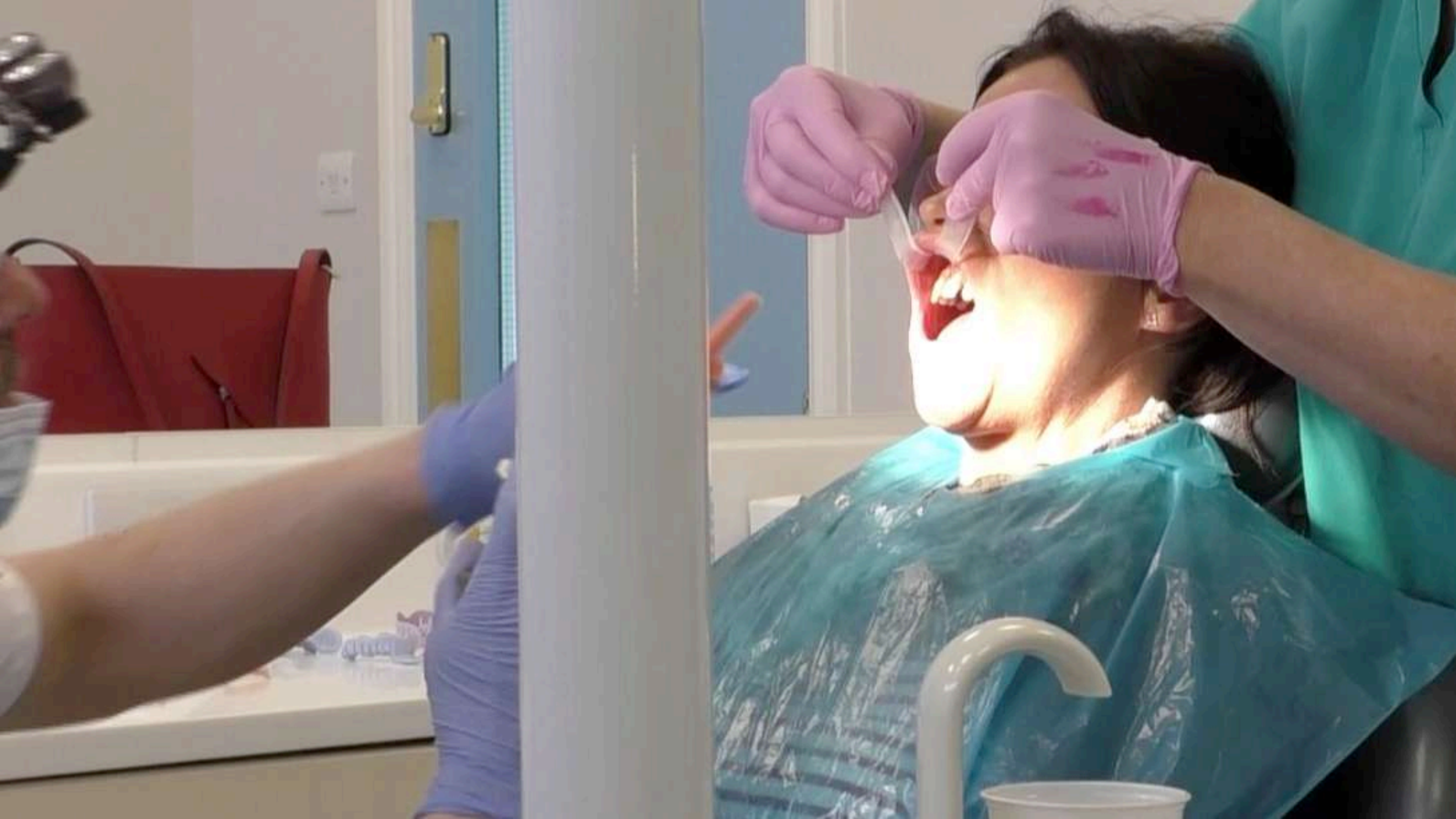Zhermack - Tropicalgin - Base
Neocolloid - Injectable

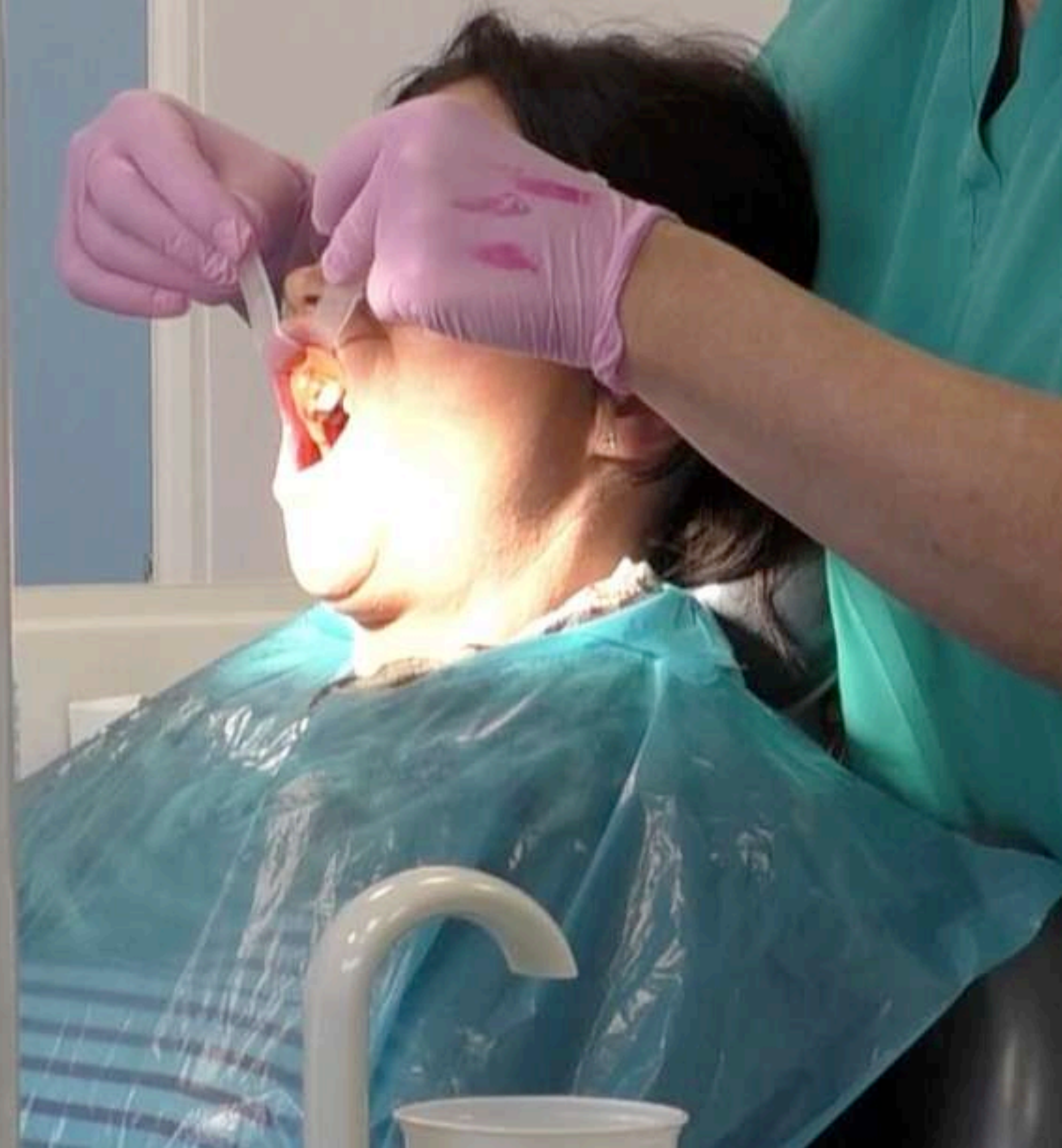
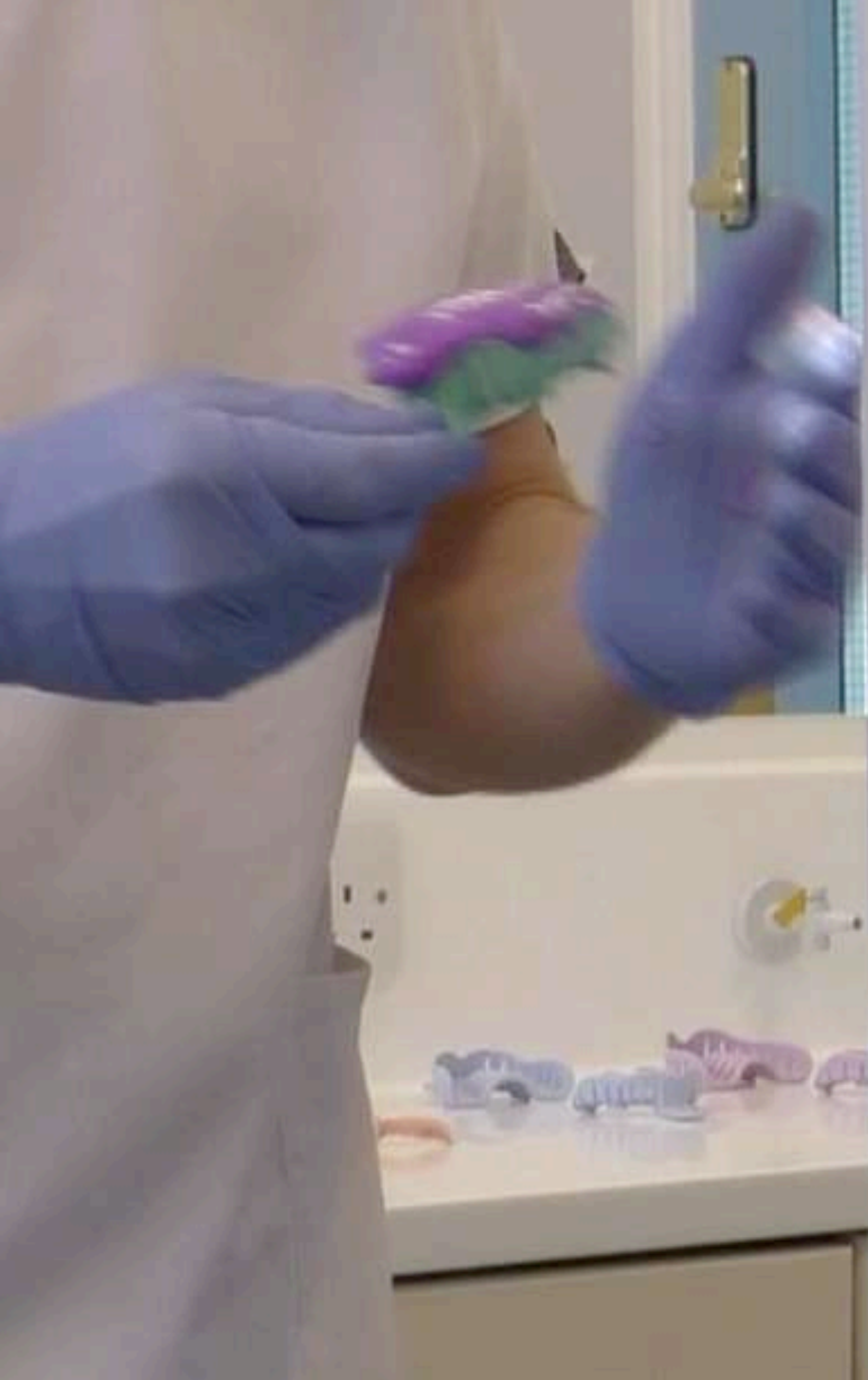


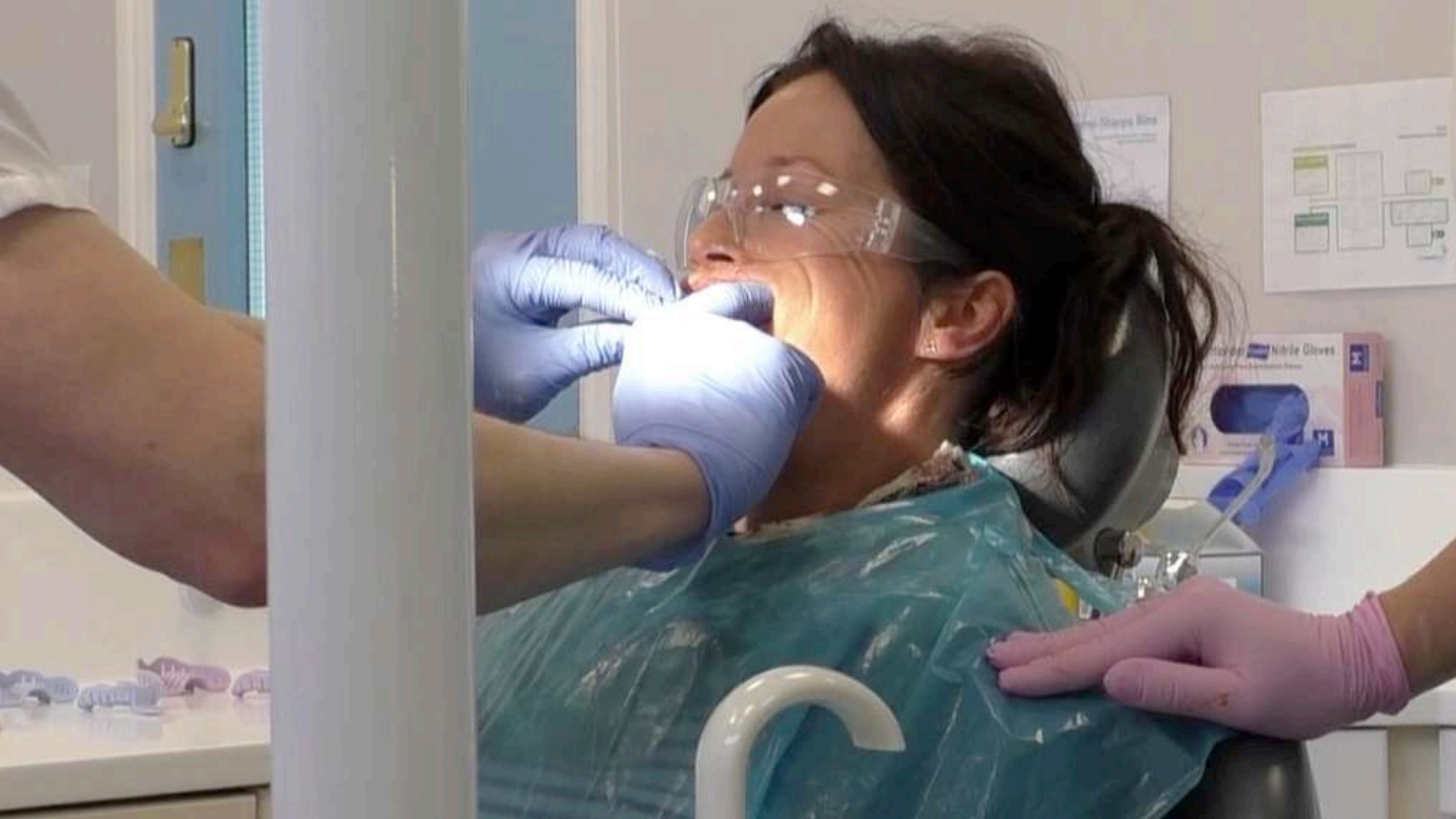Neocolloid - Injectable →

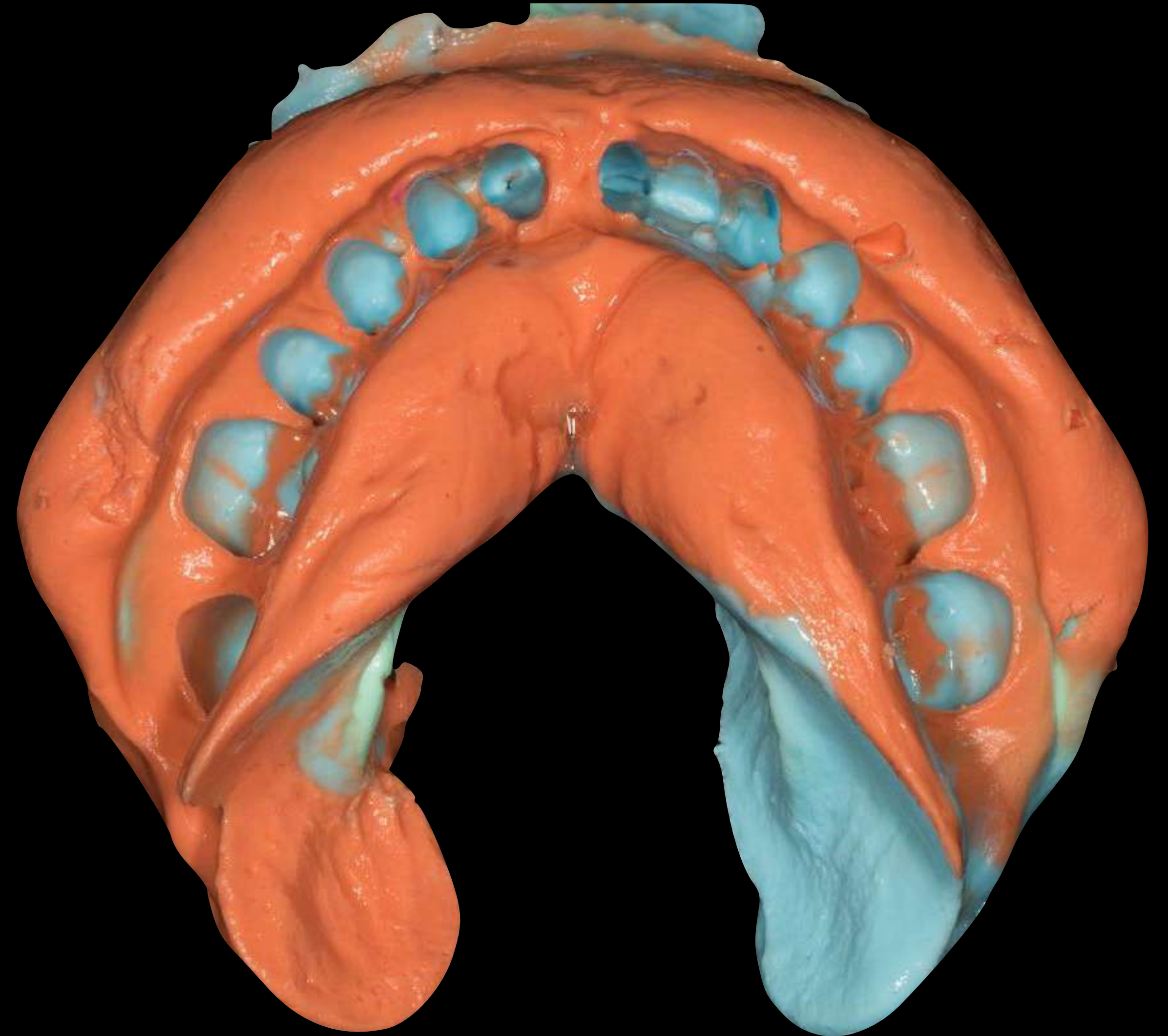
↑
Tropicalgin - Base



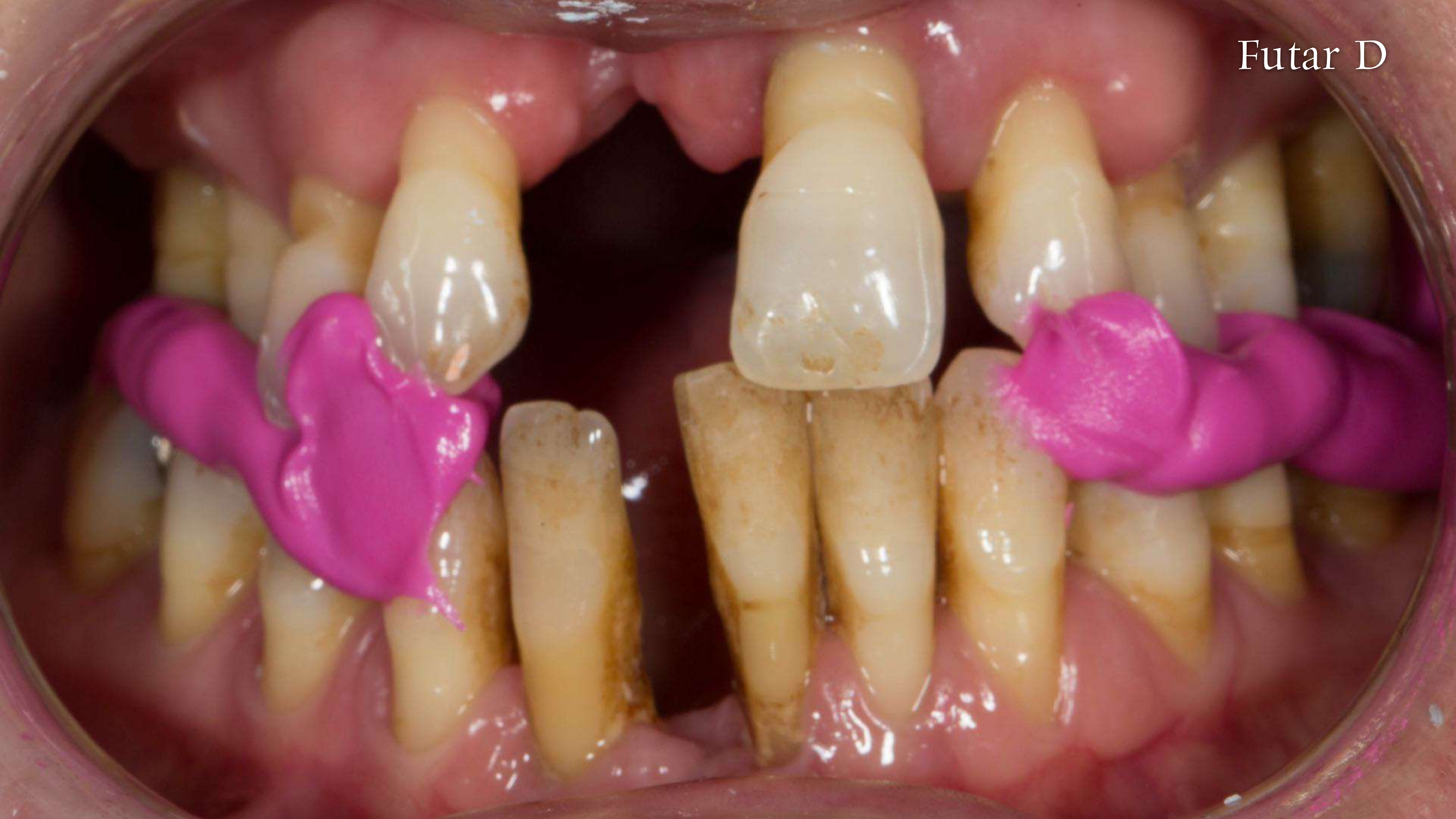


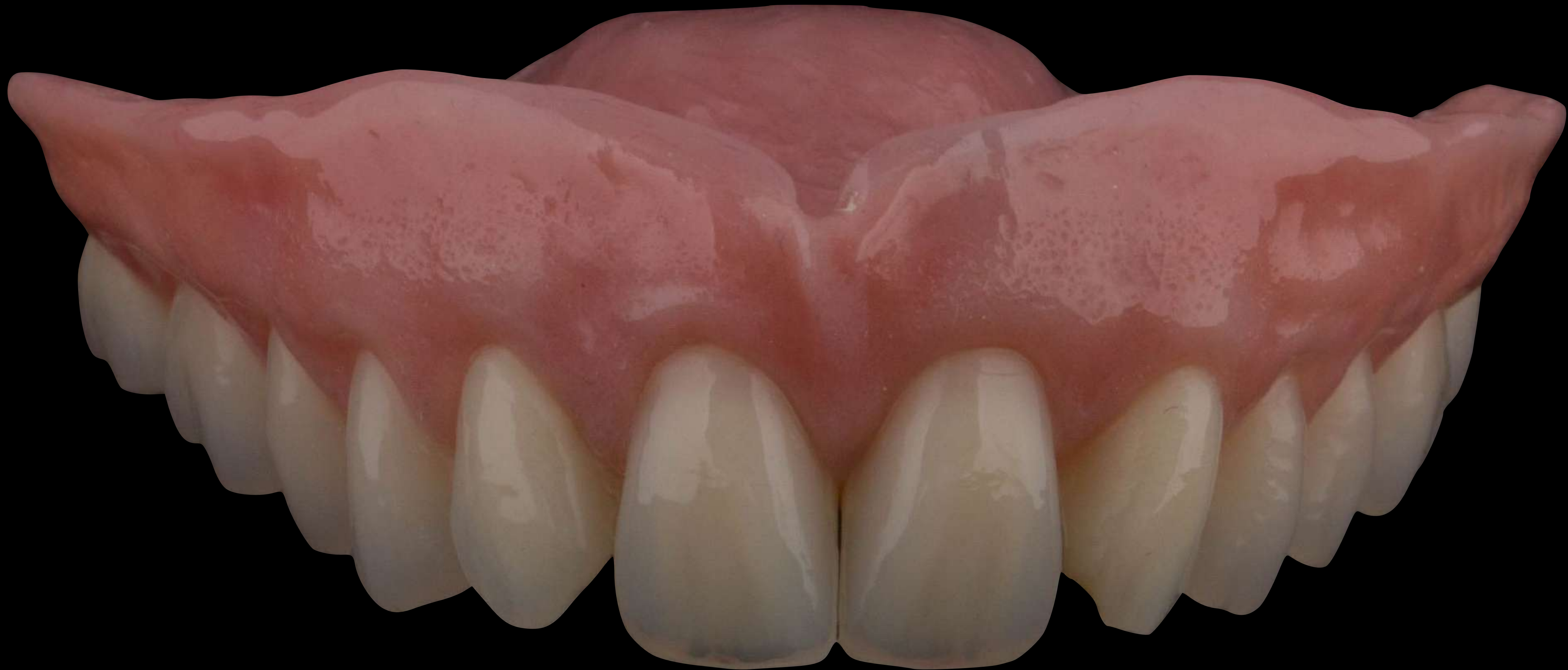
Zhermack - Tropicalgin - Base
Neocolloid - Injectable

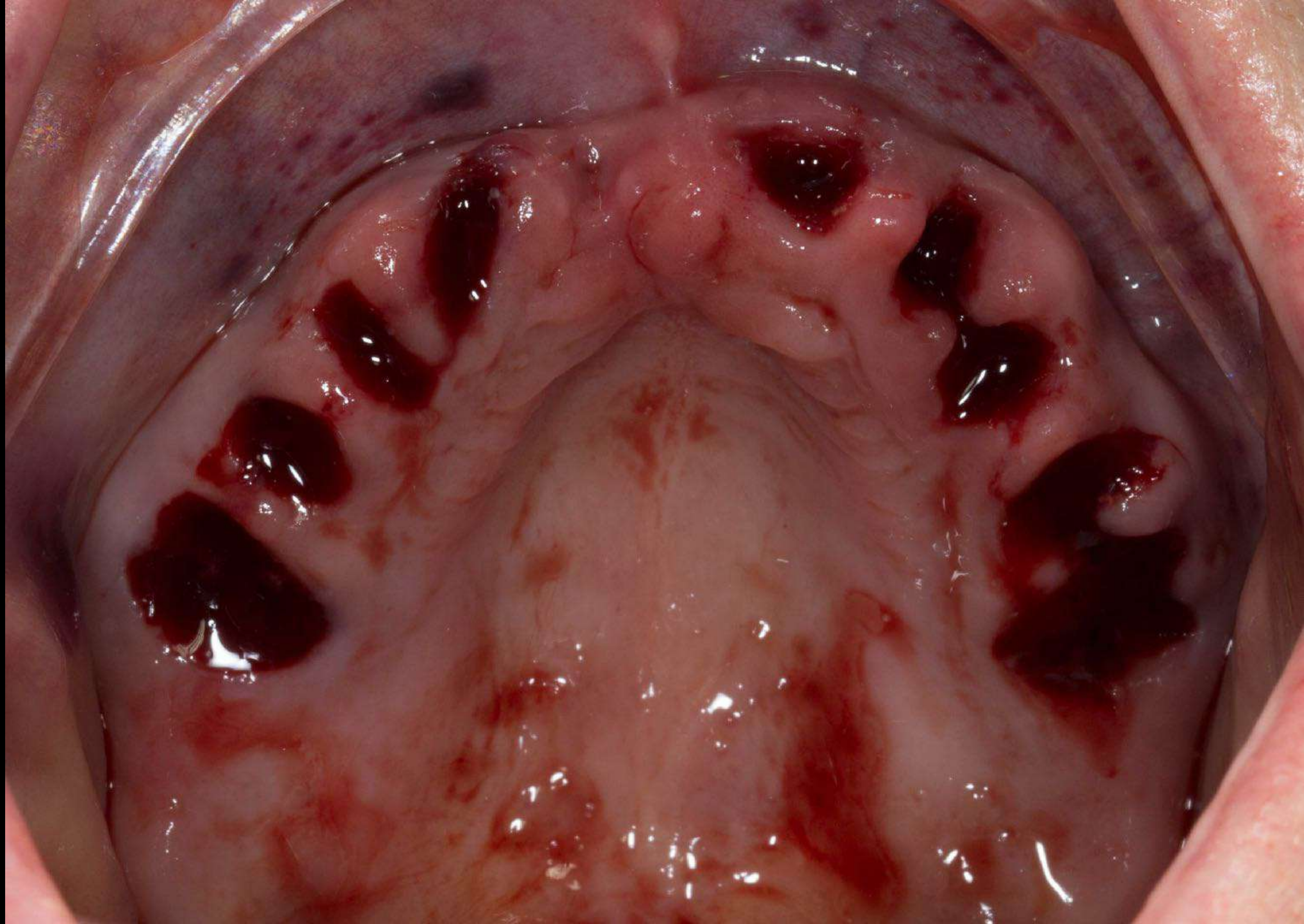


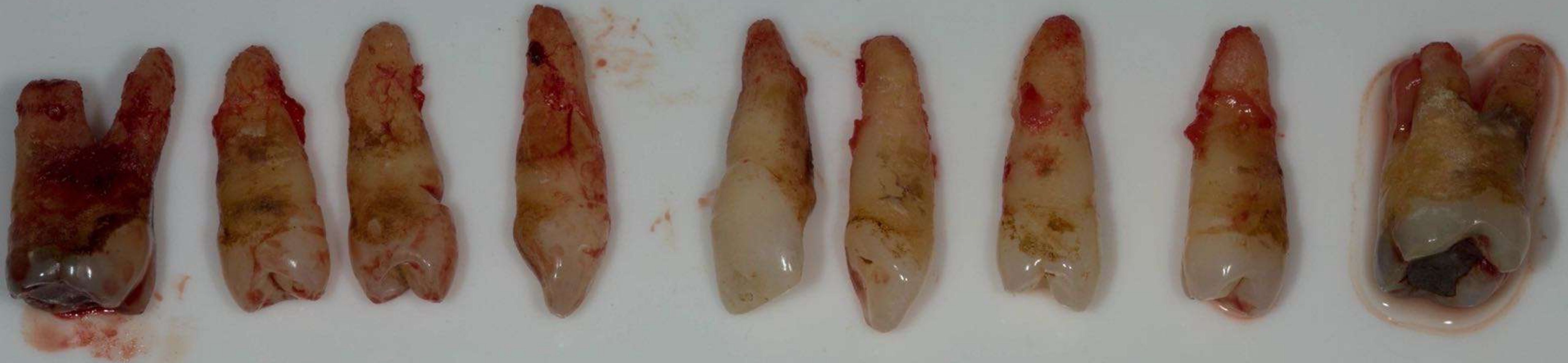Futar D

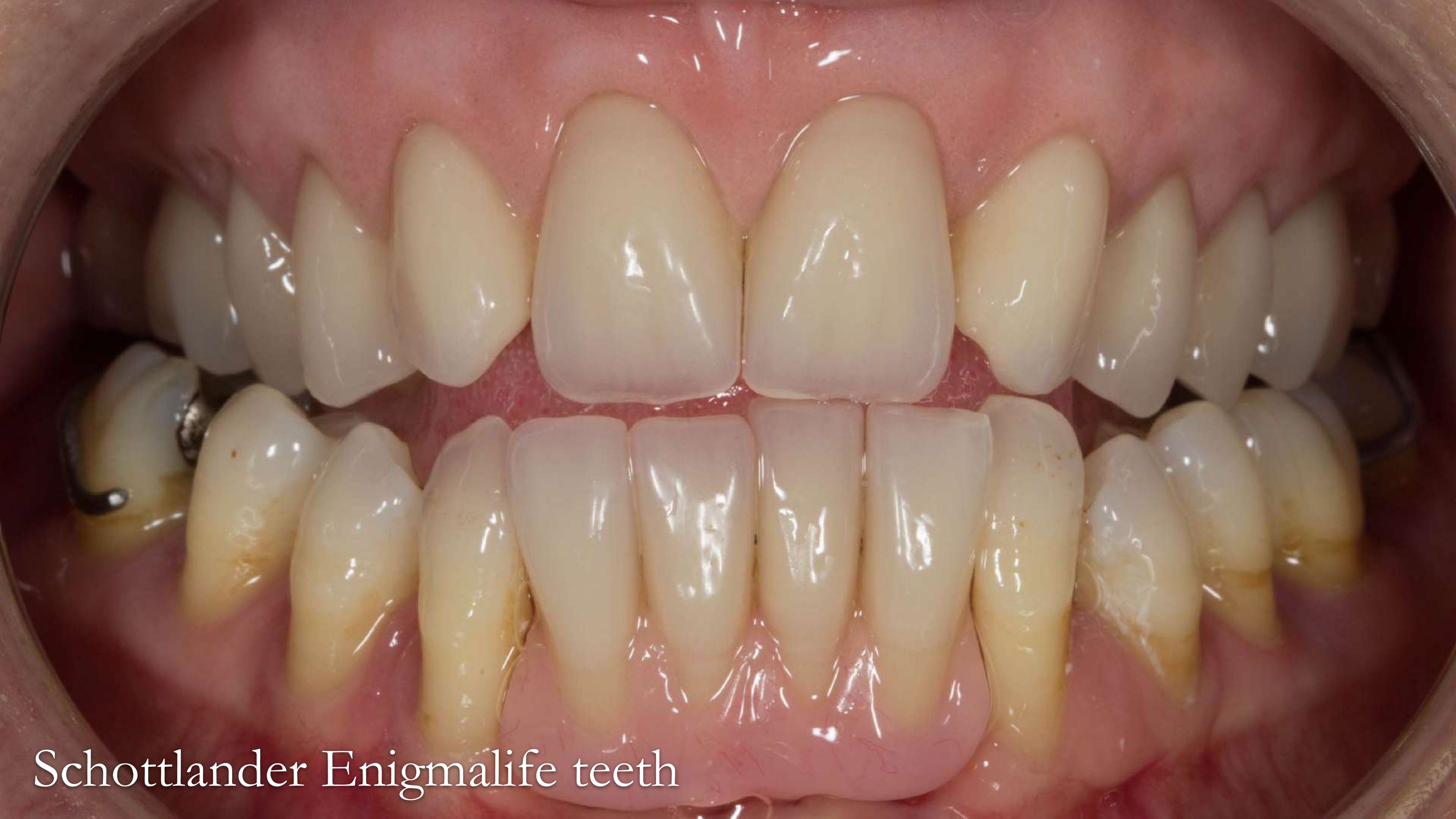



Schottlander Enigmalive teeth







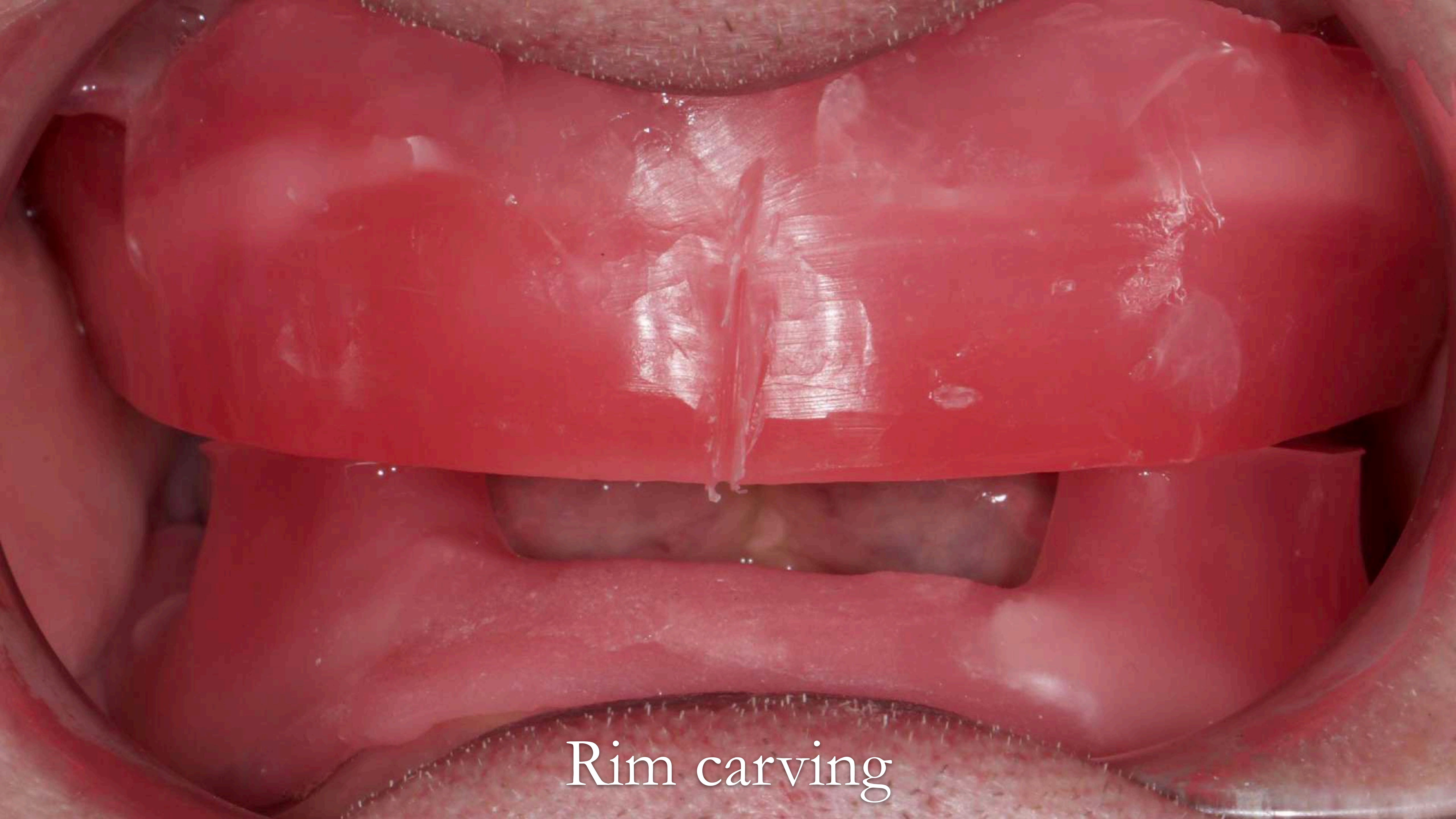
Schottlander Enigmalive teeth

loom.com
for post op
instructions

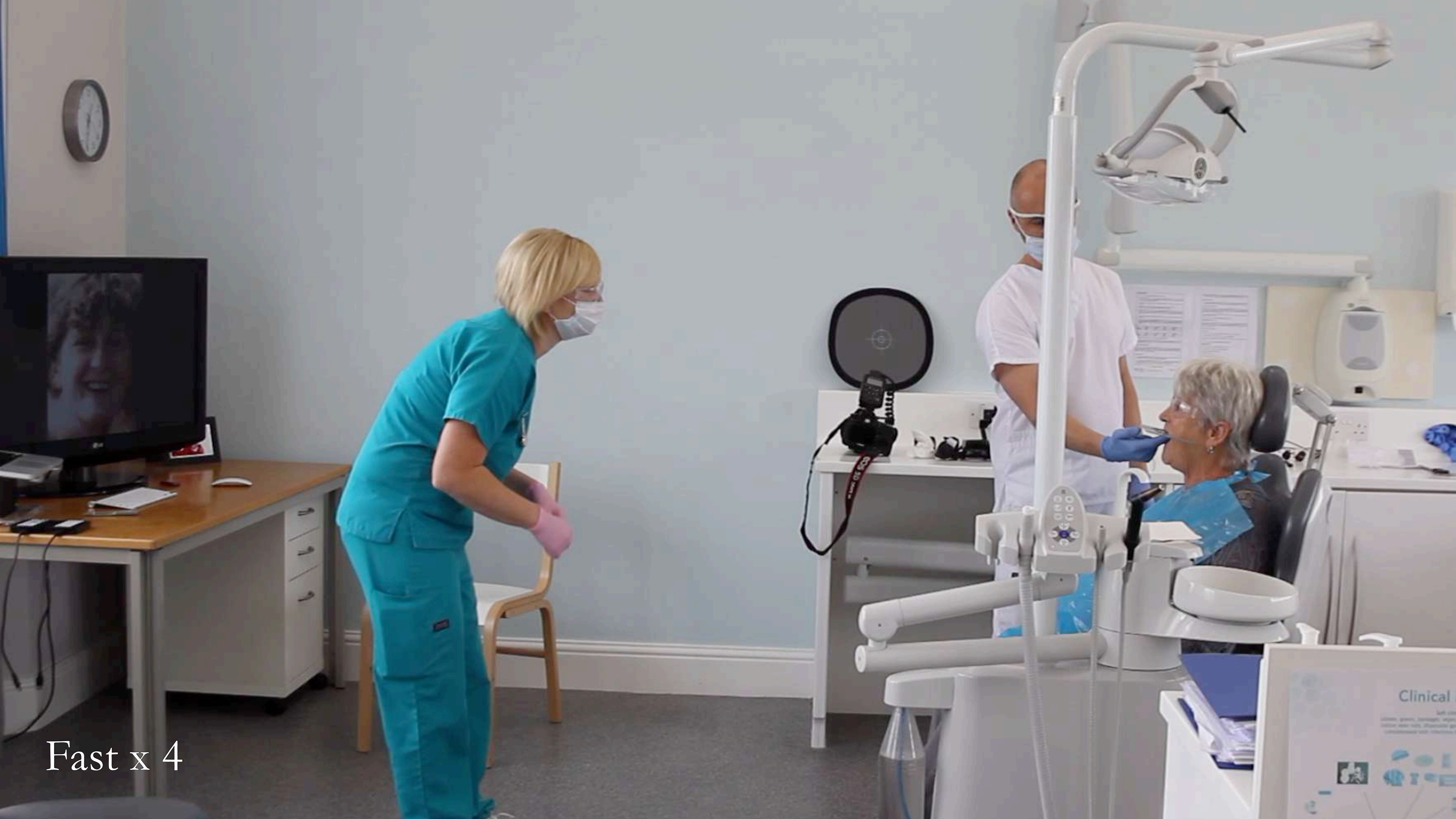The image is a composite screenshot. The primary focus is a Microsoft Word document titled "General Instructions Following Dental Extractions and Mouth Surgery 12-19" with a subtitle "Last Modified: 7 February". The document is in the "Home" tab, showing a ribbon with various formatting options. The main text of the document is titled "General instructions following tooth/teeth removal and or/mouth surgery" and contains a bulleted list of instructions: "Take the medication as explained to you. Even if there is no pain or discomfort, continue with pain killers as described:", "Avoid hot drinks for 4 hours until the anaesthetic wears off.", "AVOID RINSING OF THE AREA FOR THE FIRST 24 HOURS.", "Avoid drinking alcohol for 24 hours.", "Avoid exercise for 24 hours.", "Apply an ice pack (frozen peas) – wrapped in a tea towel to the outside of your face where the extractions/surgery have occurred for 20 minutes on, 20 minutes off as often as possible over the first 3 days.", "Only brush your teeth in the surgical area as directed", "After 24 hours - rinse your mouth after every meal, with warm salt water.", and "Swelling and/or bruising after extractions commonly occurs. If the swelling becomes red and/or hot". A circular video call window is overlaid on the right side of the document, showing a man in a white lab coat in a dental clinic. A "Welcome back!" notification bubble is visible near the video call. The background of the entire image is a blurred office environment with a desk, chair, and computer monitor. The bottom of the image shows a macOS dock with various application icons.



Achieving great aesthetics?



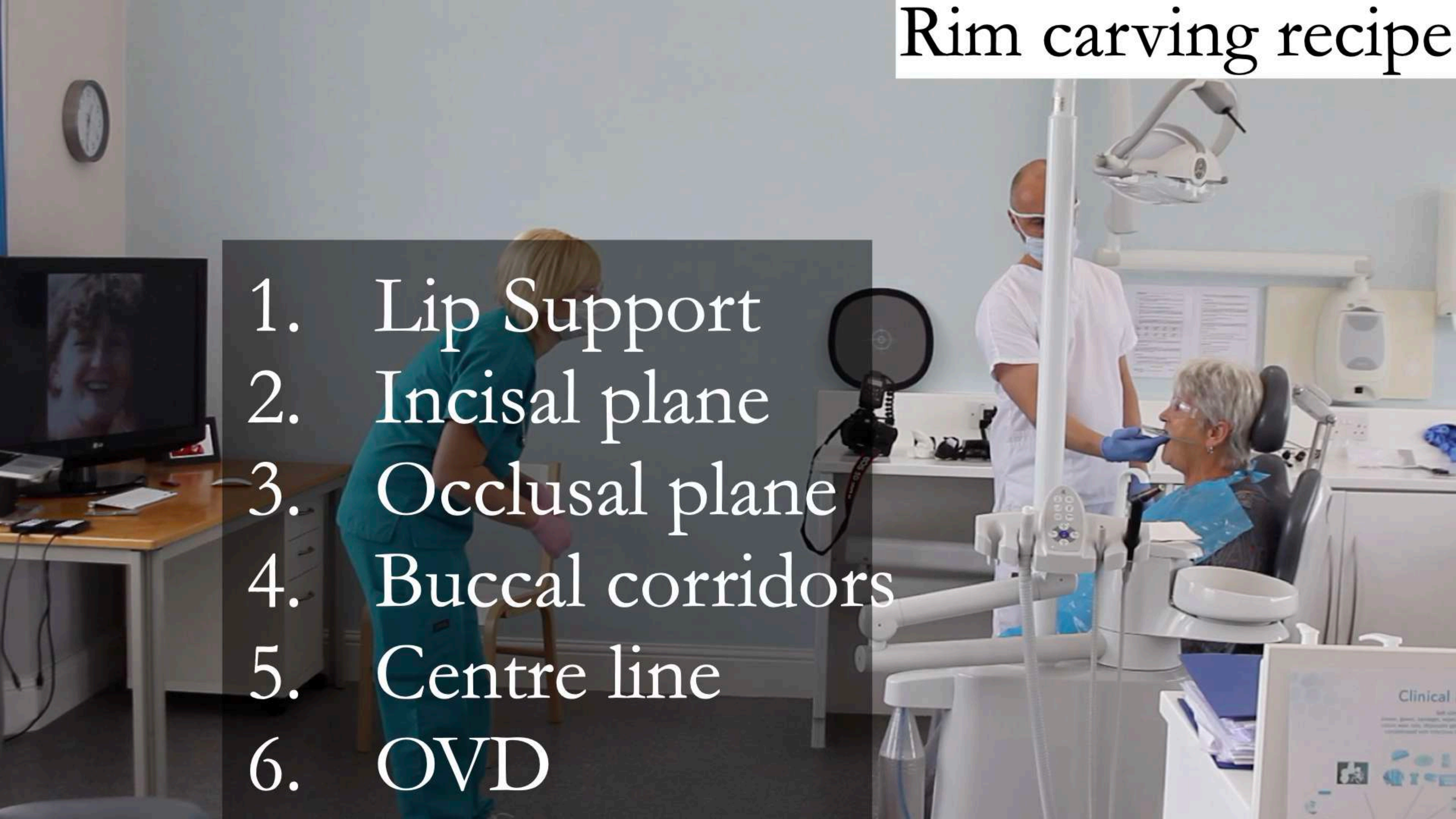
Rim carving



Fast x 4

Rim carving recipe

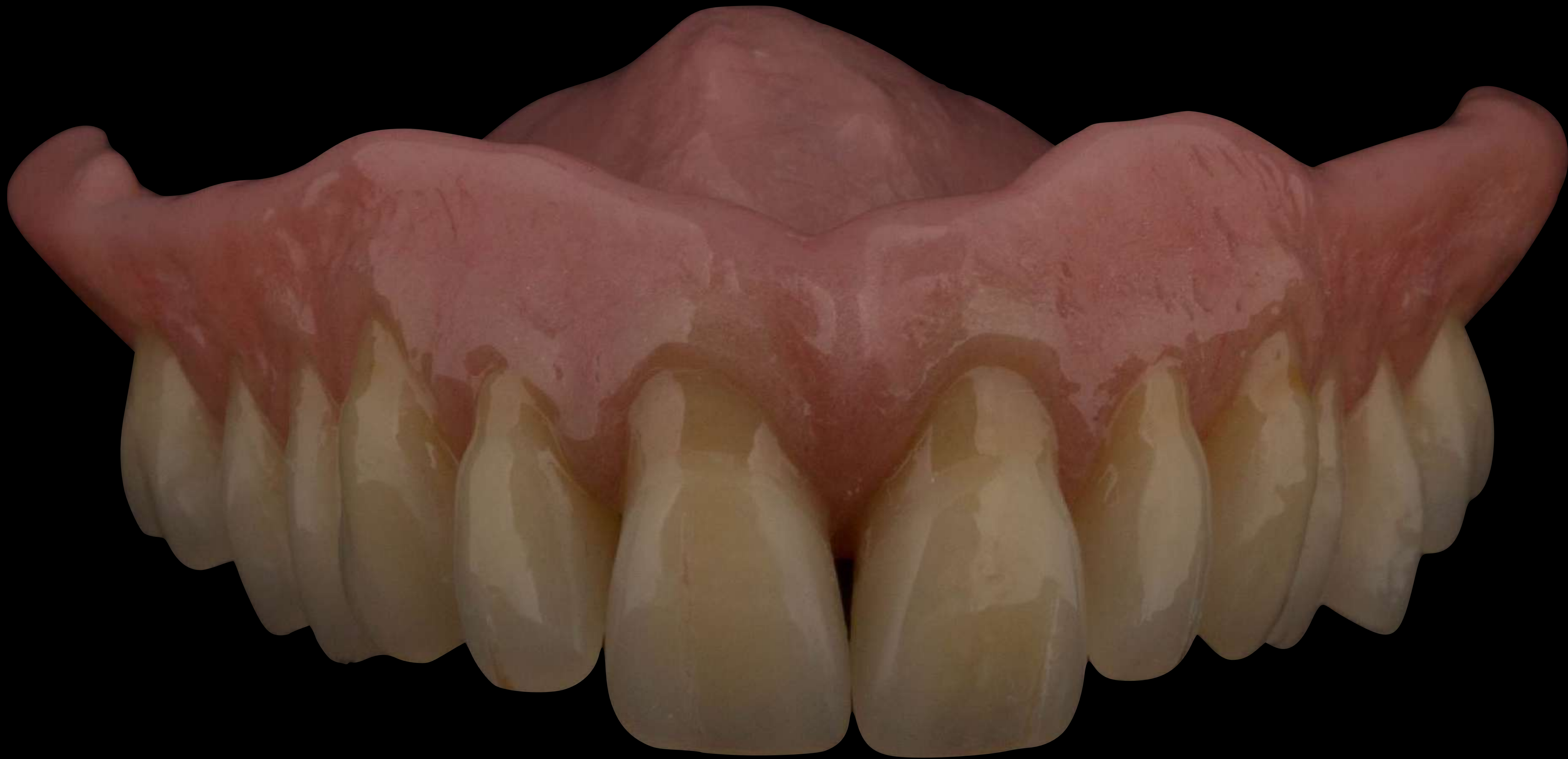1. Lip Support
2. Incisal plane
3. Occlusal plane
4. Buccal corridors
5. Centre line
6. OVD



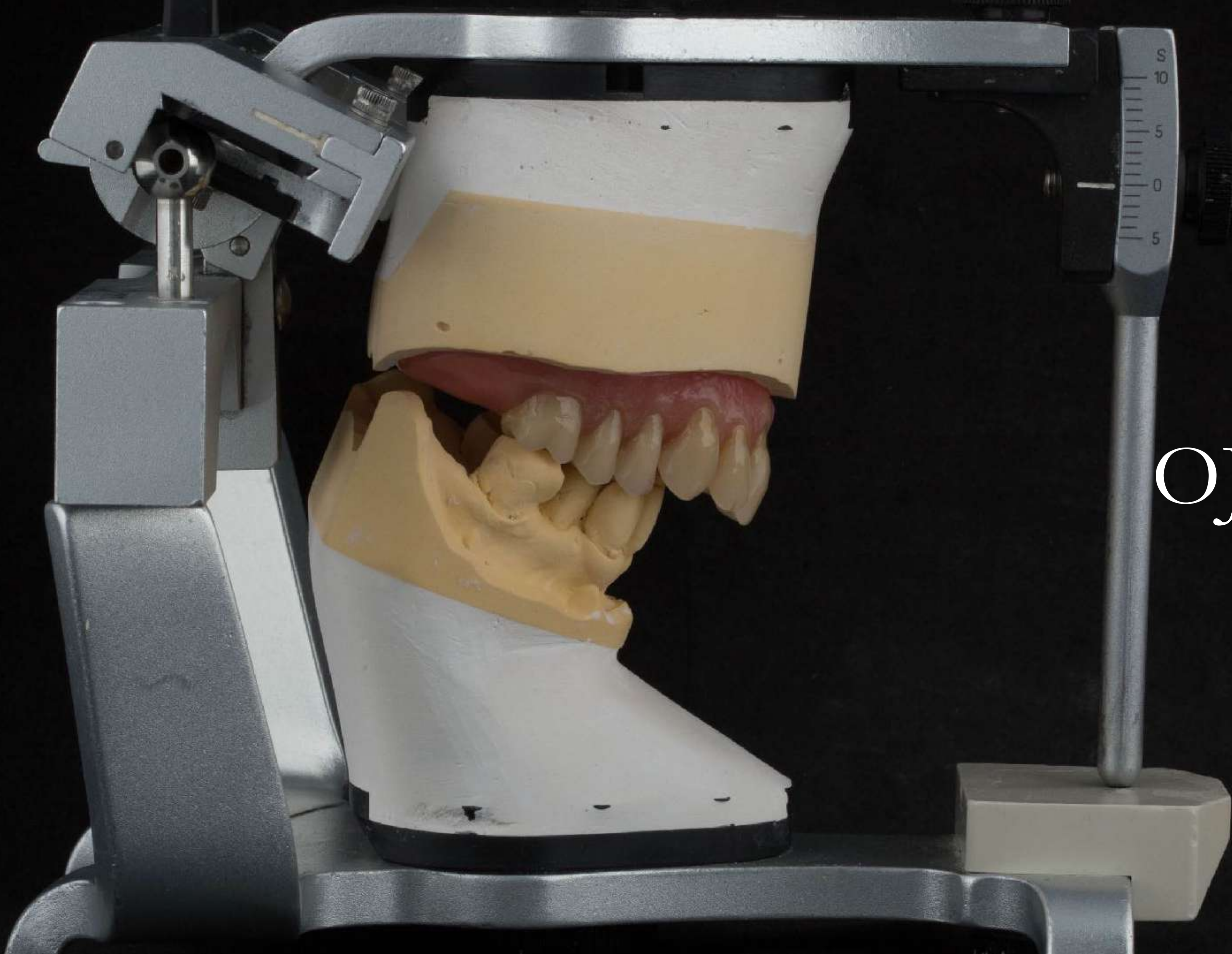The “must have” photos for Dental Technician





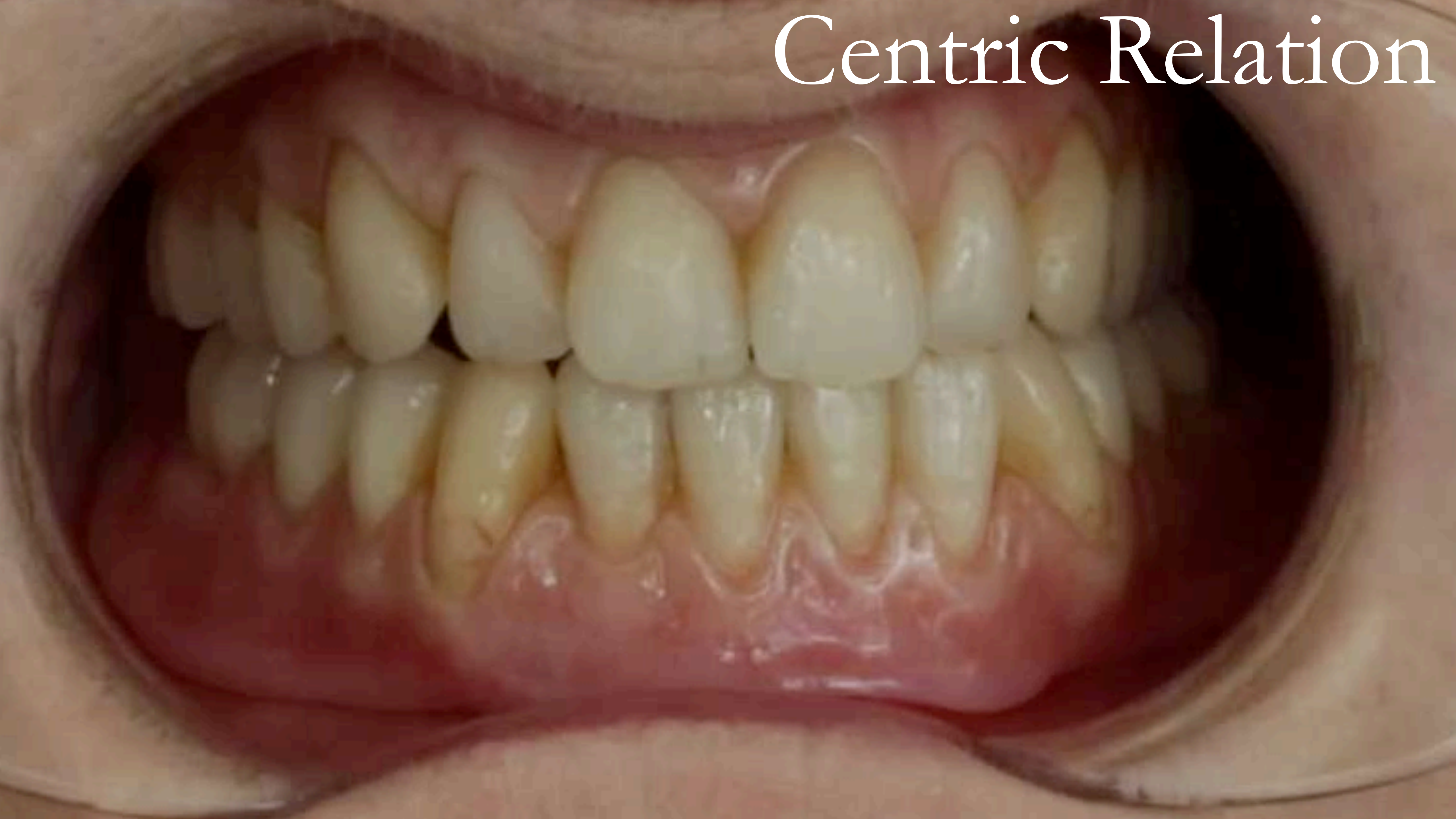

Schottlander Enigmalive teeth



OJ - 12.5 mm

Centric Relation



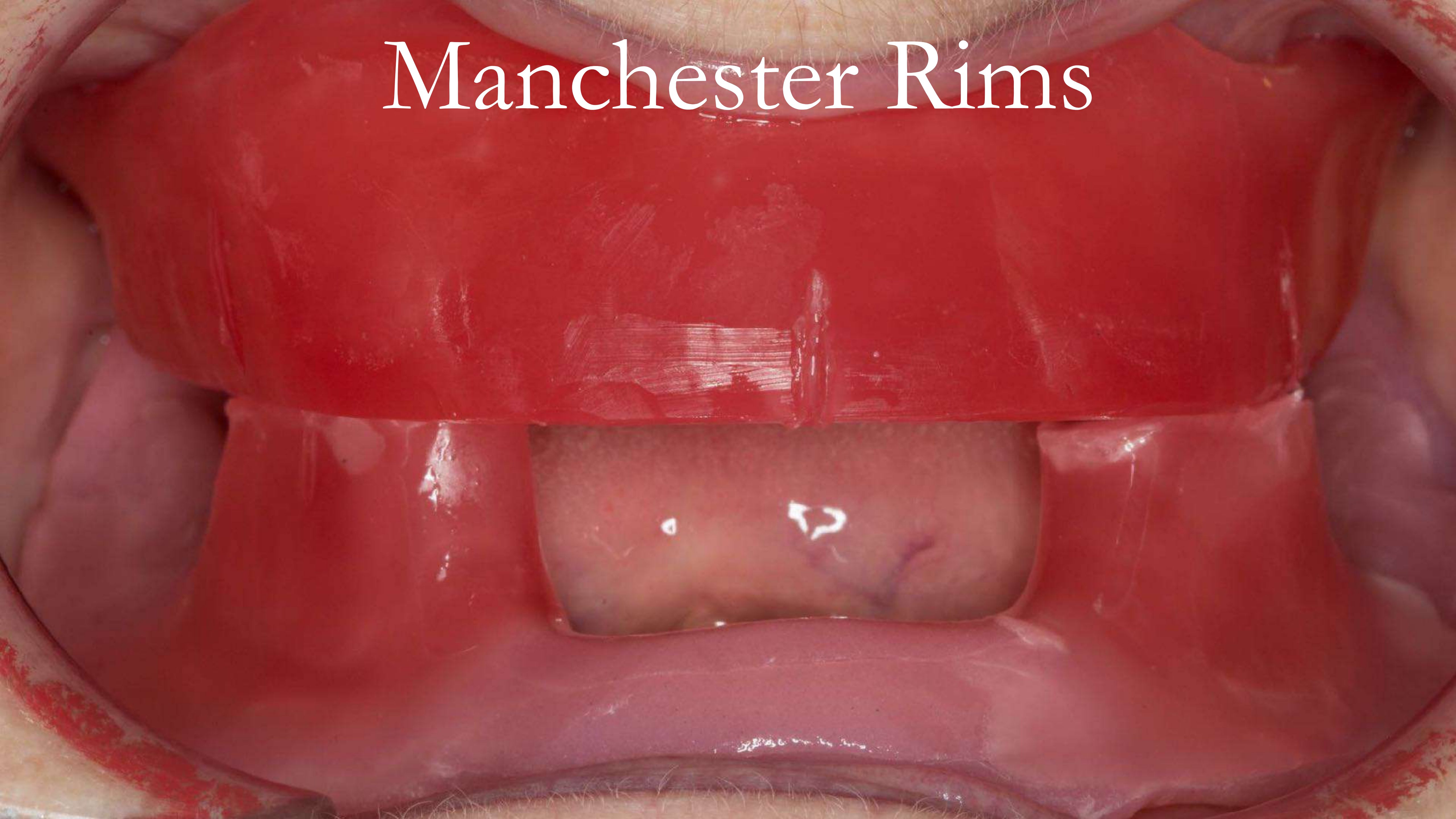A dental model showing a red wax rim on a yellow base. The wax rim is a thick, red, wavy-edged band that follows the contour of the upper and lower dental arches. It is mounted on a yellow, wavy-edged base. The text "Wax Rims" is overlaid in the center of the image in a white, serif font.

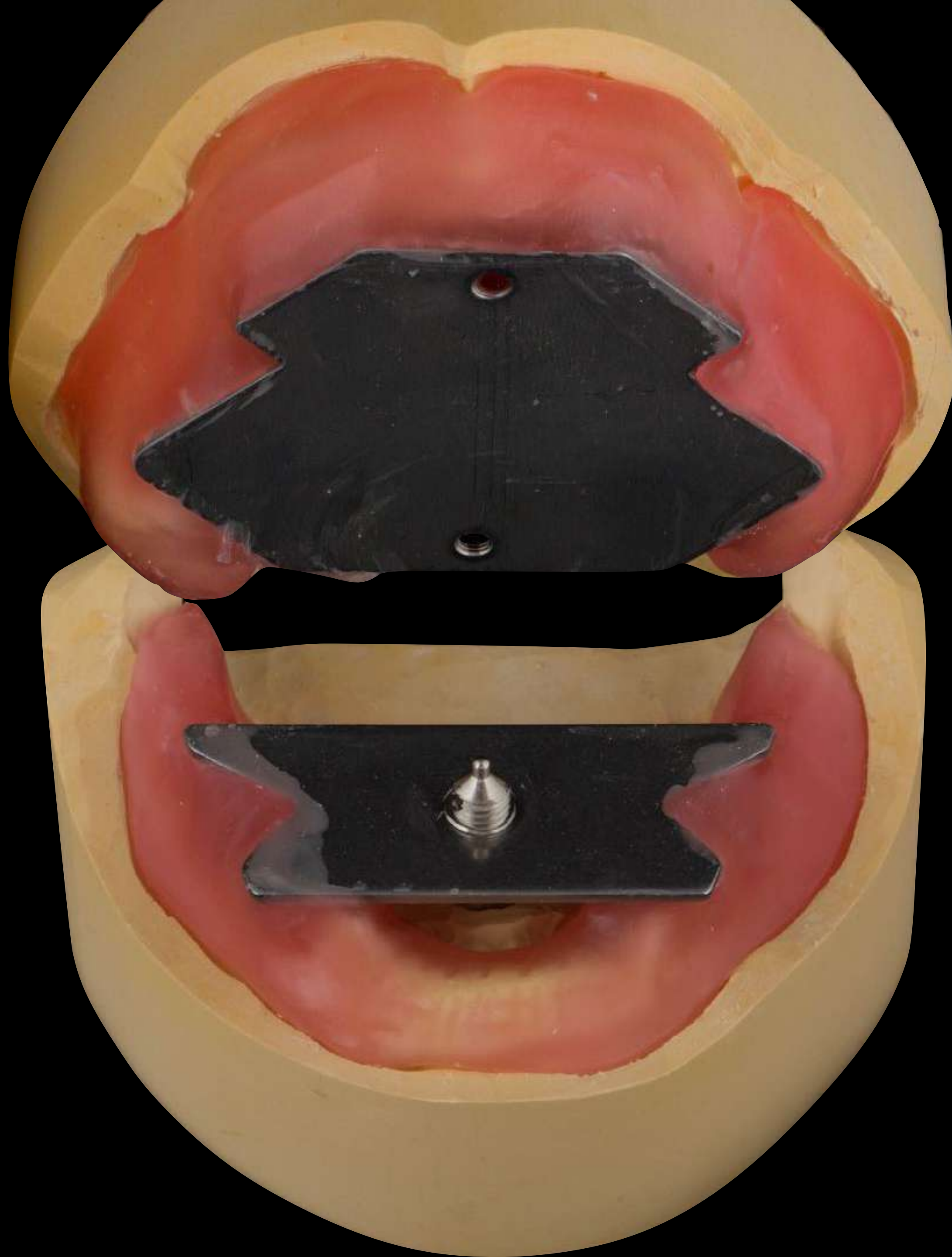
Wax Rims

A photograph of a dental wax rim mounted on a yellow plaster model of a maxilla. The wax is a reddish-pink color and has been shaped to follow the contour of the upper dental arch. A large, thick red 'X' is drawn across the entire image, from corner to corner, indicating that this method is discouraged or incorrect. The text 'Wax Rims' is centered over the wax rim in a white, serif font.

Wax Rims

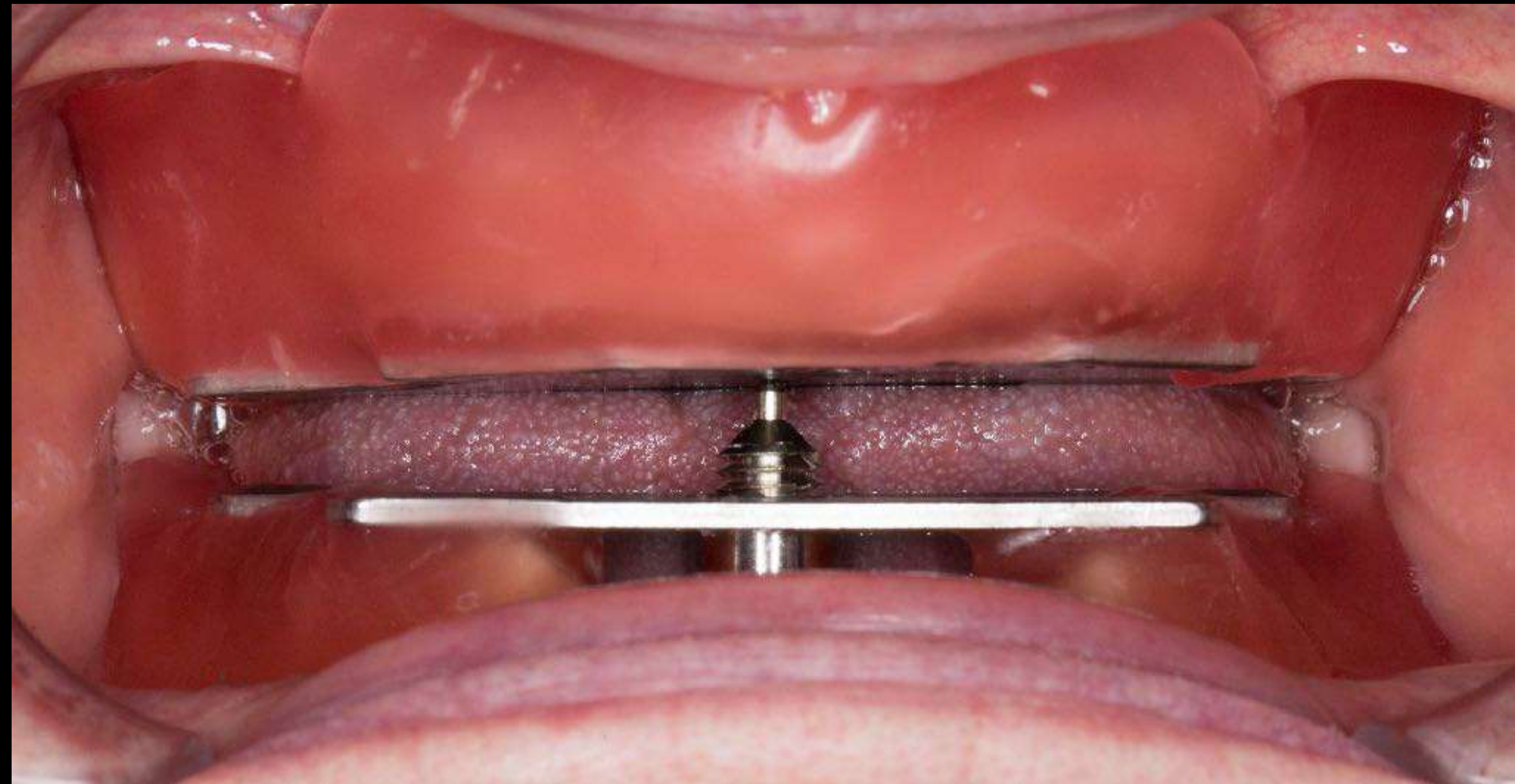
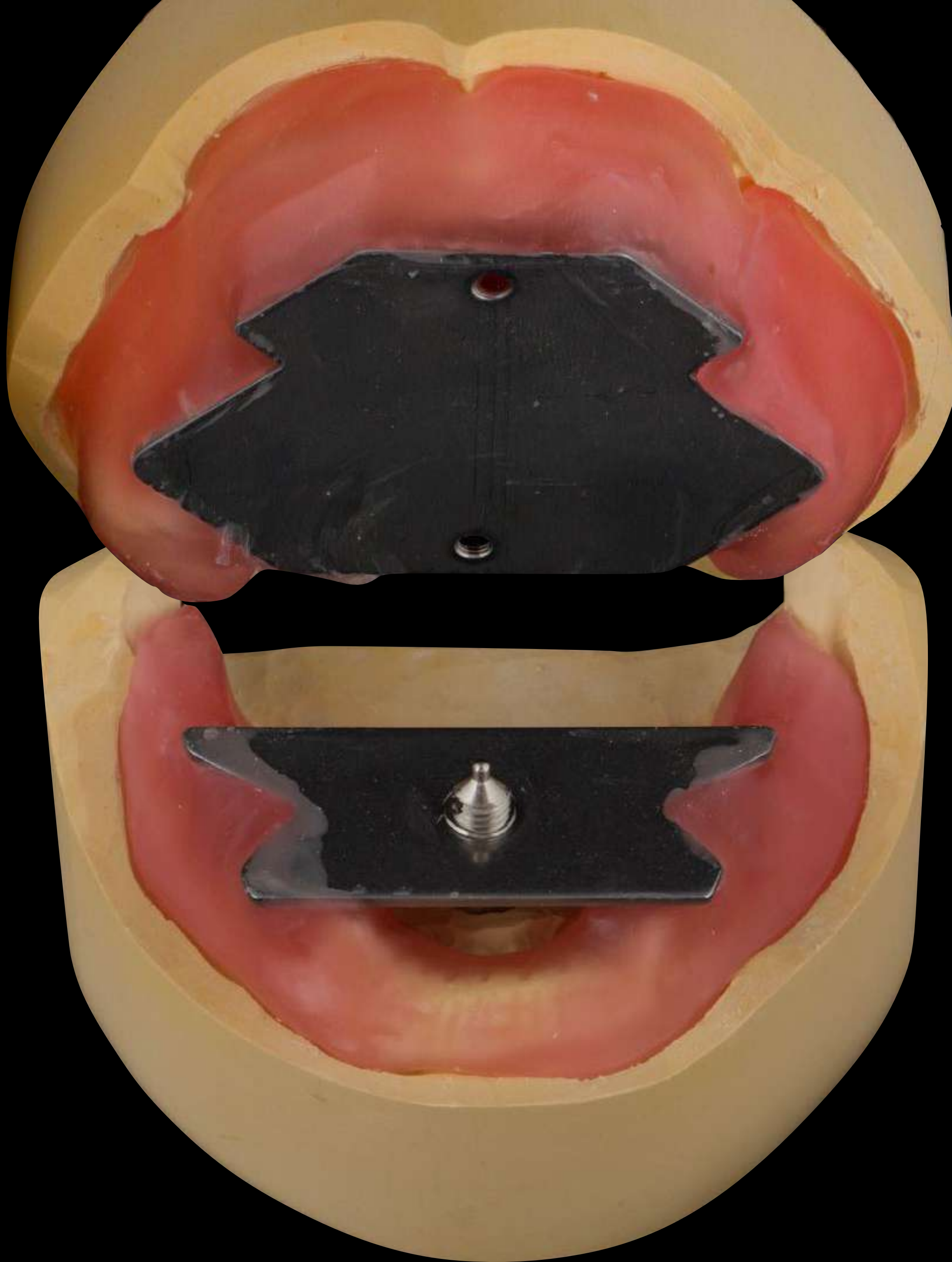
Manchester Rims

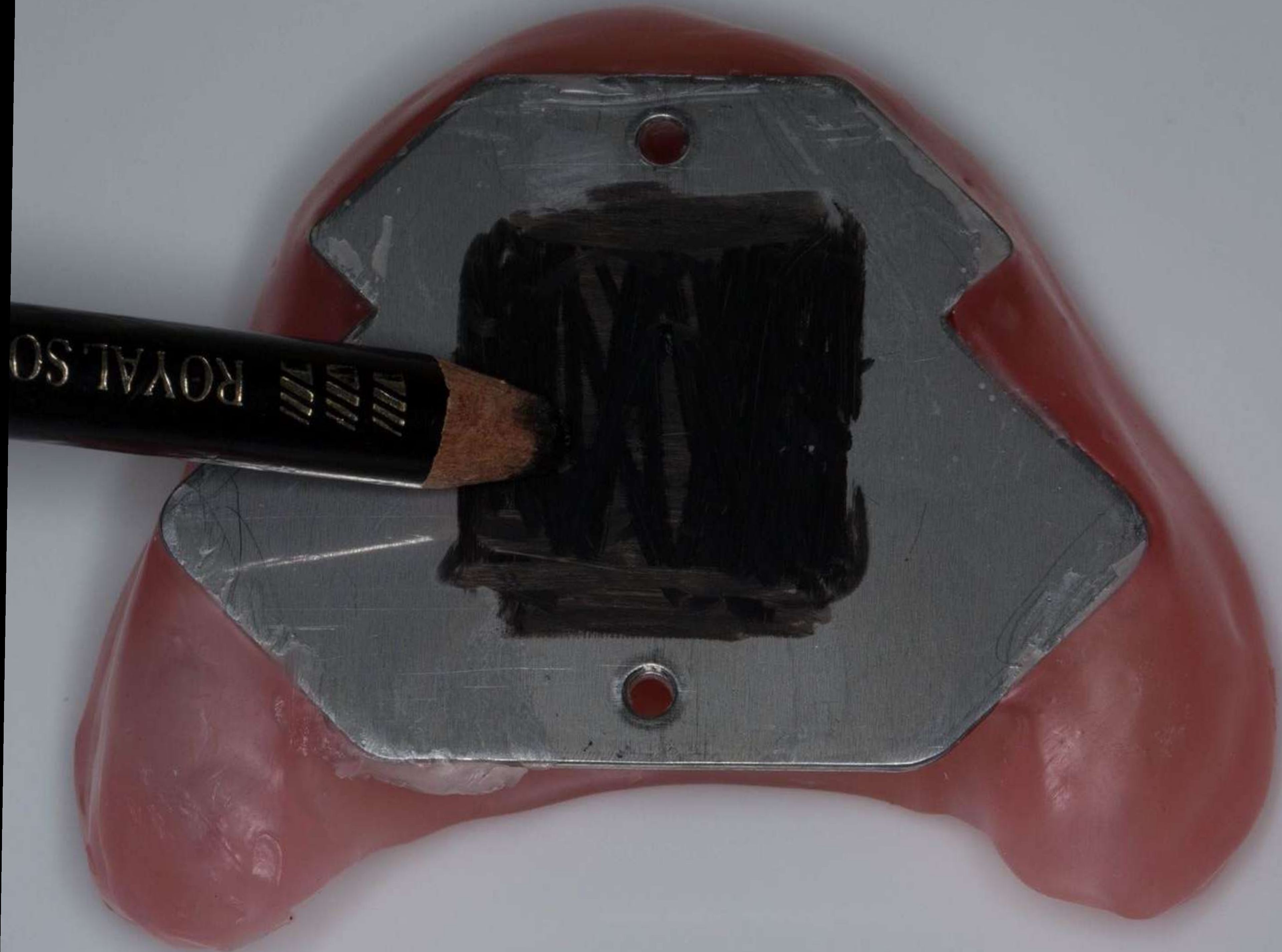


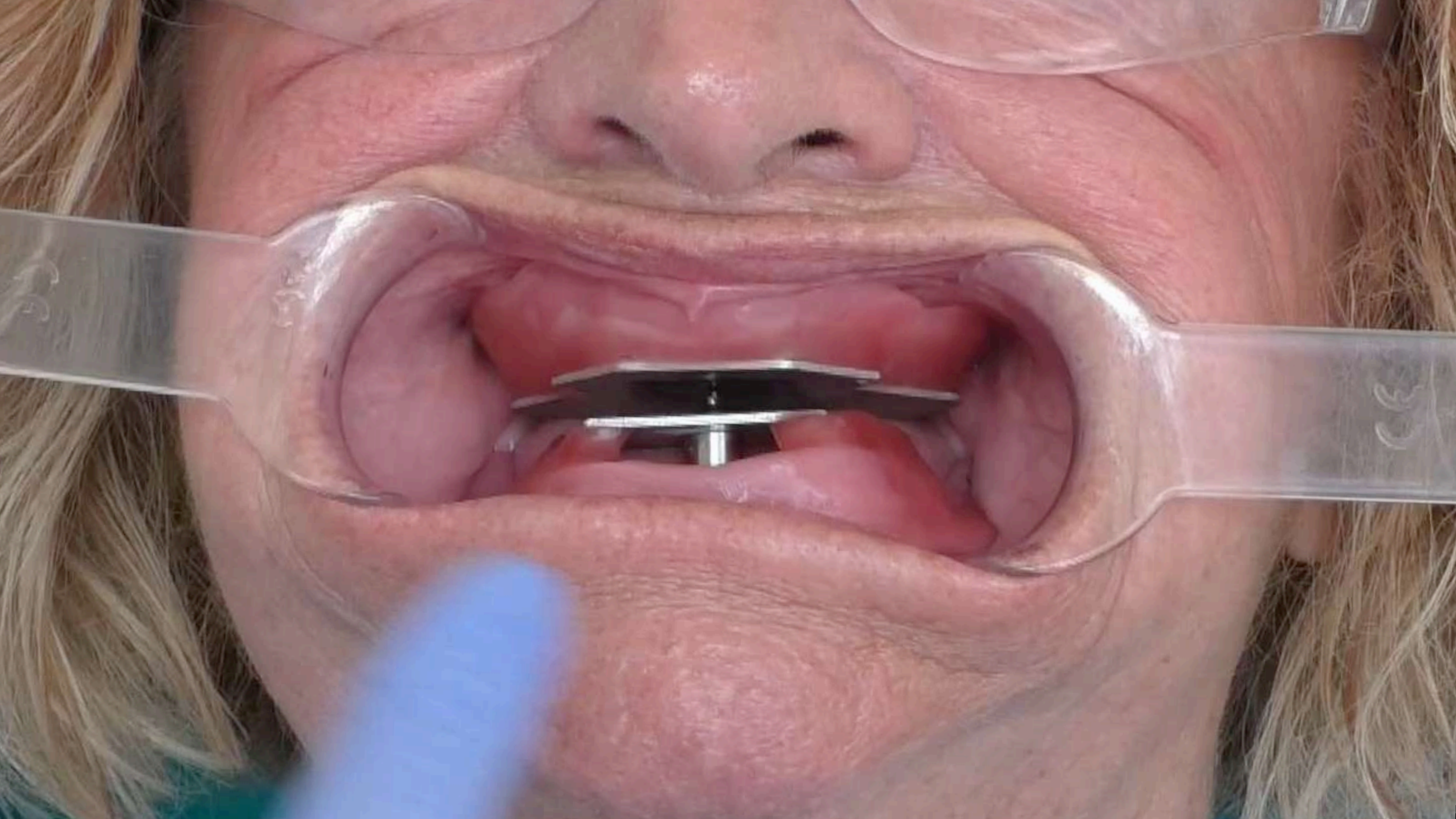


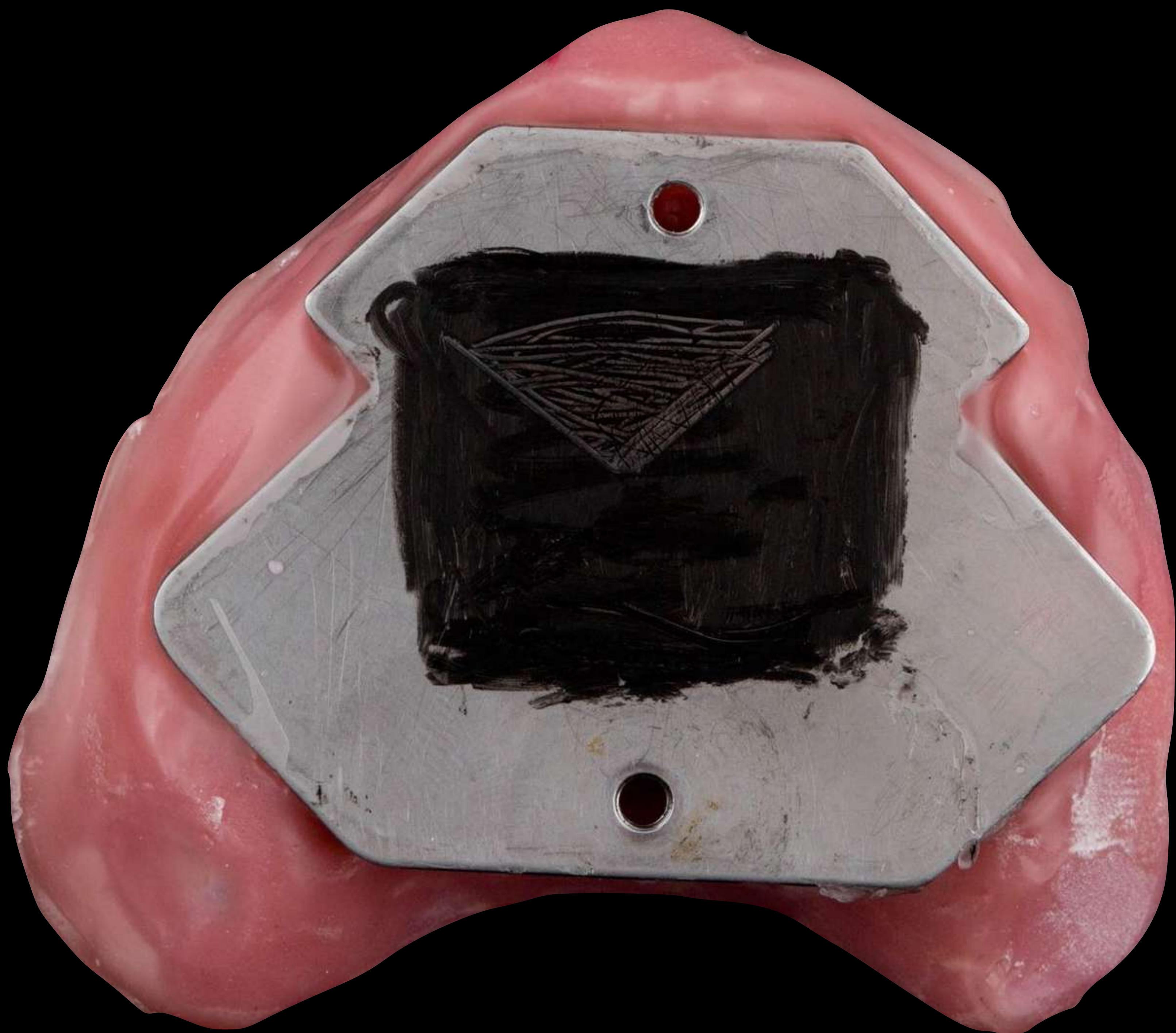
Gothic arch tracing
Central bearing point

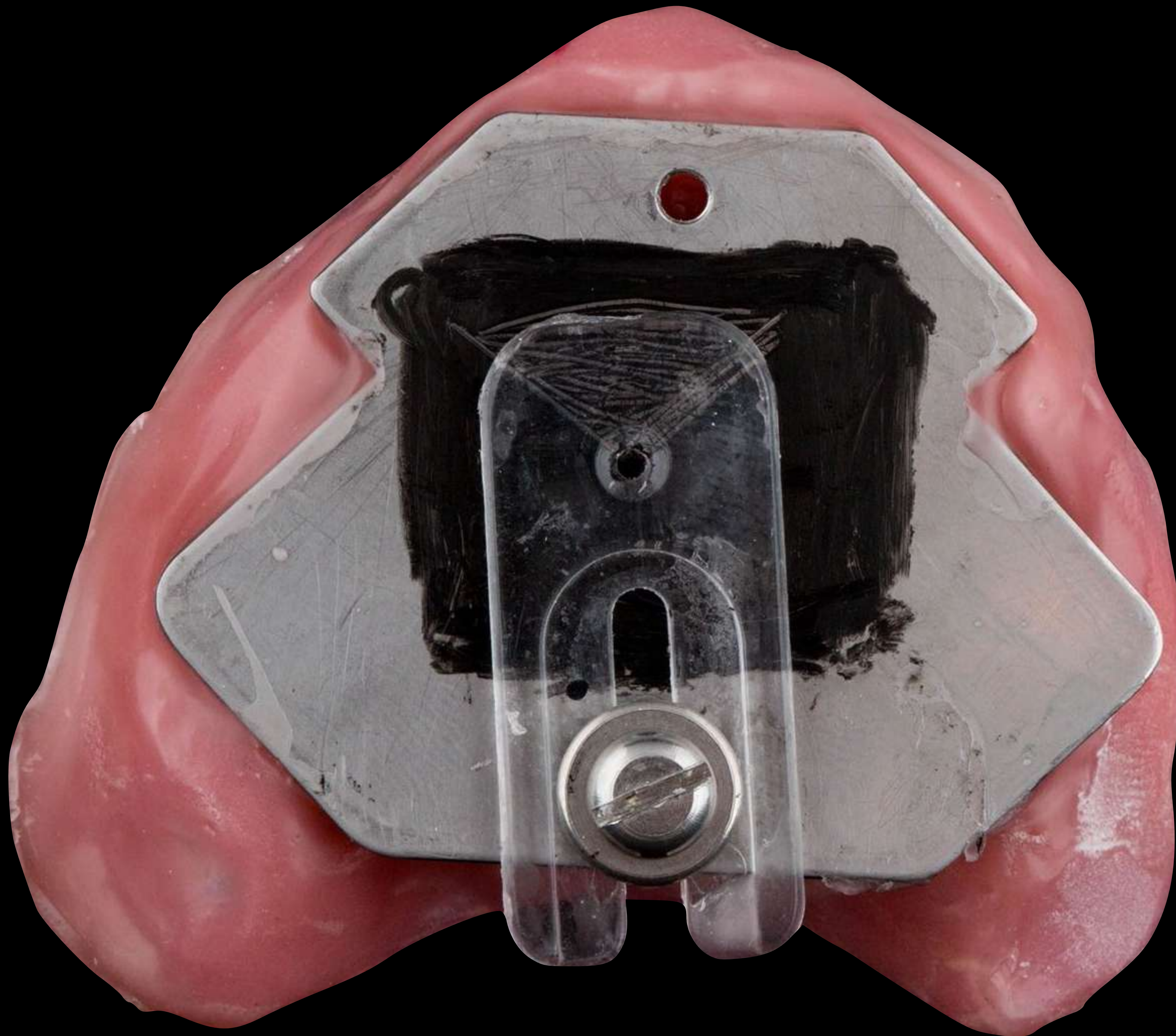Gerber Condylator

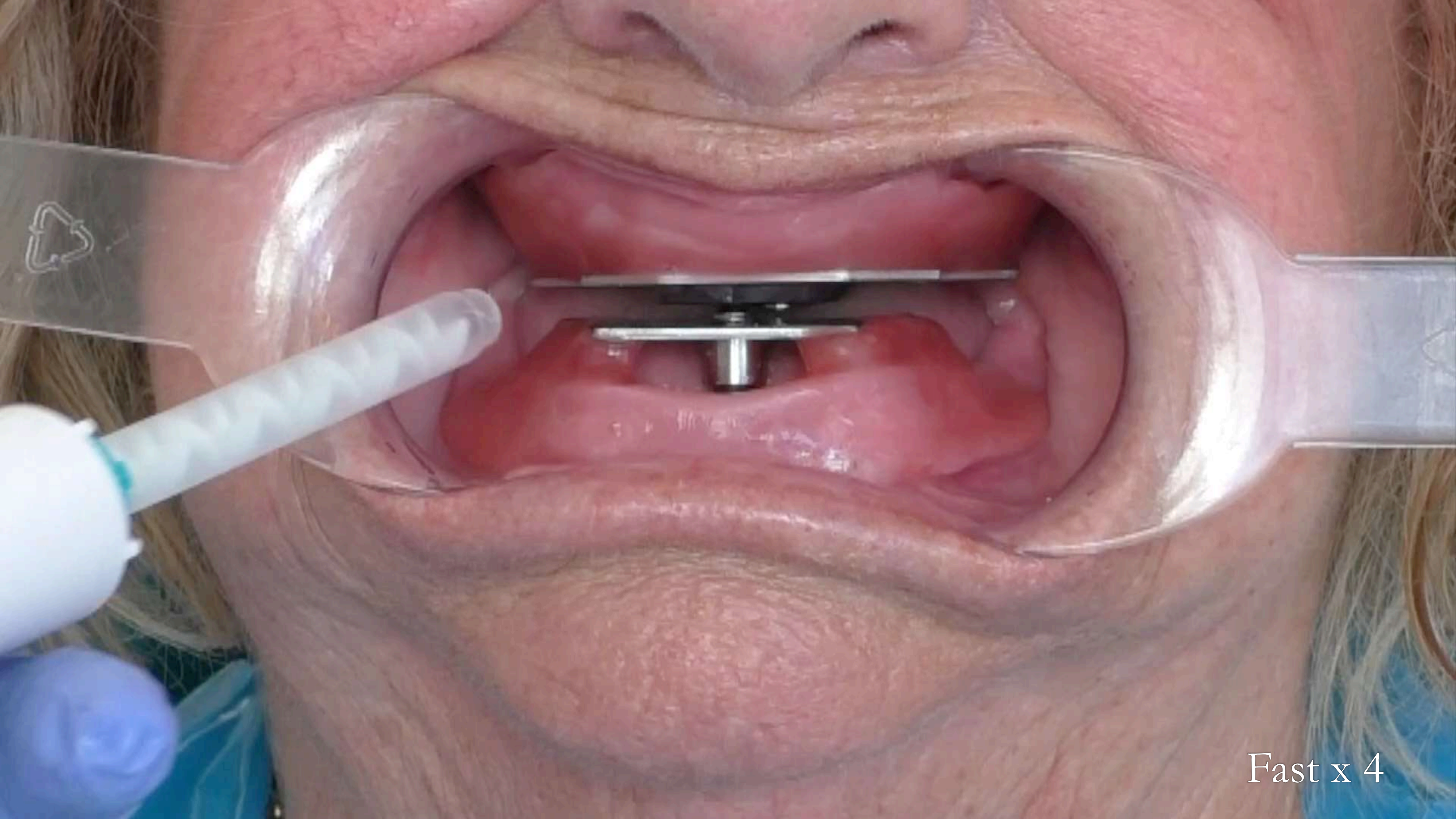



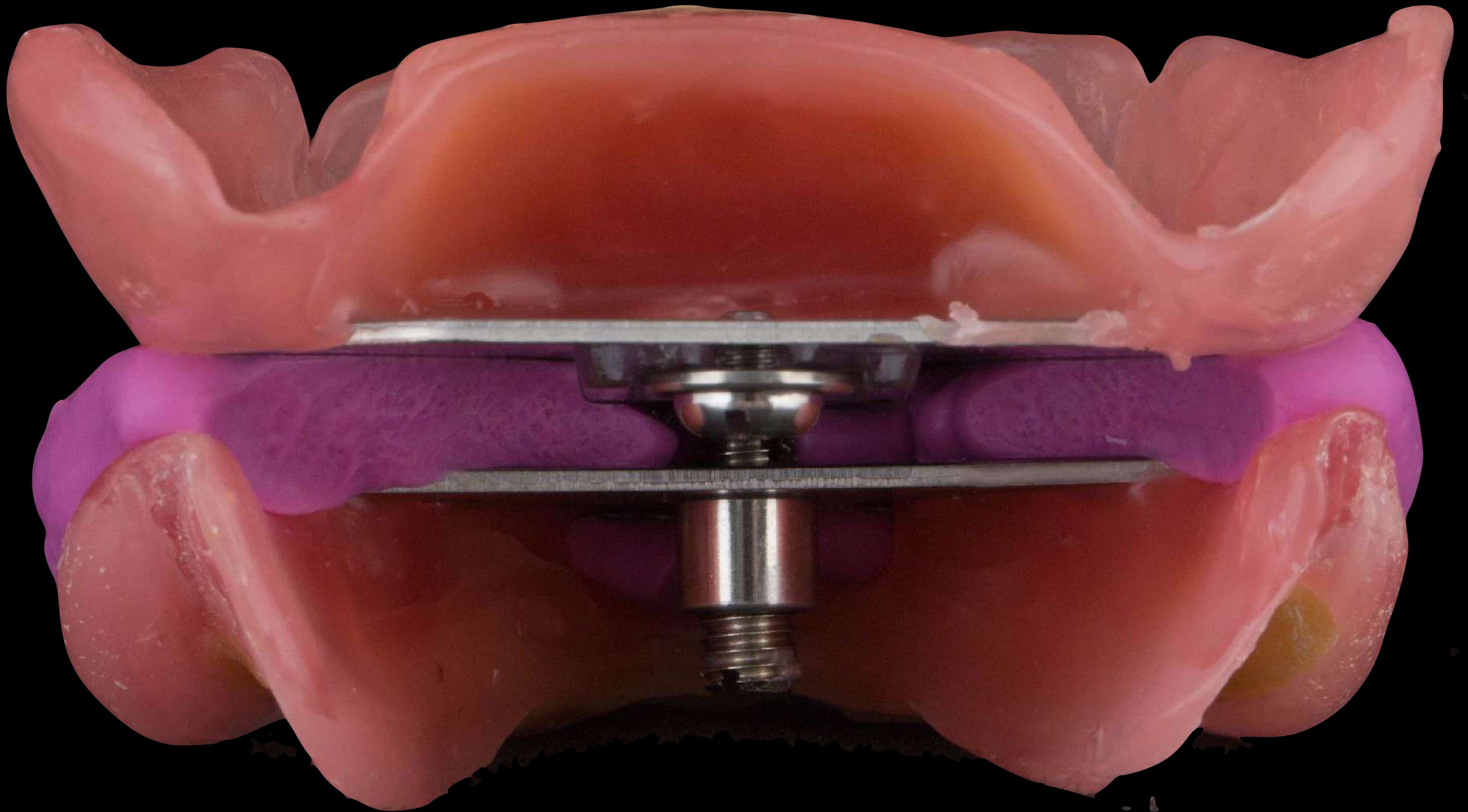



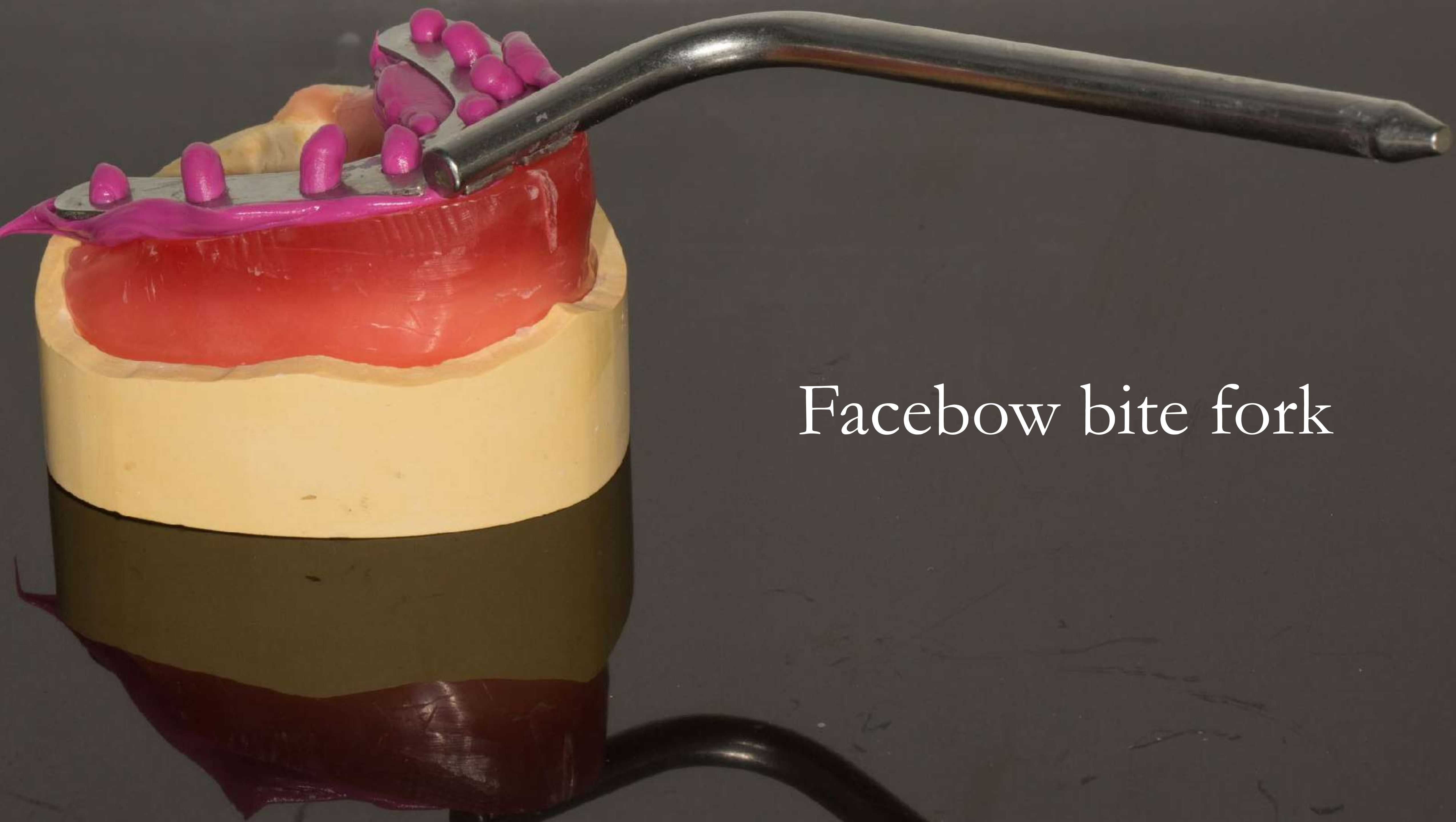




Fast x 4





Facebow bite fork

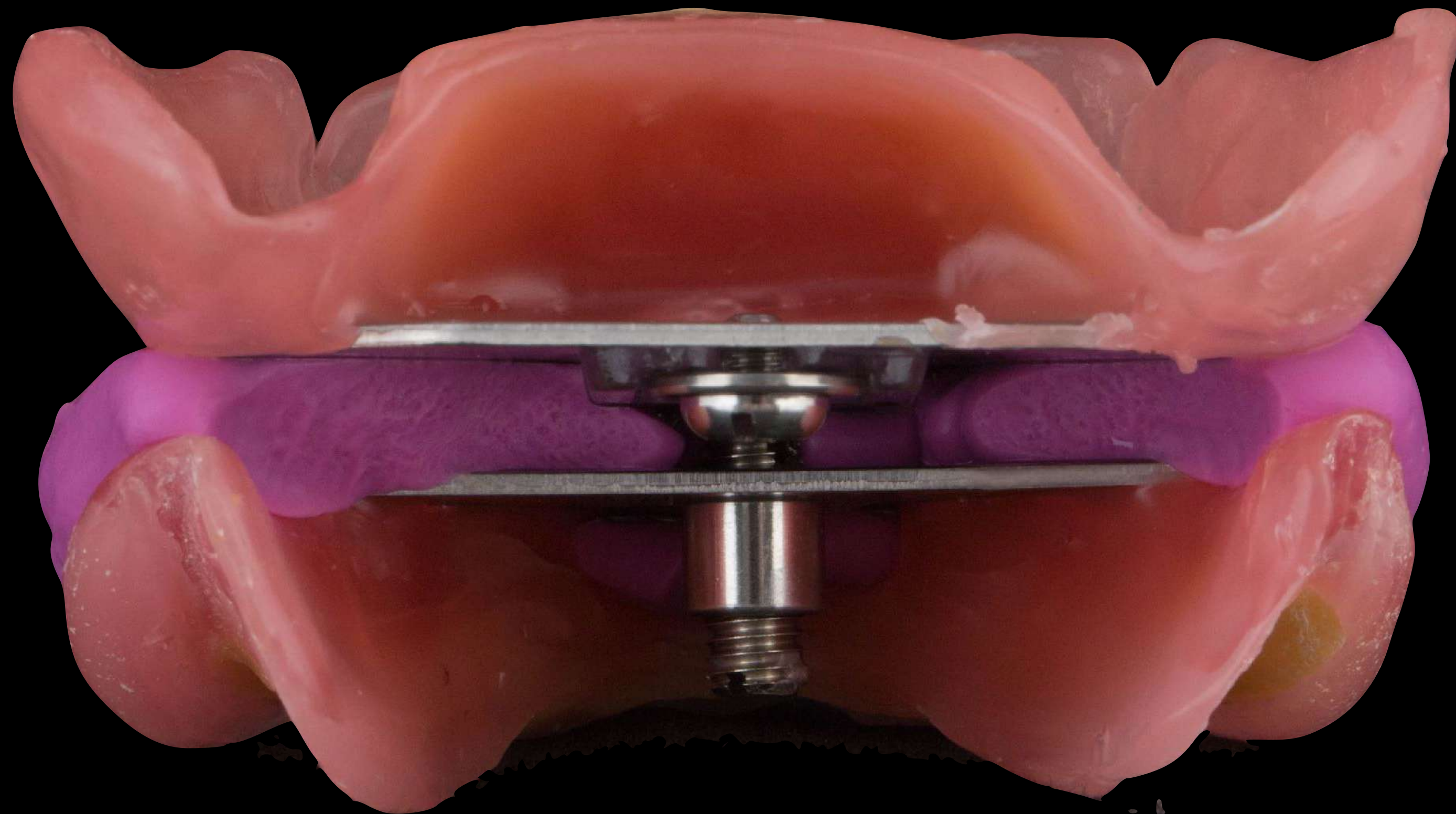
Facebow



Facebow

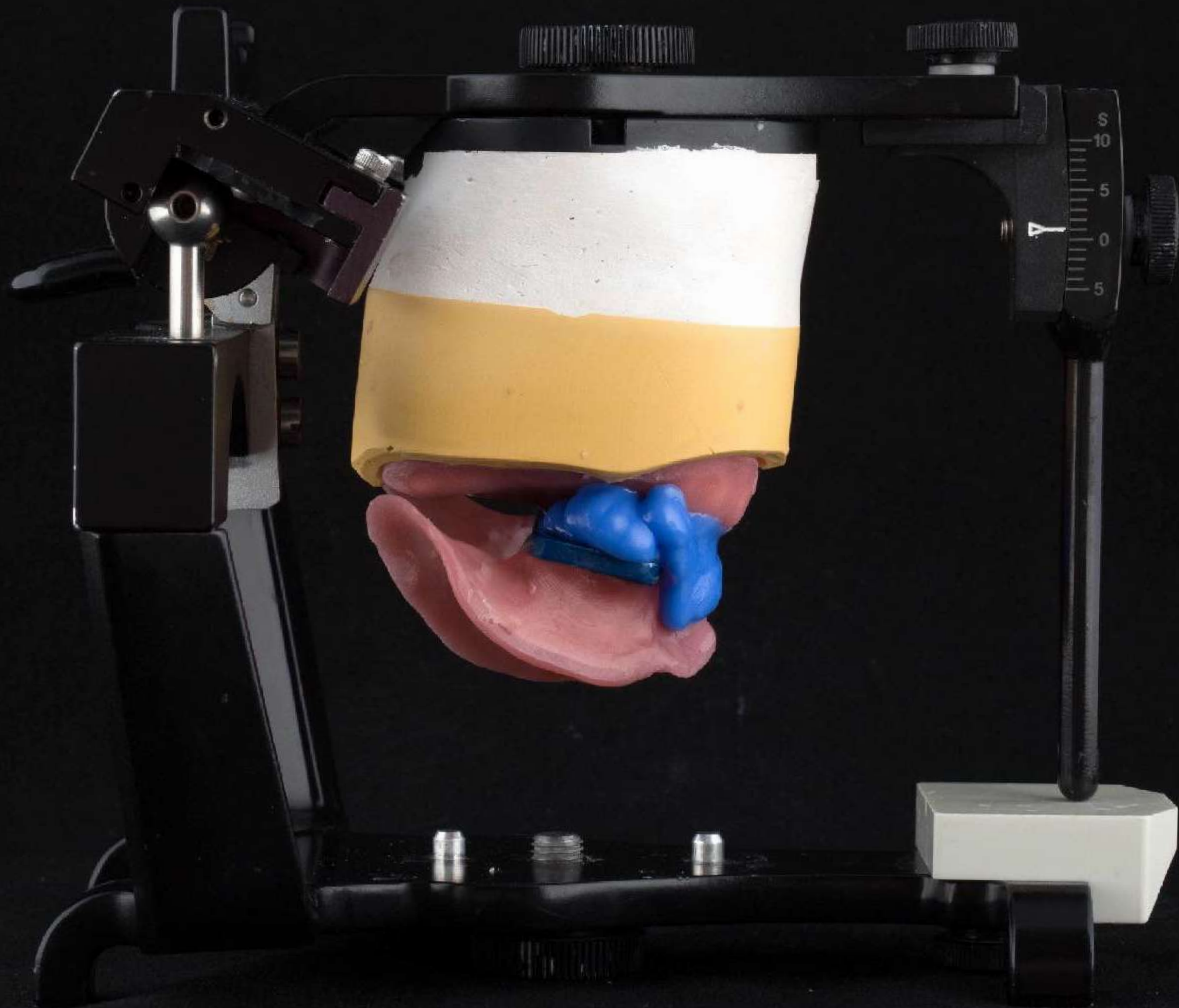


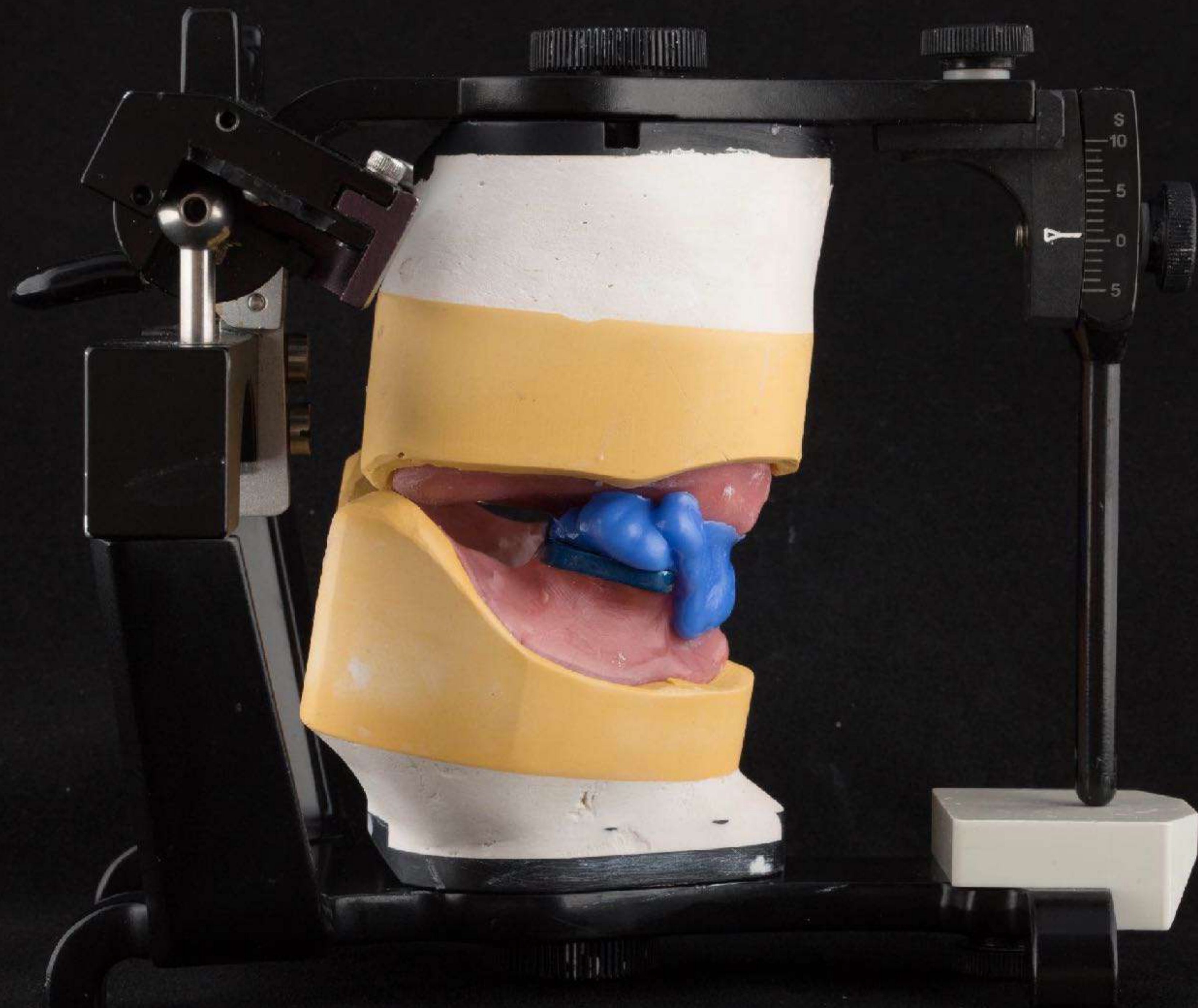
+ CR record

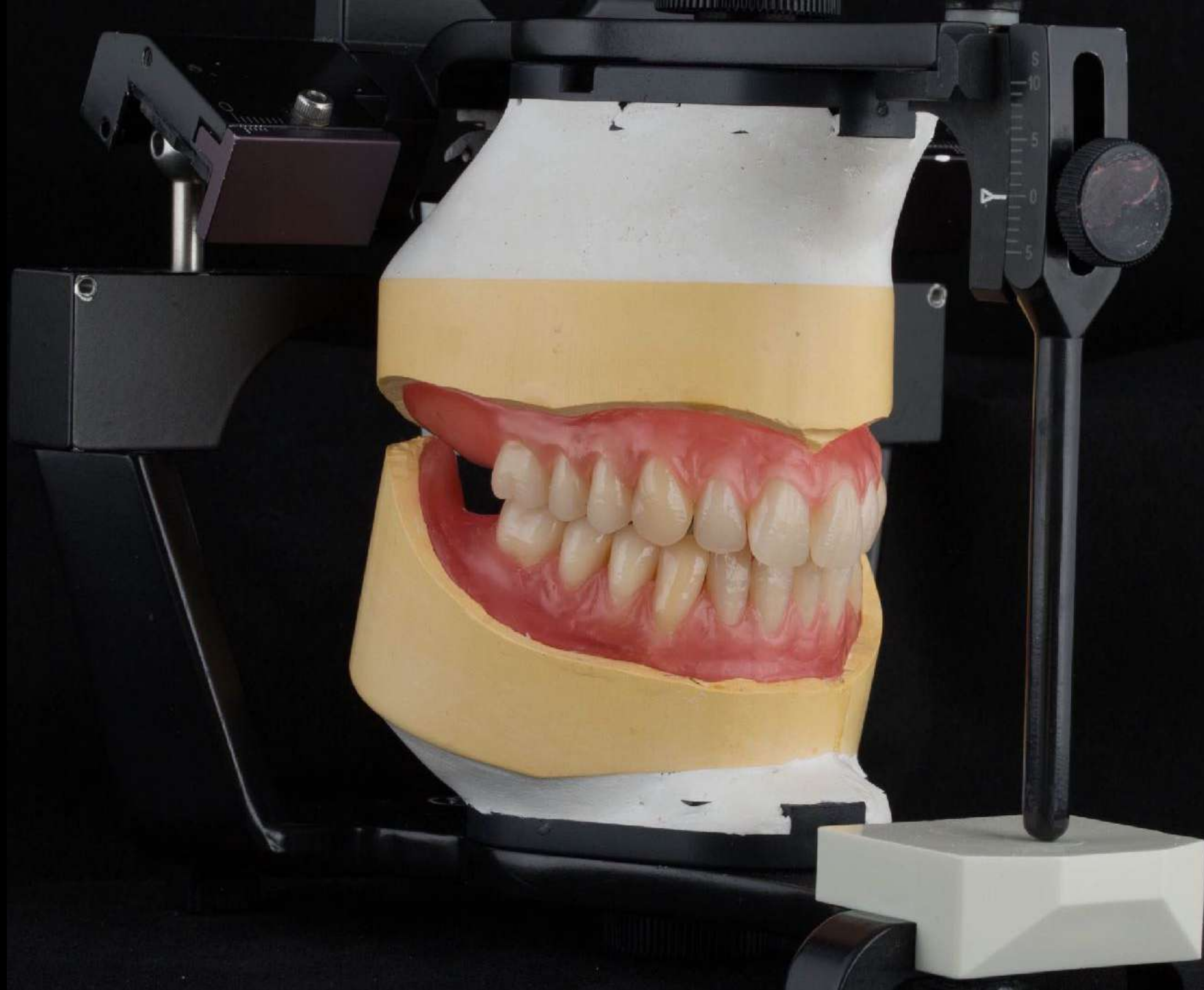






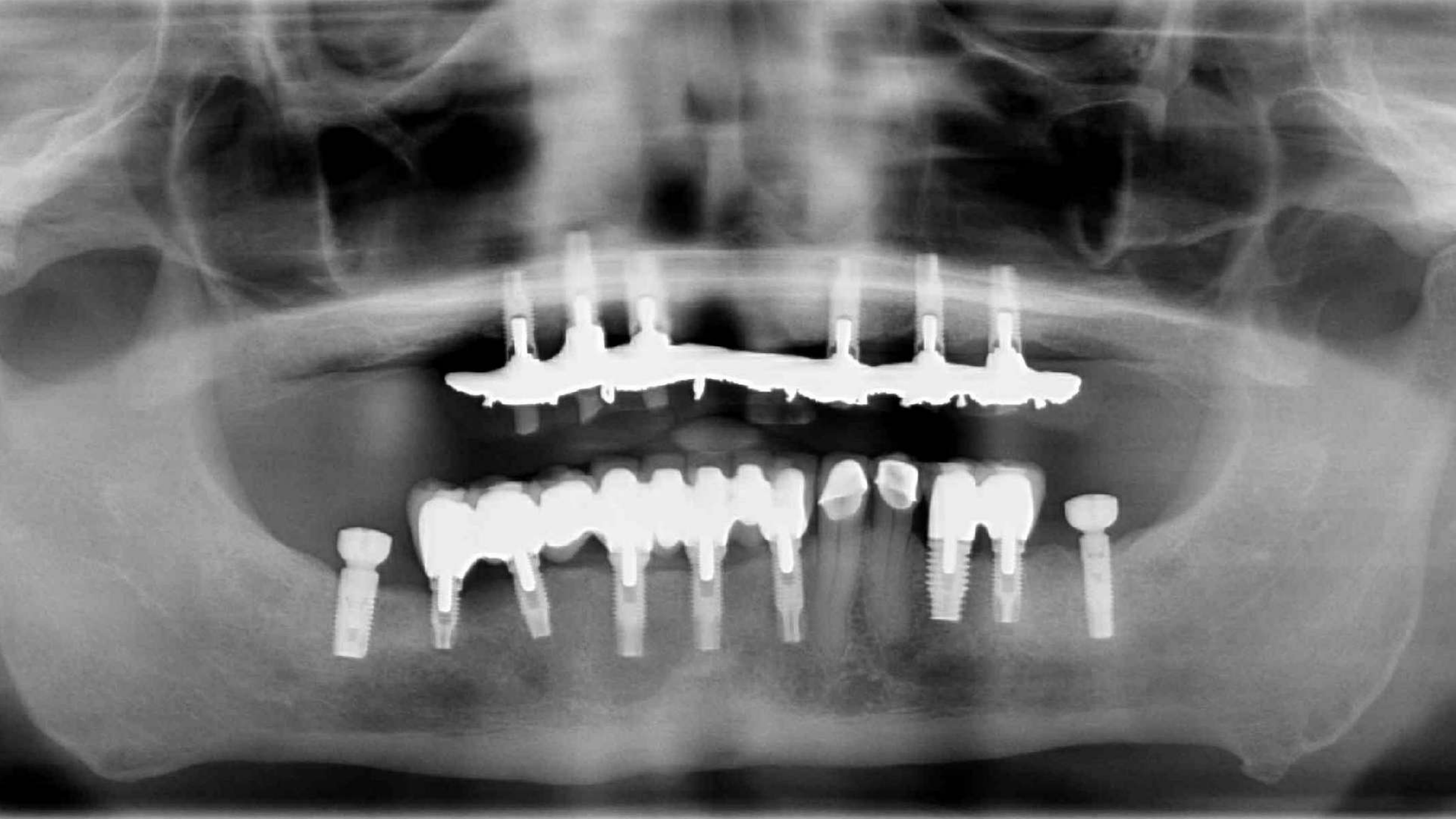


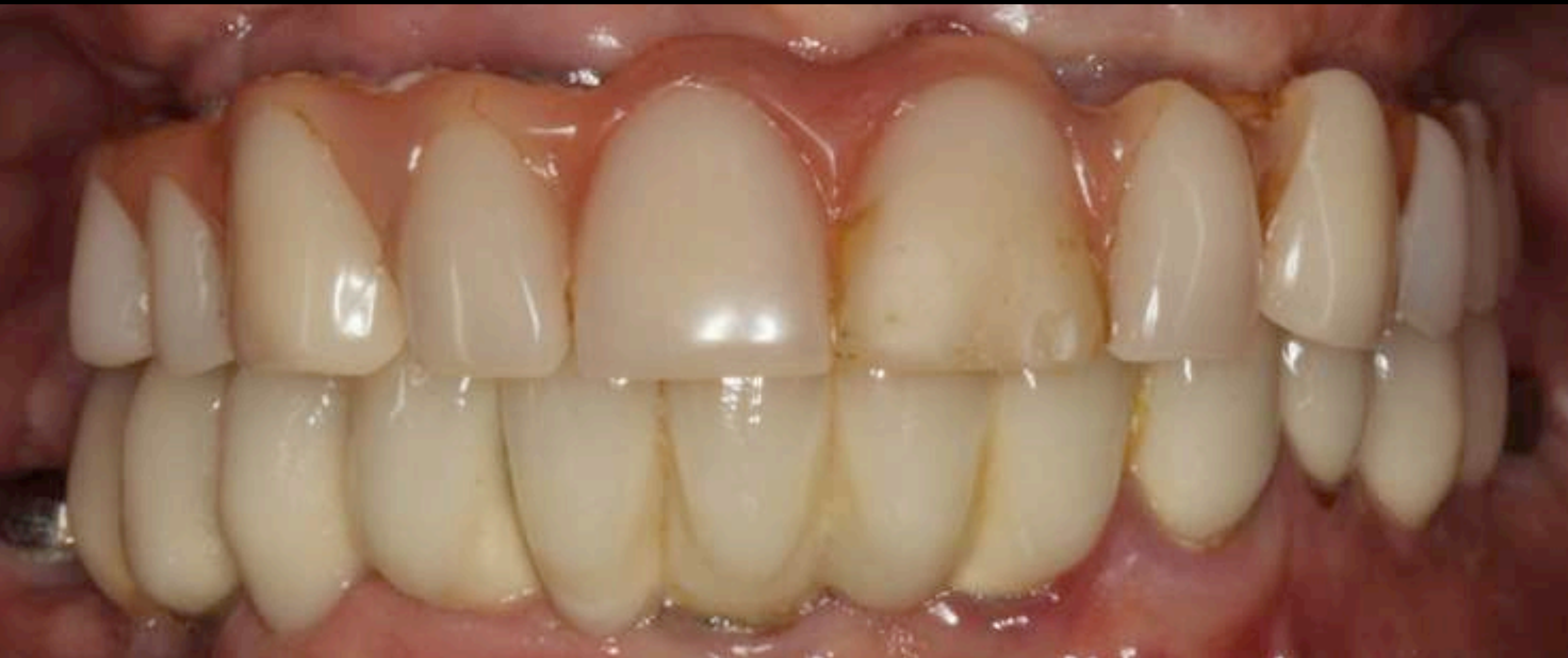

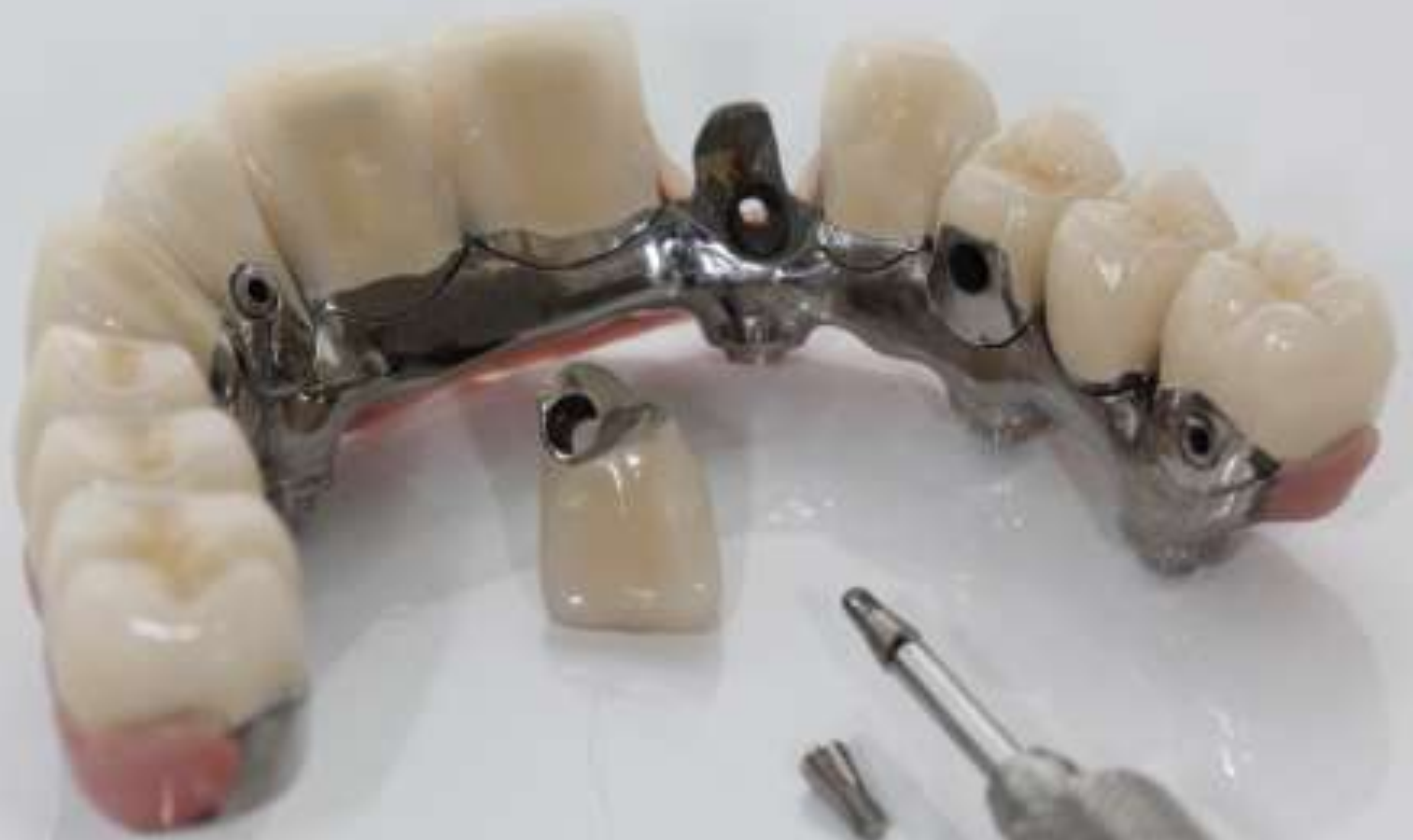Why dentures?

I love doing them





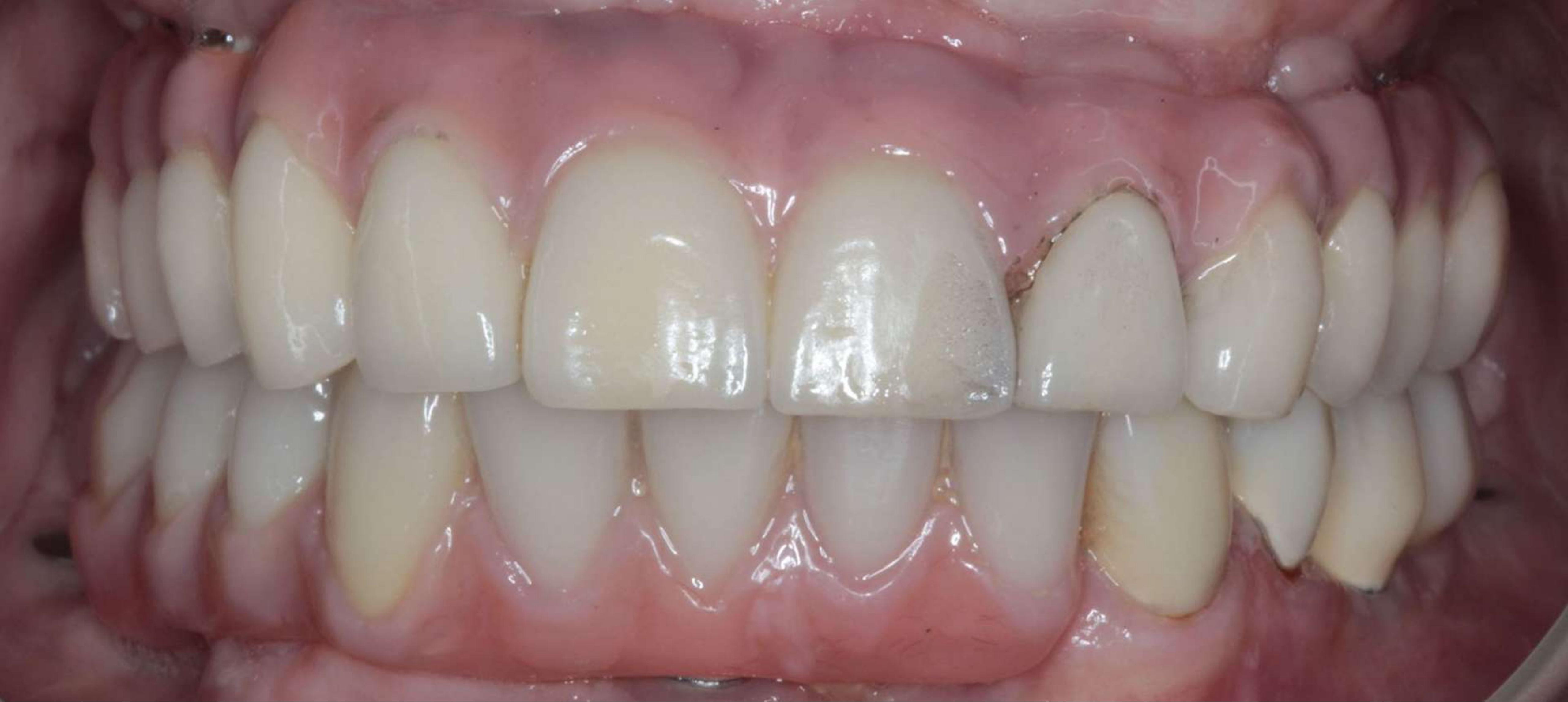On arrival



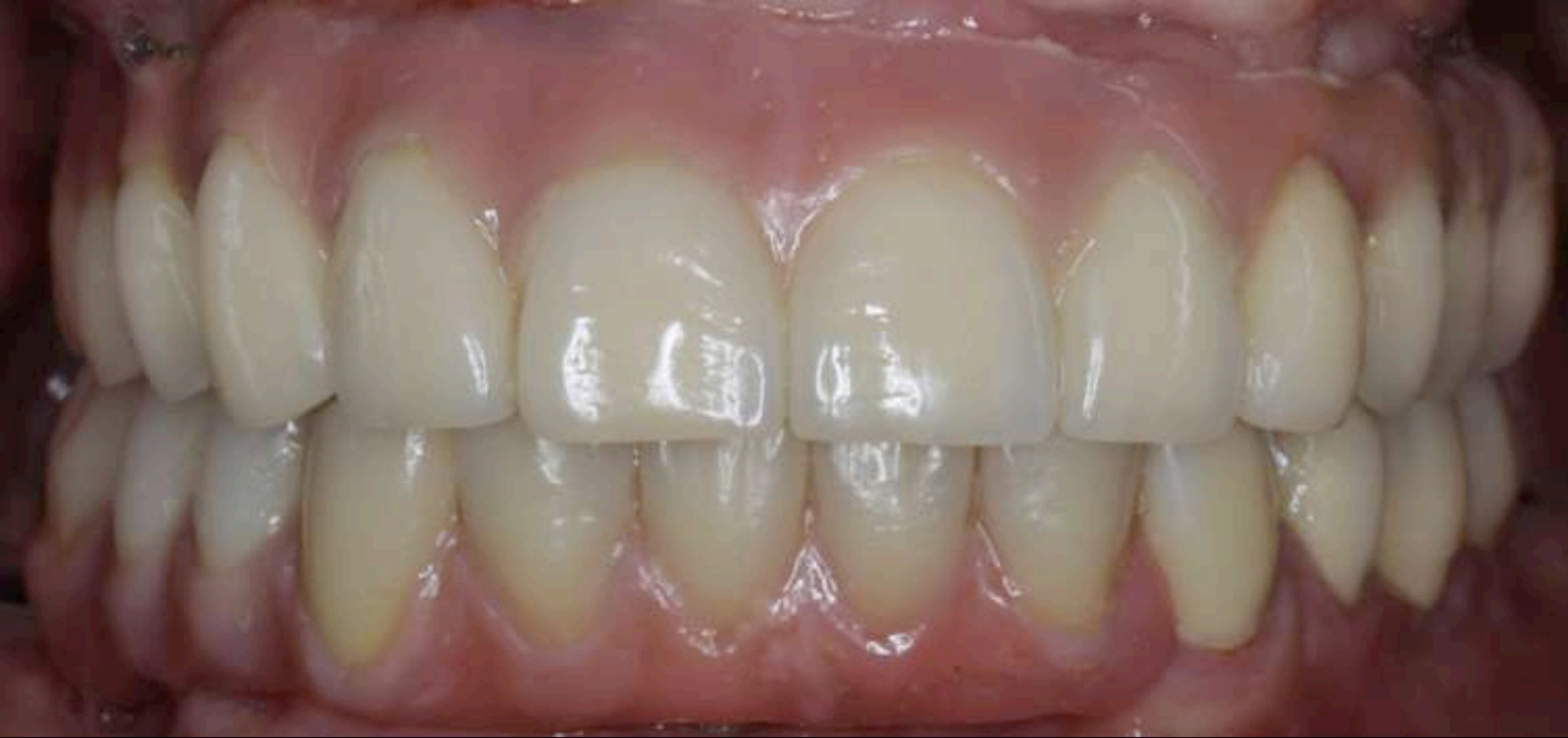Peter Whorlie bridge

A dental arch model, likely a maxillary (upper) arch, is shown. It features a metal framework with several circular openings, possibly for a removable partial denture. The teeth are made of a light-colored material, possibly porcelain or acrylic. A purple rectangular box is superimposed over the center of the arch, containing the text "Fin, you idiot!". In the lower right corner, there is a small metal tool, possibly a dental bur or a similar instrument, and a small metal pin or screw.

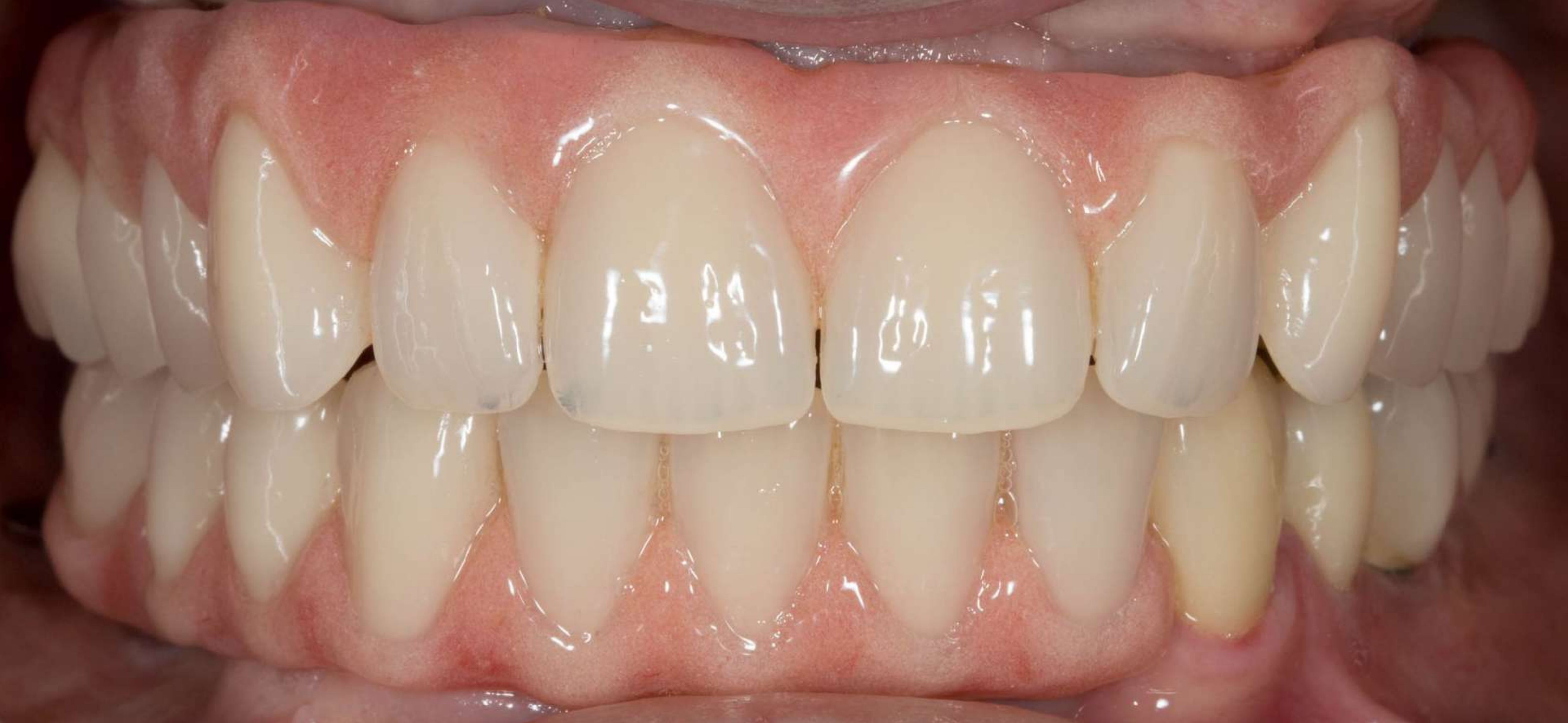Fin, you idiot!



1st attempt



2nd attempt



3rd attempt

Schottlander Enigmalive teeth

John Riach

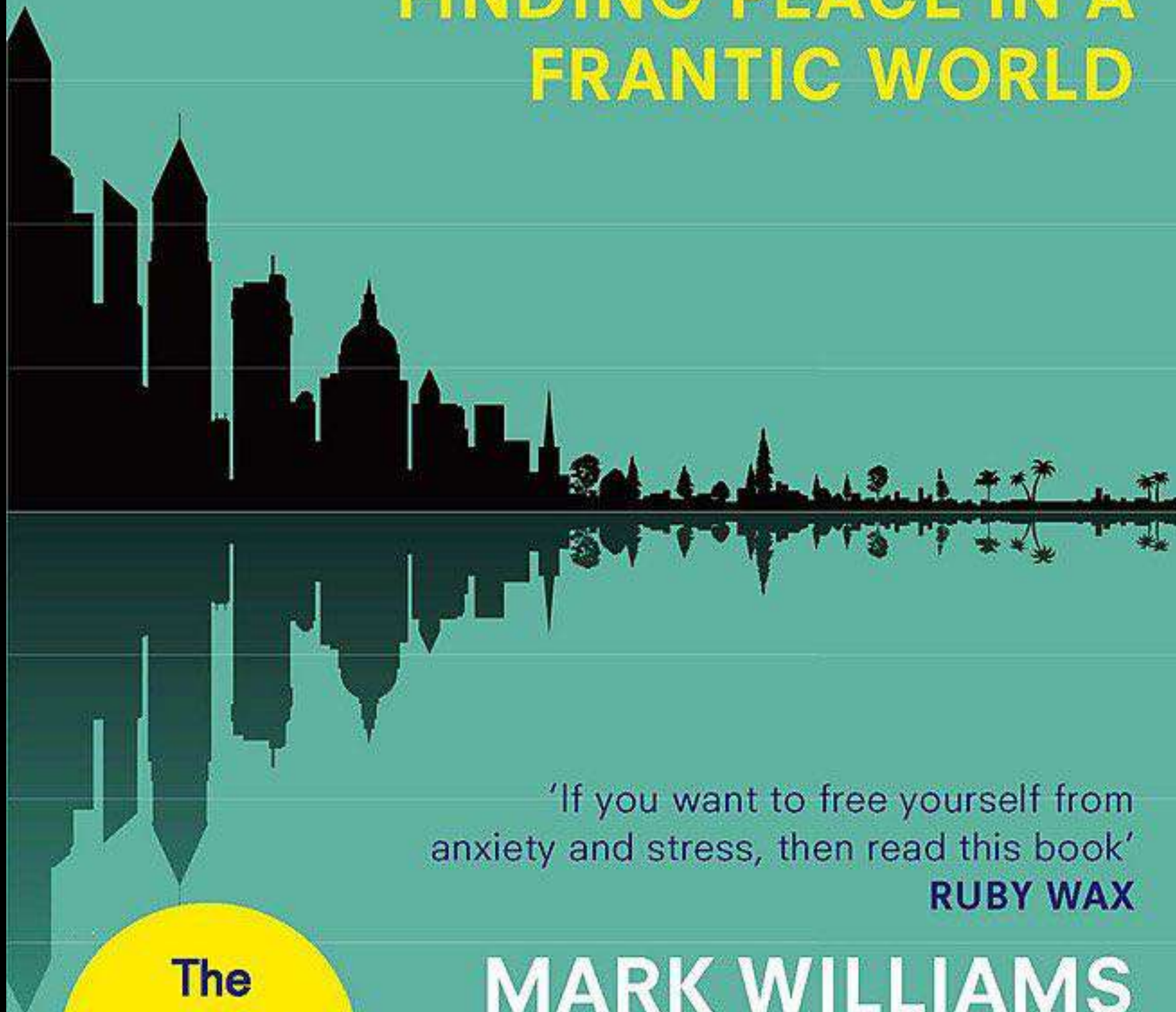
My Clinical Psychologist



INCLUDES FREE CD OF GUIDED MEDITATIONS

Mindfulness

a practical guide to
**FINDING PEACE IN A
FRANTIC WORLD**



'If you want to free yourself from
anxiety and stress, then read this book'

RUBY WAX

The
life-changing
bestseller

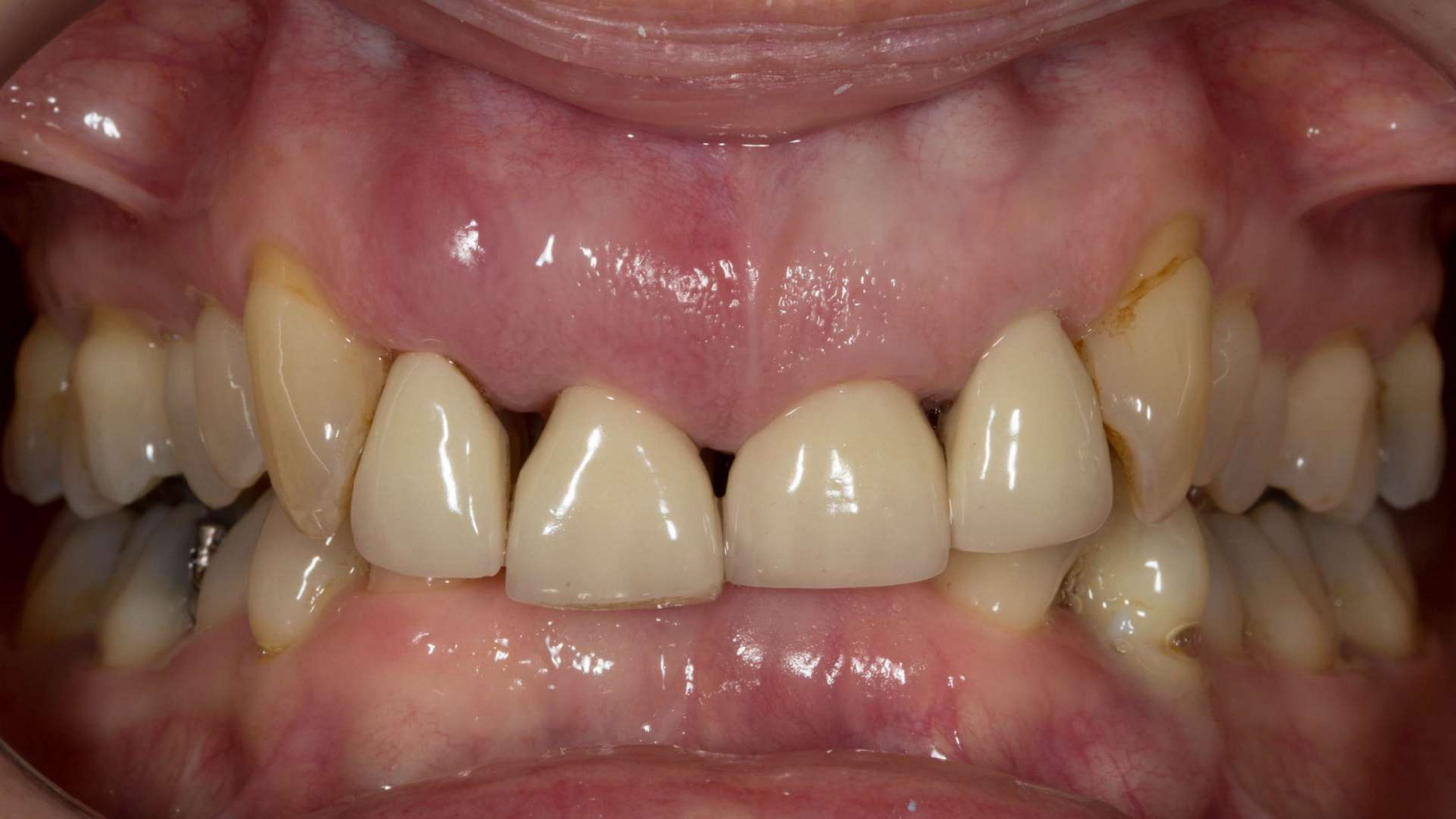and **MARK WILLIAMS**
DANNY PENMAN

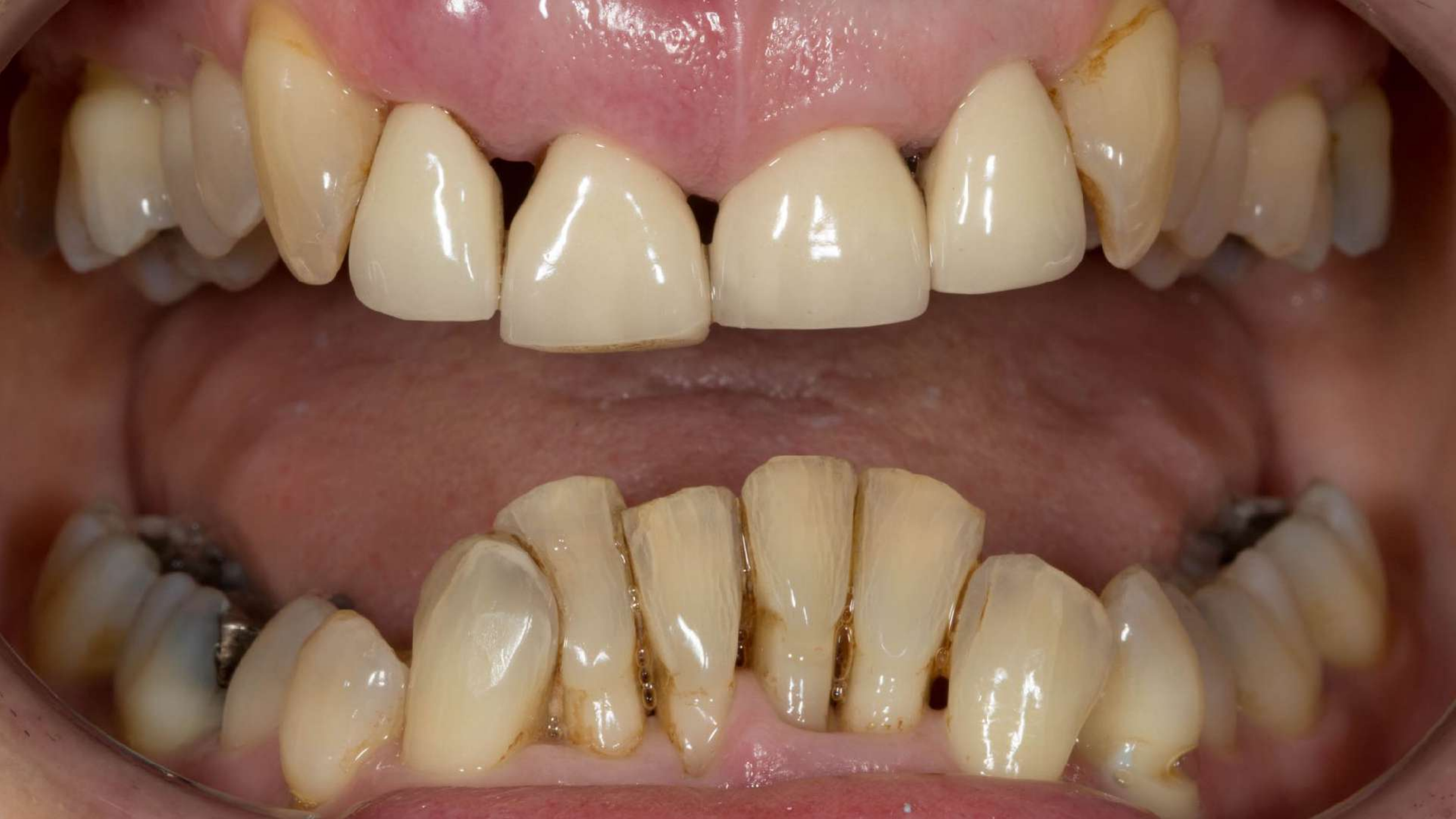Foreword by Jon Kabat-Zinn



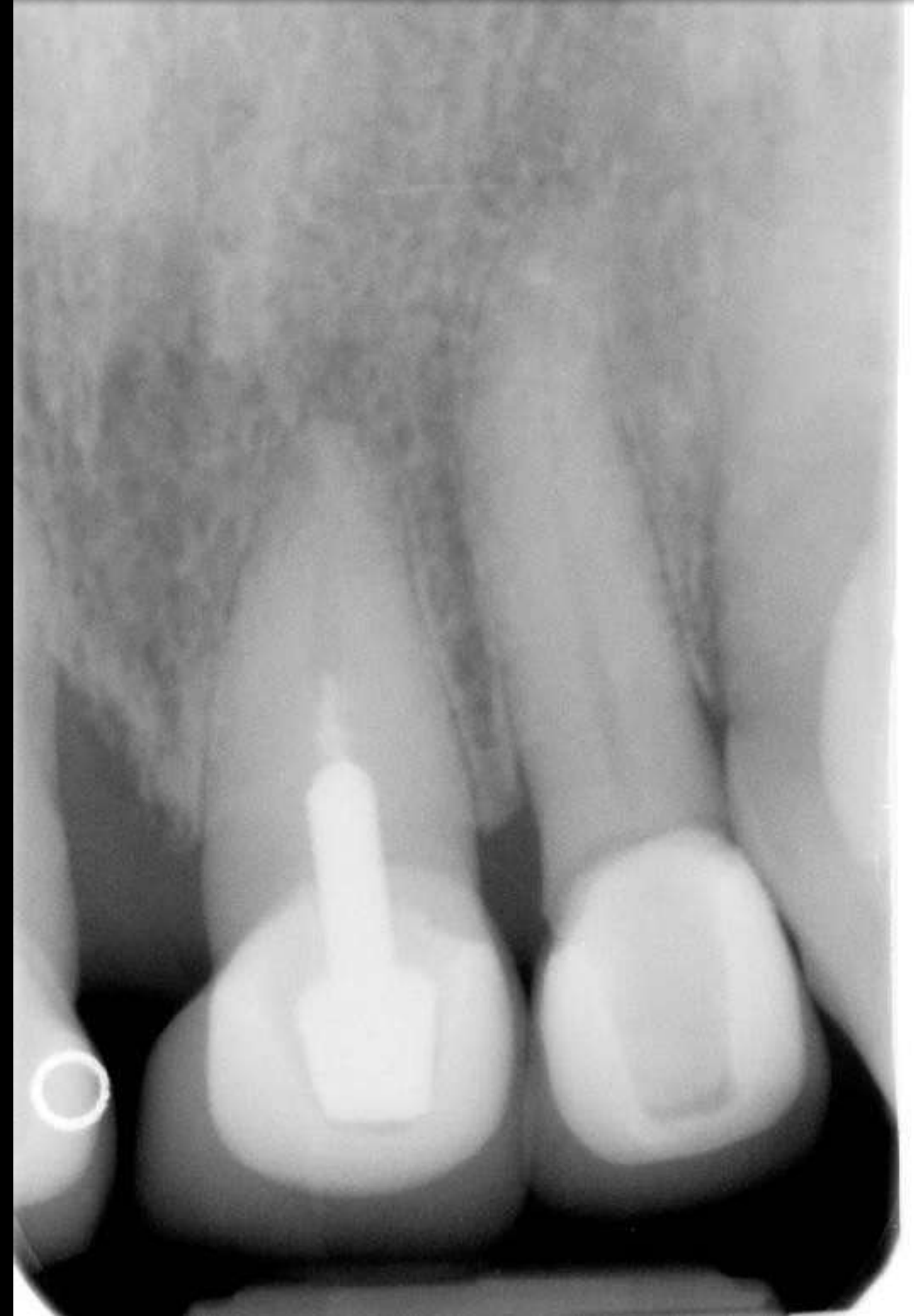
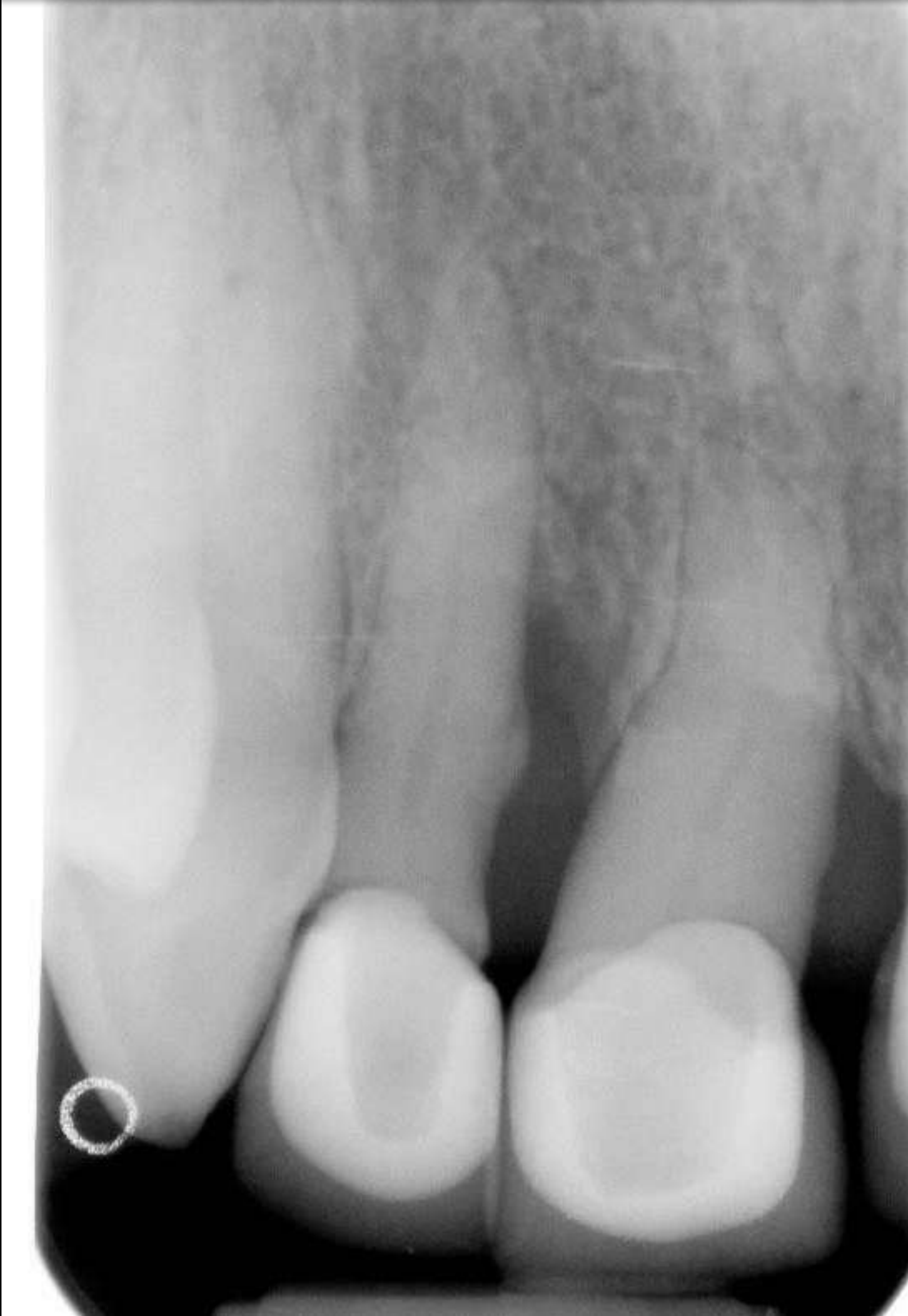
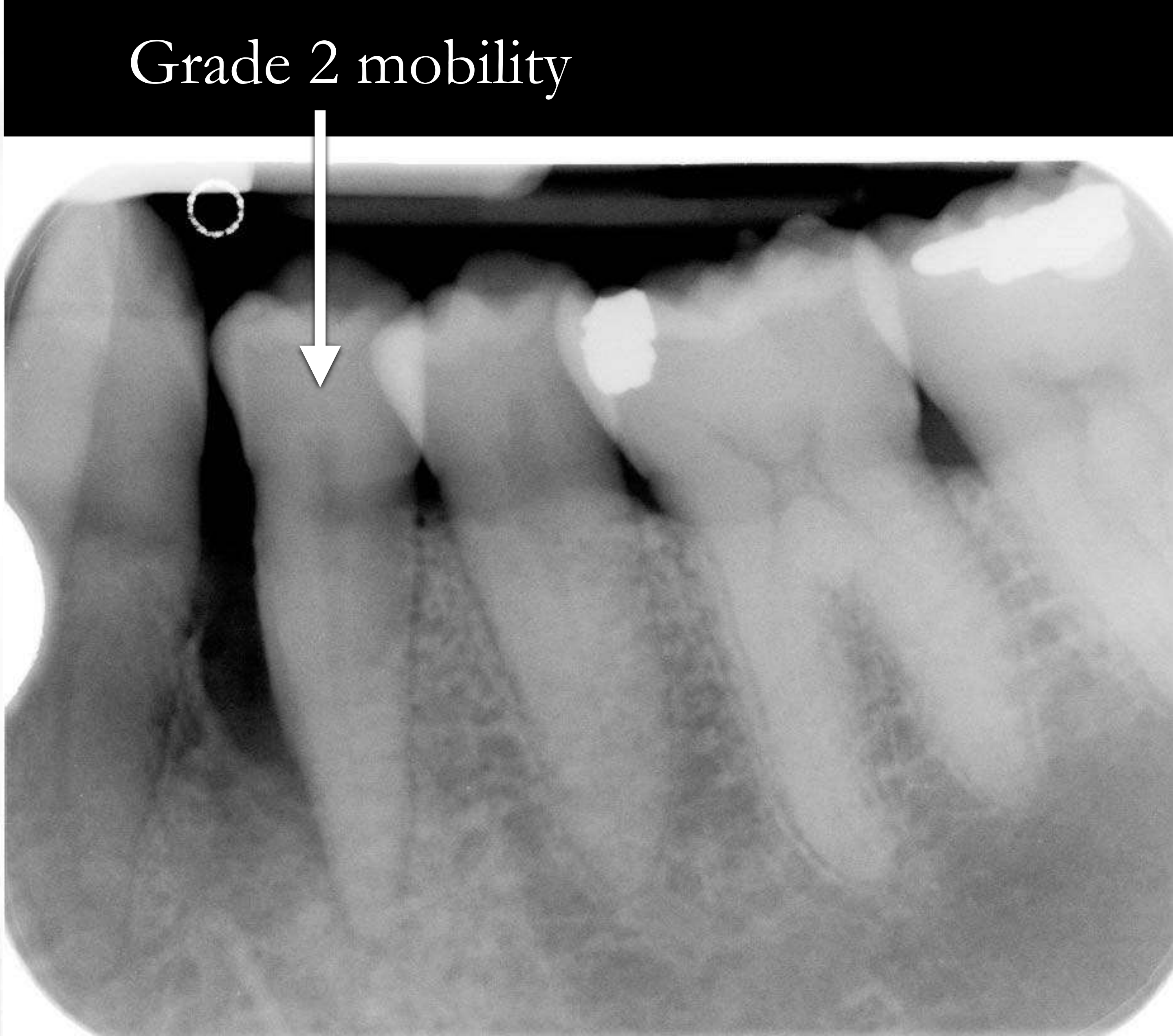
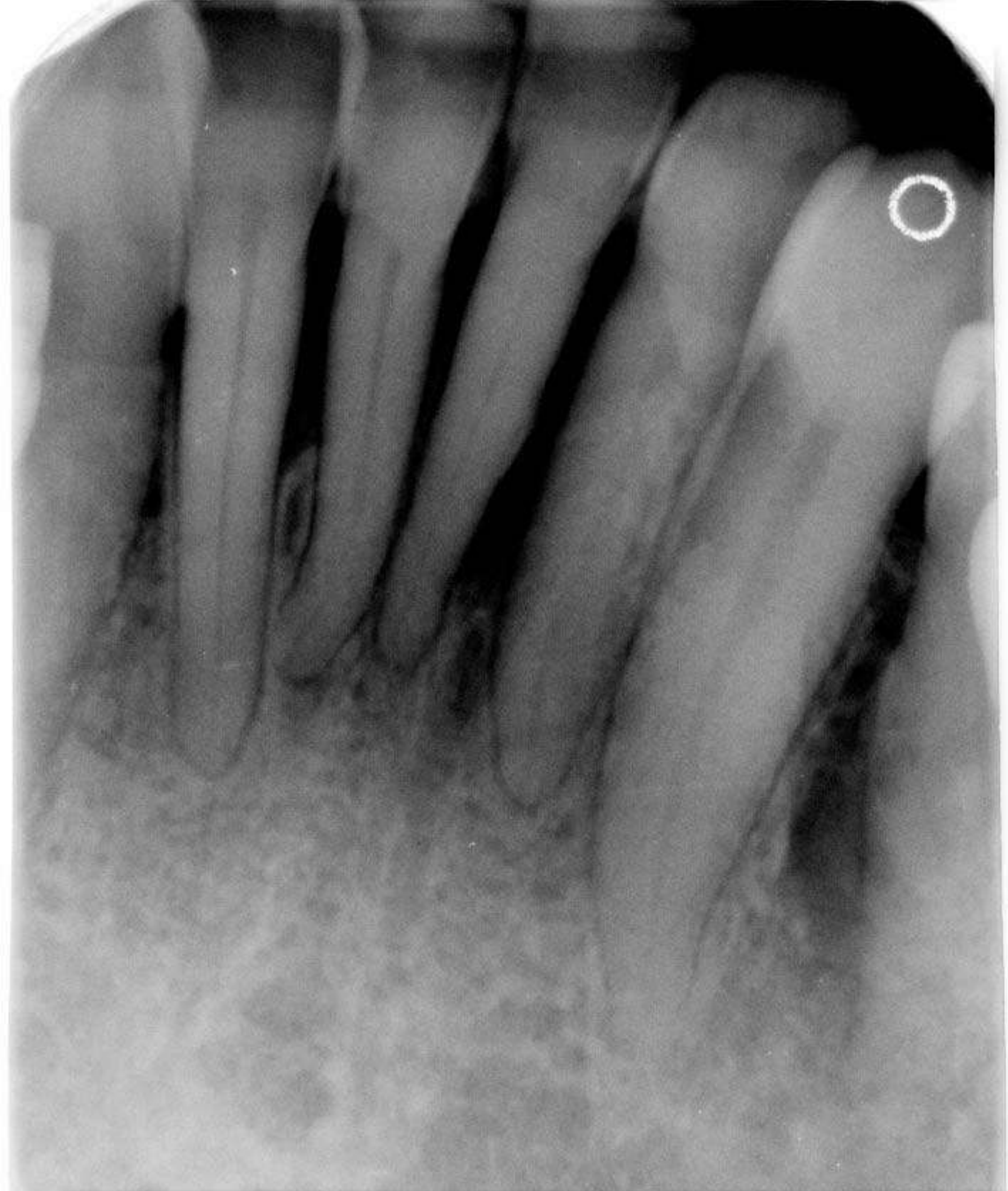The Besford Study Club





Localised periodontitis stage 4 (very severe) Grade C (rapid progression)





Grade 2 mobility

Localised periodontitis stage 4 (very severe) Grade C (rapid progression)

Treatment options

1. Do nothing
2. Periodontal management
3. Partial dentures
4. Bridges
5. Implant supported fixed teeth

Very high smile line

Fixed restoration - difficult to produce natural aesthetics

A close-up photograph of the upper teeth and gums. A semi-transparent dark grey rectangular box is centered over the image, containing white text. The text is arranged in three lines: 'Mk 1 Immediate P/P' on the top line, '9 months' on the middle line, and 'Mk 2 P/P' on the bottom line. The teeth are yellowish-white with some staining, and the gums are pink.

Mk 1 Immediate P/P

9 months

Mk 2 P/P

Nam

Treatment plan No 1

Date estimate accepted:

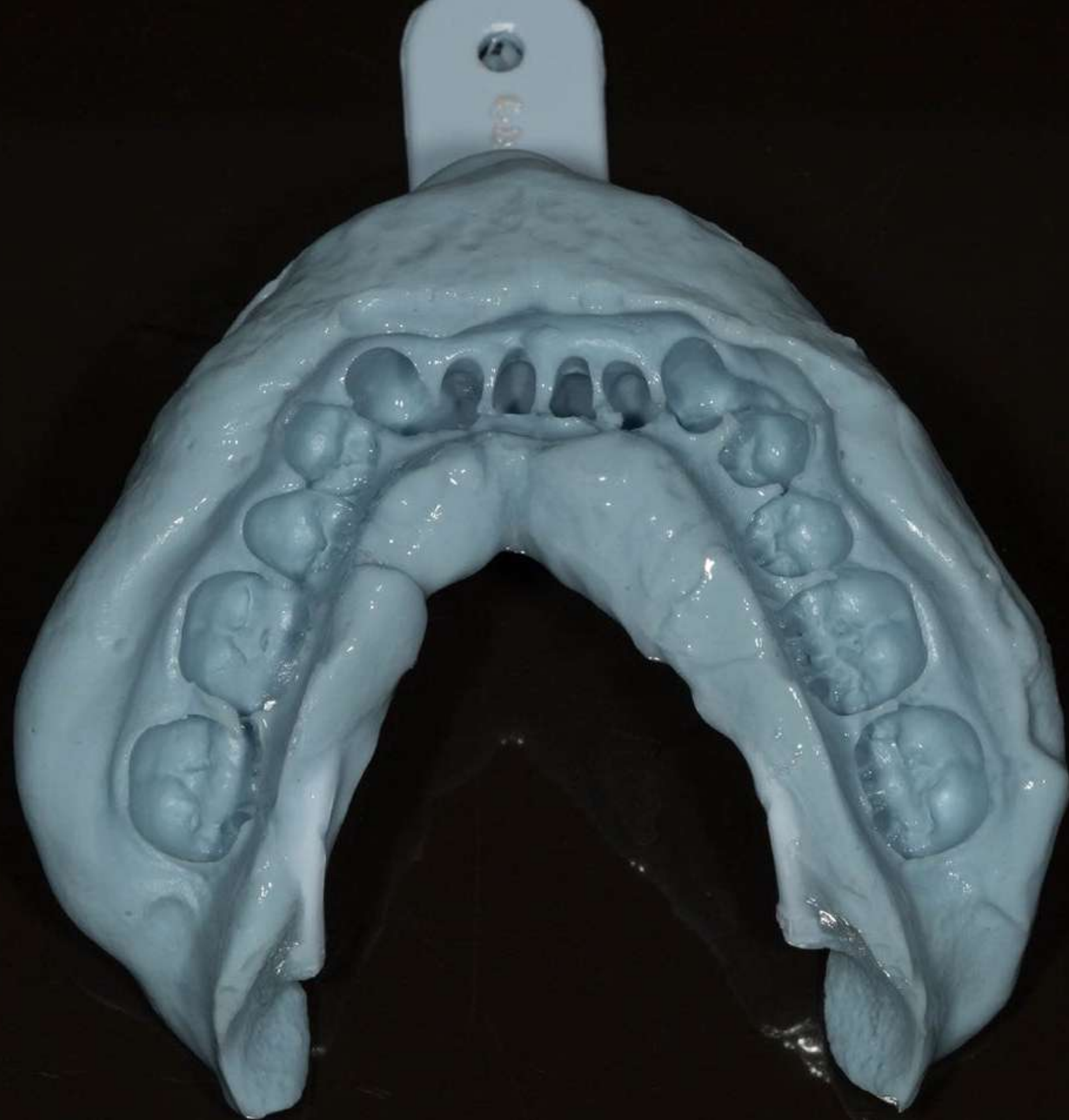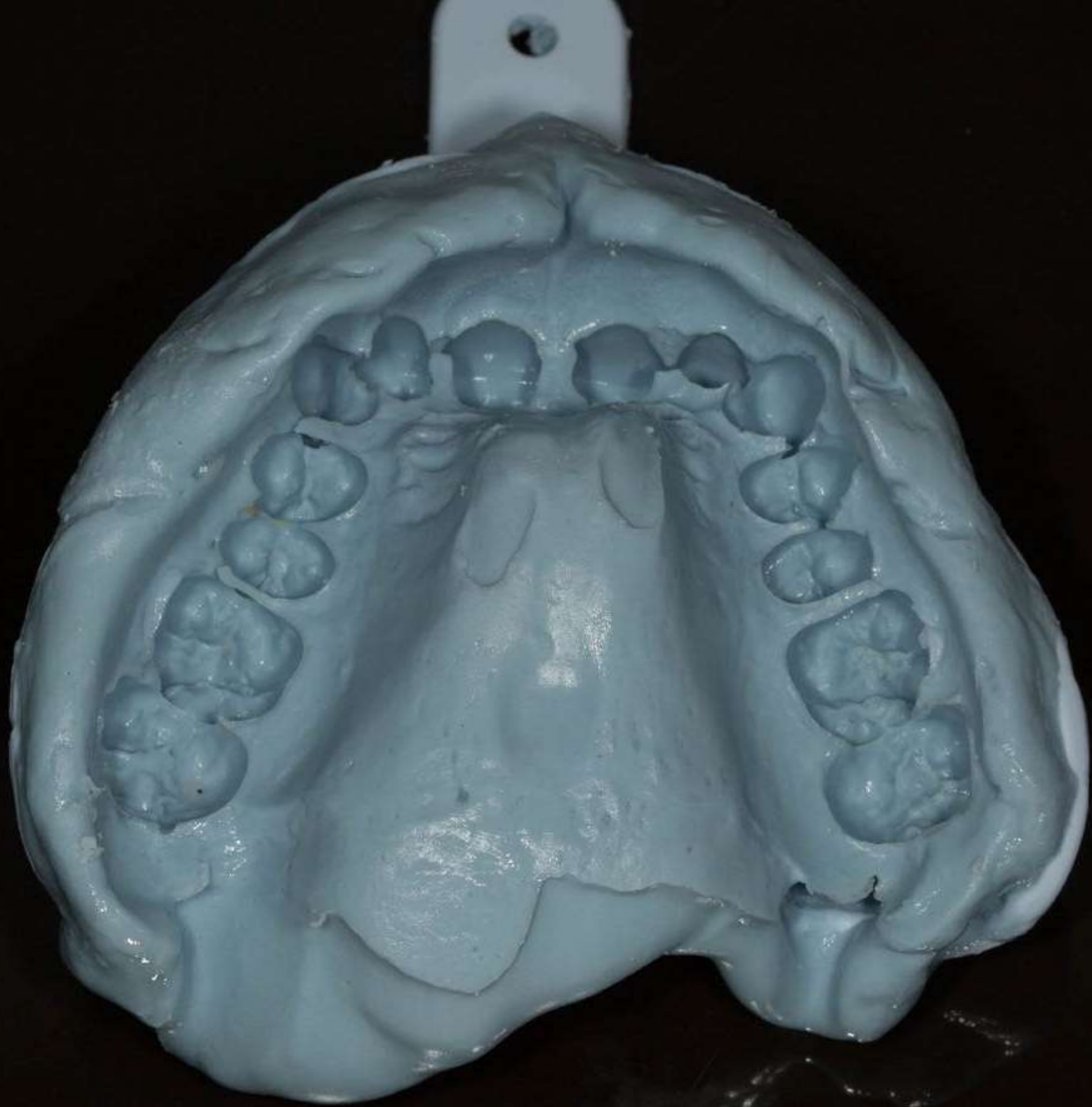Objective:

Preferred times:

- Mk 1 Immediate interim partial denture with removal of 2-2
- Teeth whitening – only if wanted no cost extra
- Periodontal therapy – Syed Abad after visit 3
- Mk 2 Definitive metal based partial dentures 2-2


MAKE SURE BOOKED IN WITH SYED REGARDING REMAINING TEETH

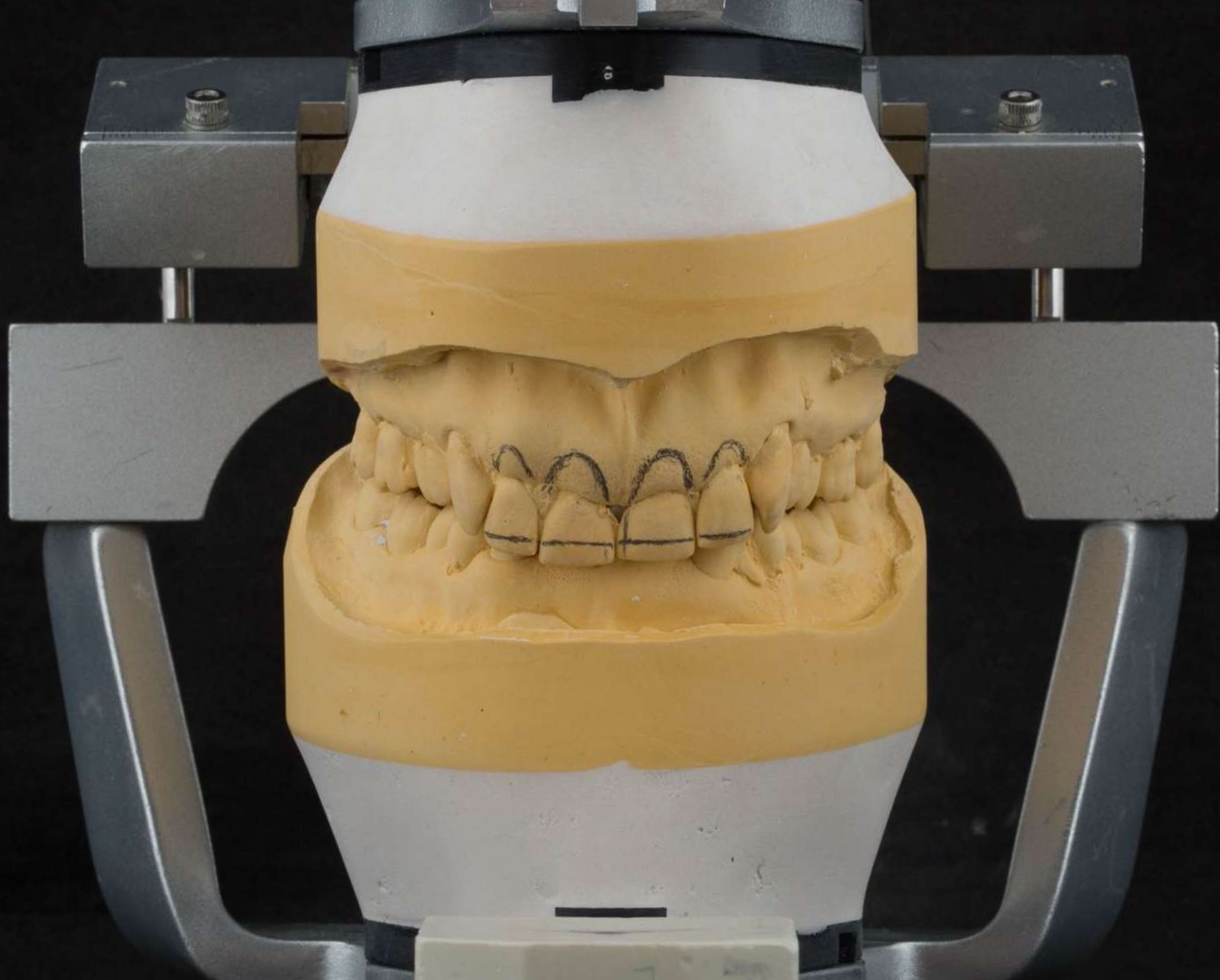
Visit	Treatment and result	Fee (£)	Time required (Hrs)	Appointment		Time Gap	Laboratory to produce	Lab and implant parts fee (£)
				Date	Time			
1.	Impressions	450	1			2 weeks	Immediate acrylic based denture upper 2-2	750
2.	Immediate dentures - fit Extract UL12, UR12 Adjust lower 2-2 to create more space in the bite	1125	2 ½			1 week		0
3.	RV 1 Impression for whitening trays if wanted	450	1			2 weeks	Whitening tray upper and lower	0
4.	Review – x 6 over 12 months Do impression – for special tray and designing appropriate denture design May require new interim partial denture	2000	4			9 -12 months	Special tray	0
5.	Prepare mouth for upper denture Check impression	450	1			2 weeks	Check impression – check design	0
6.	Refine preparations Definitive impression	450	1			2 weeks	Try in wax	0
7.	Teeth try in	250	½			2 weeks	CoCr framework	300
8.	Metal <u>framework</u> try in	450	1			2 weeks	Try in with teeth on	0
9.	Try in with teeth on frame	450	1			2 weeks	Finish	1500
10	Fit	450	1			1 week		0
11	Review and post op photos	450	1					0
12	Contingency for additional denture reviews and remakes, relines etc...	450	1					0
Total		7425				52 weeks		2550

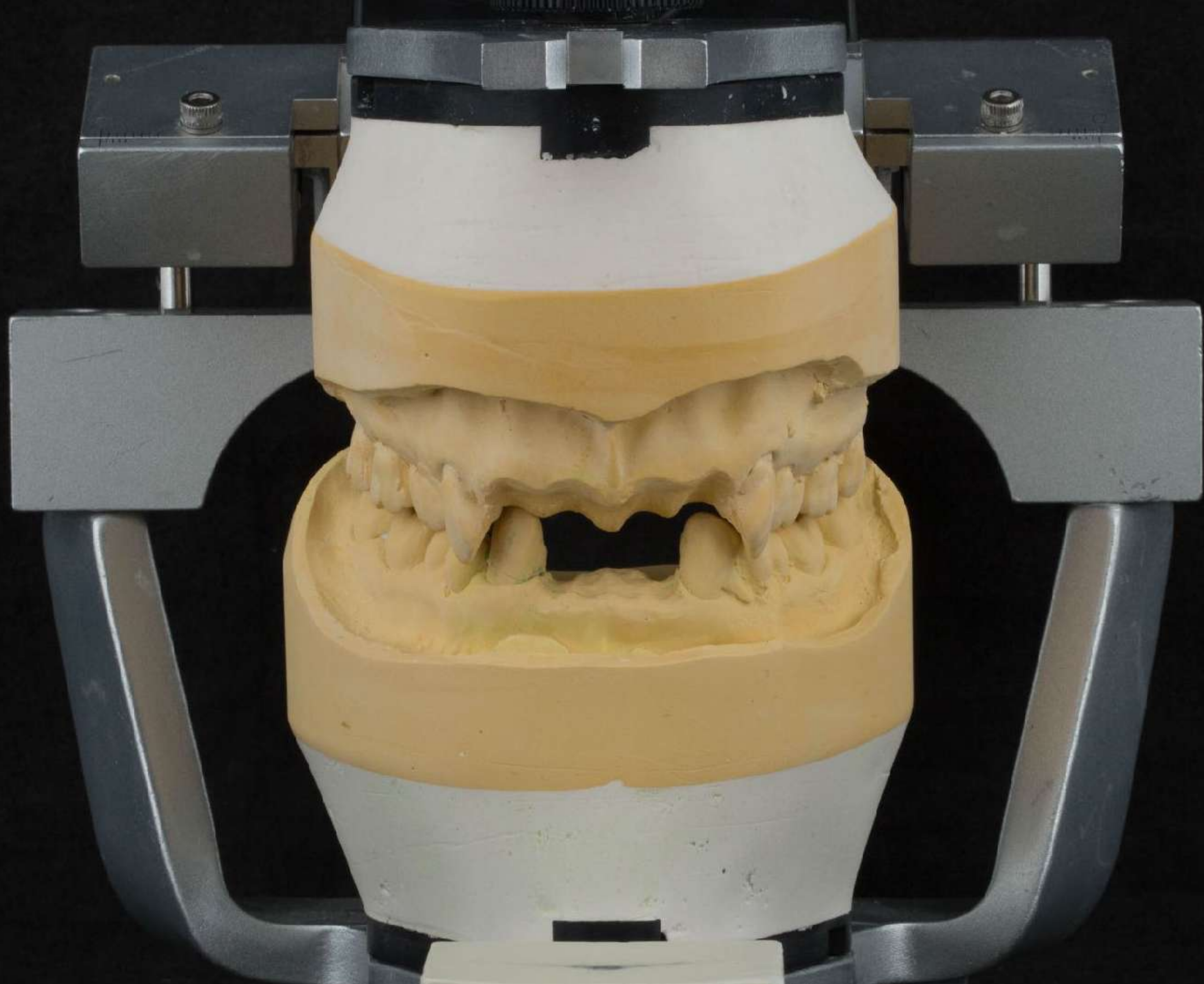


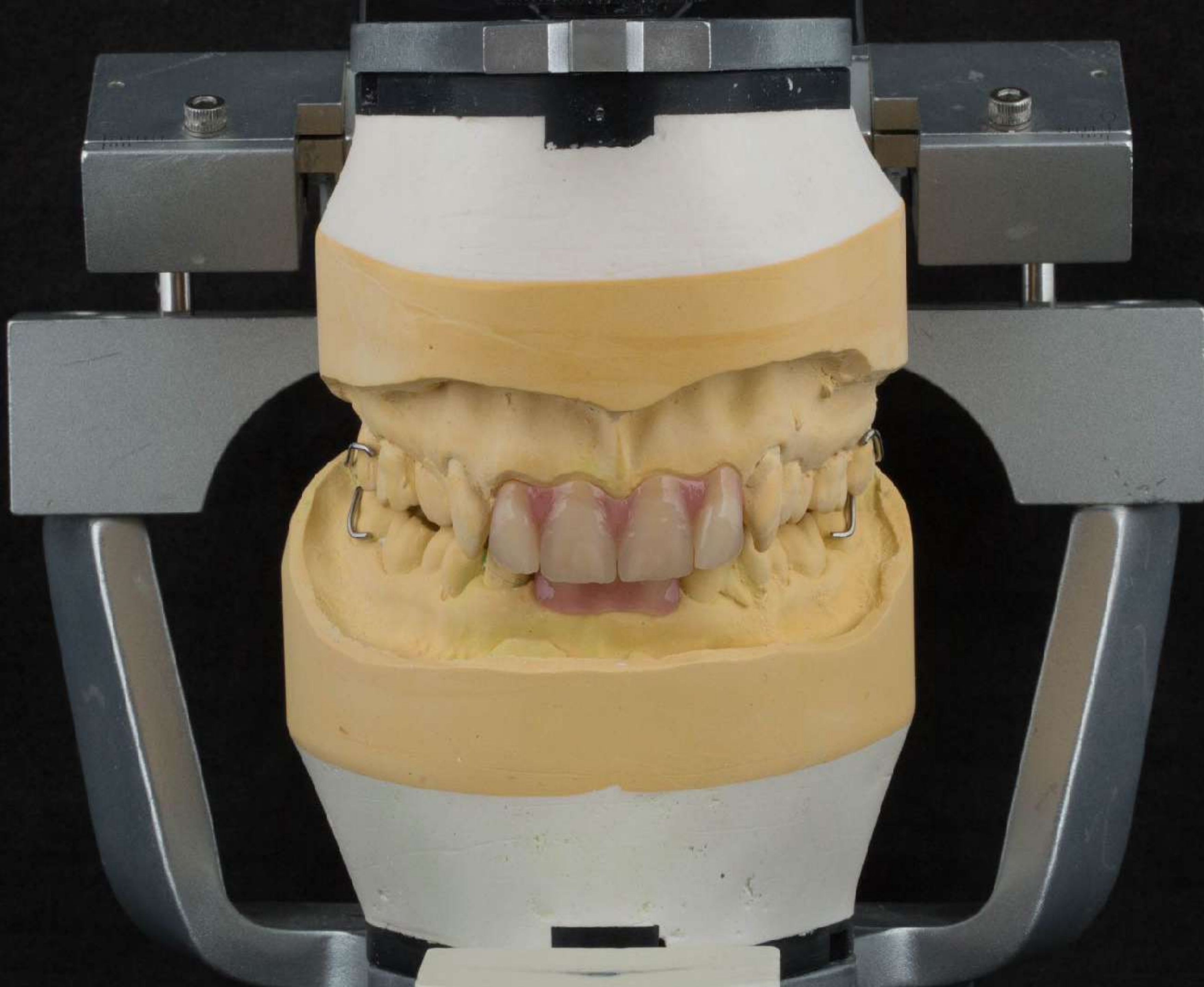
Primary impressions

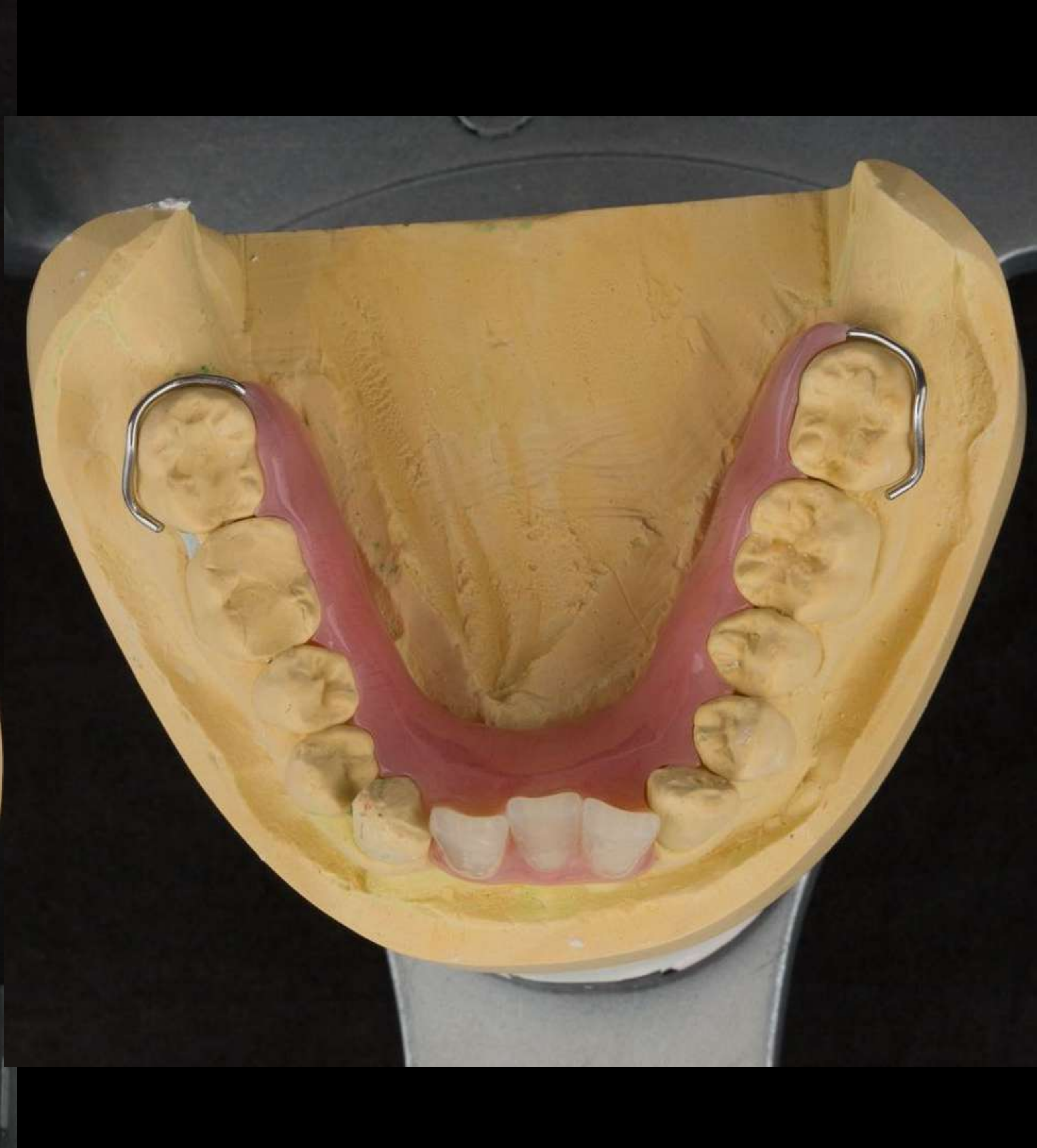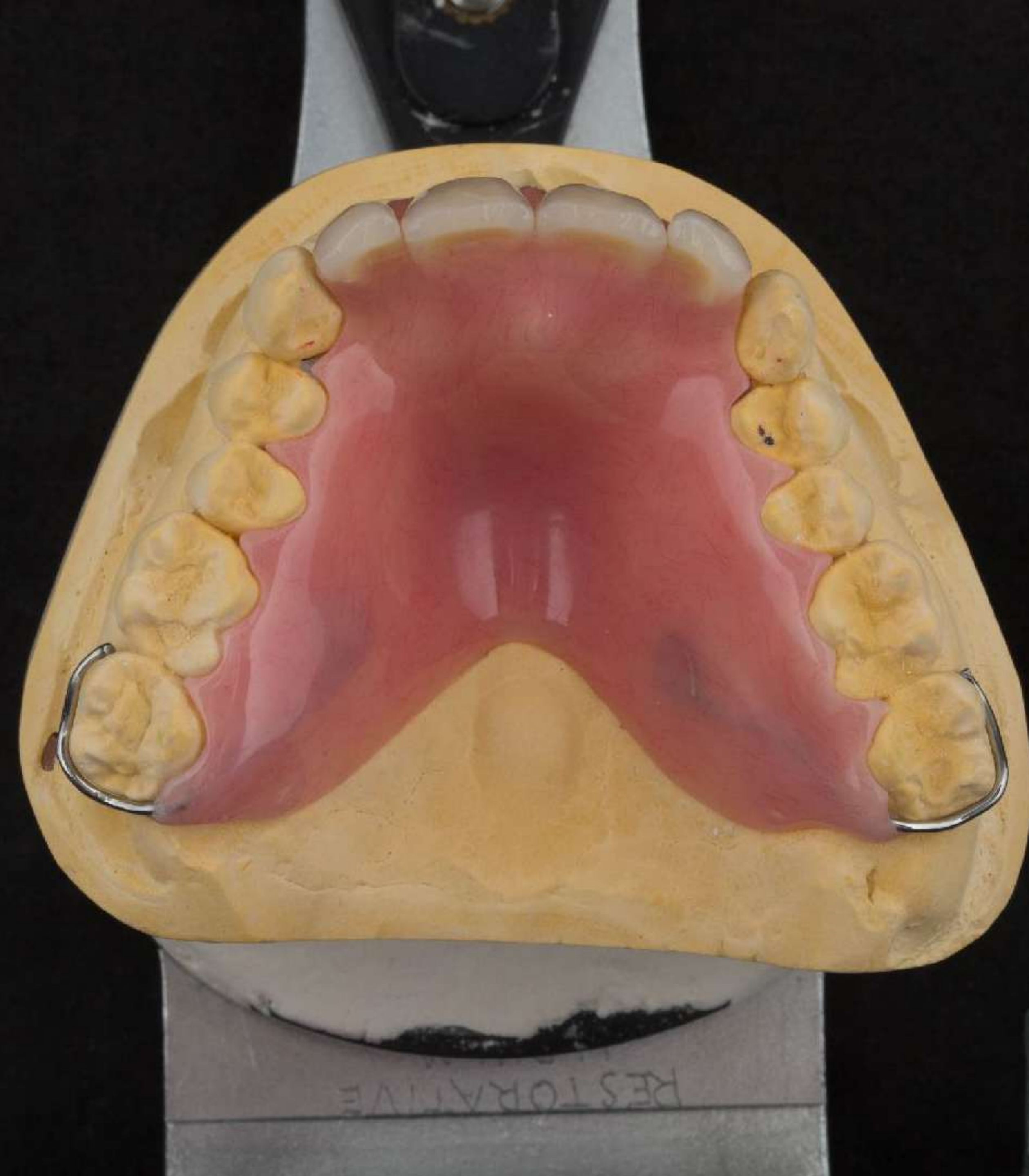Aesthetic improvement



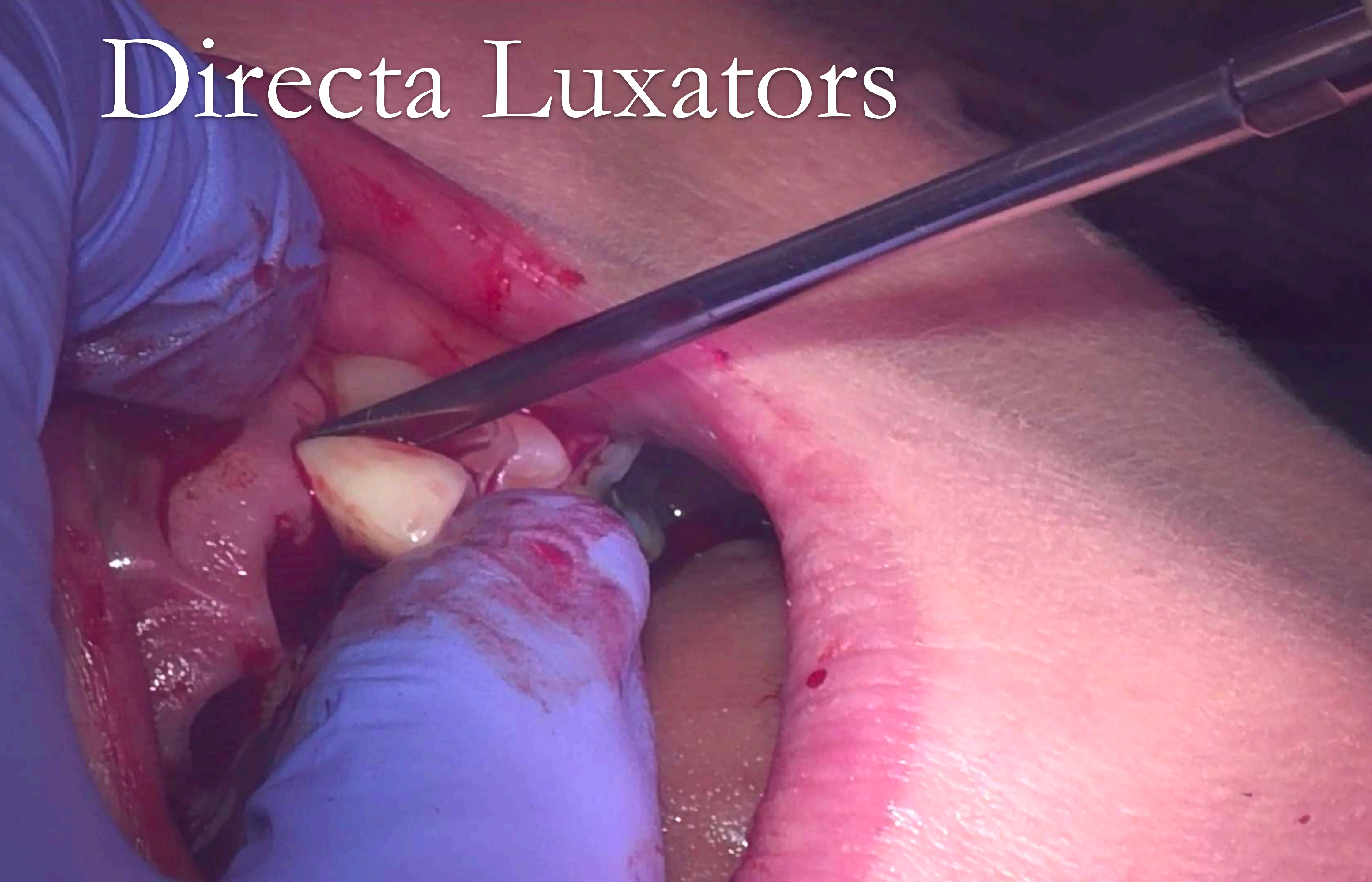


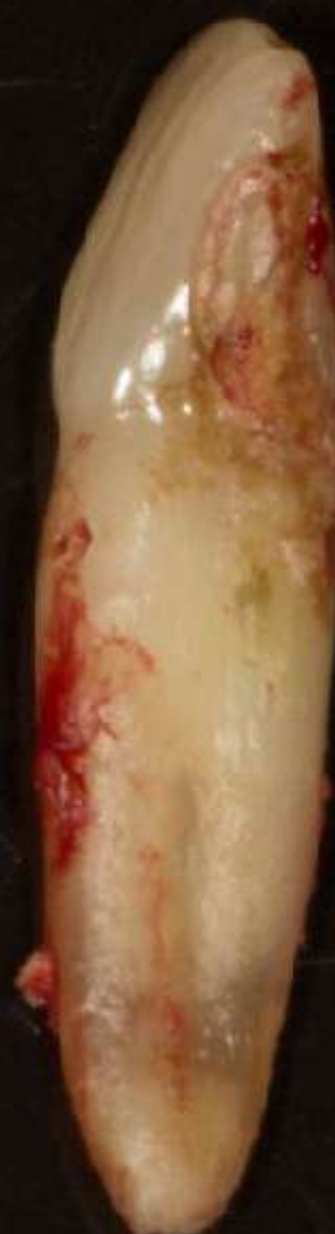
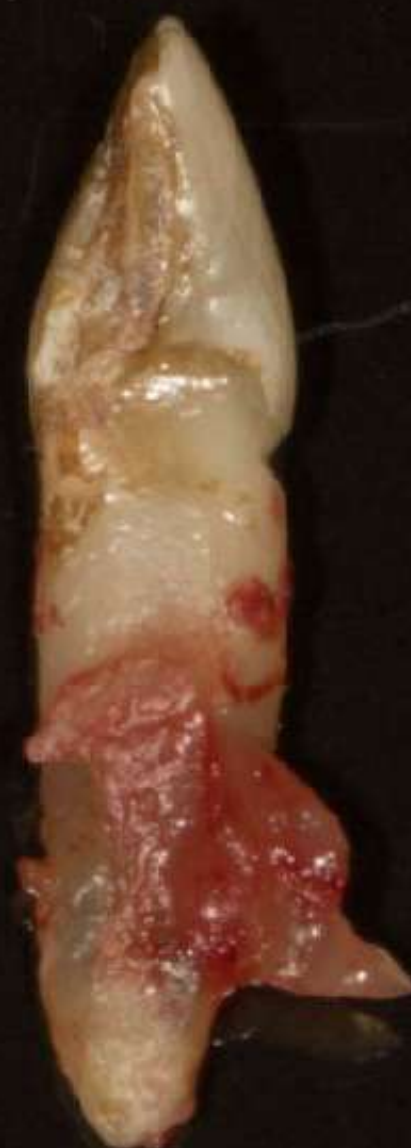
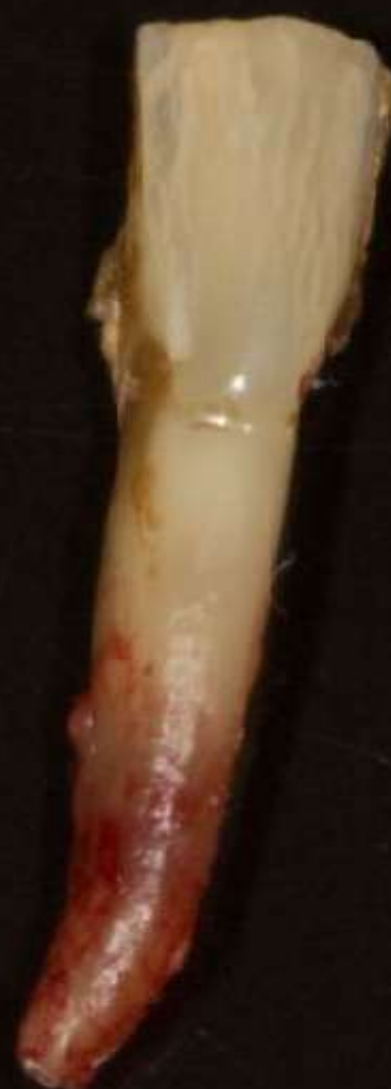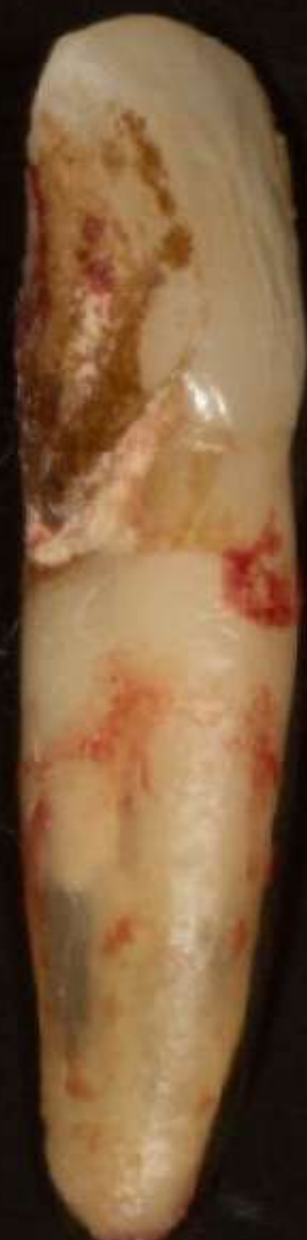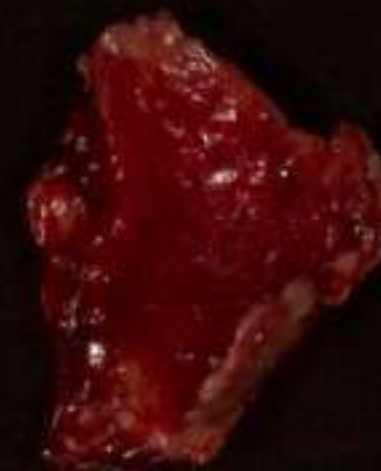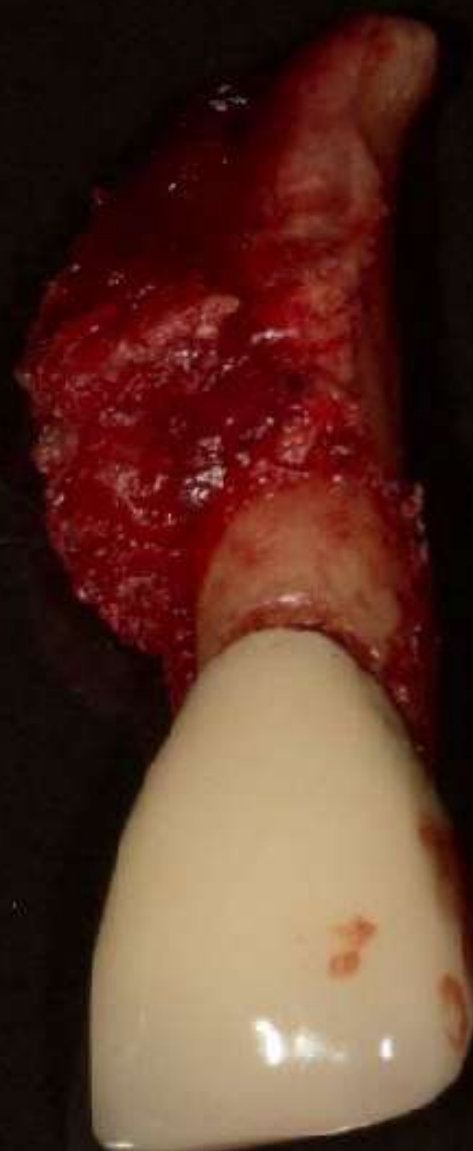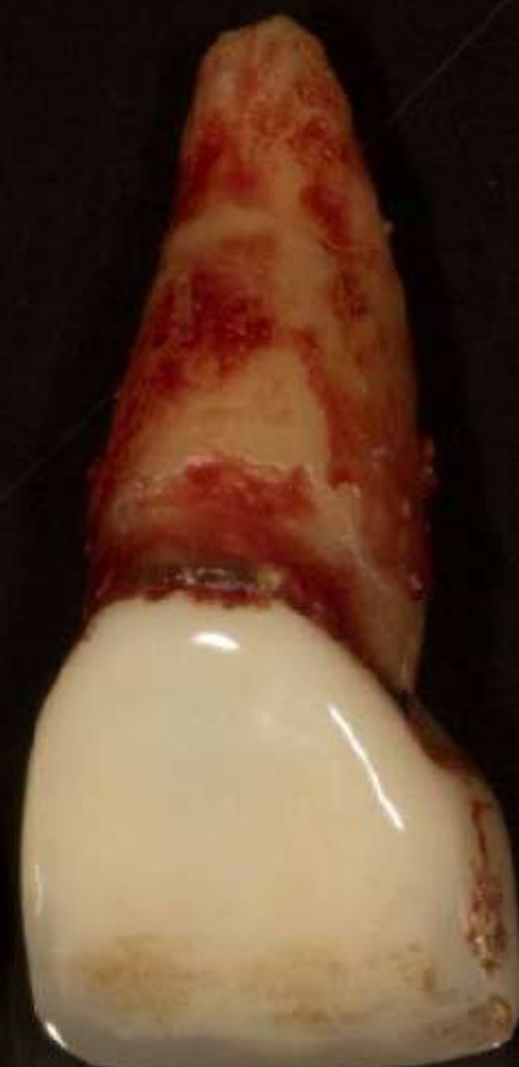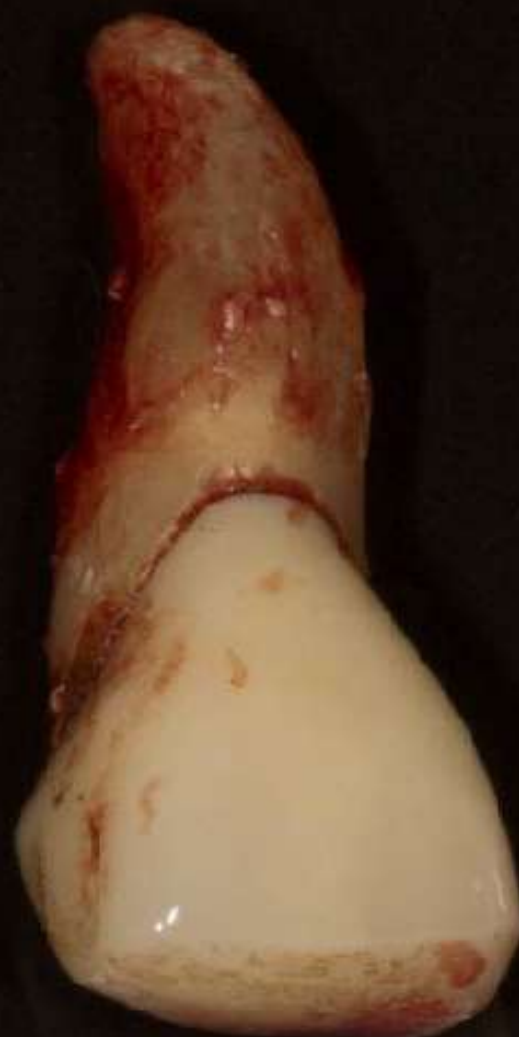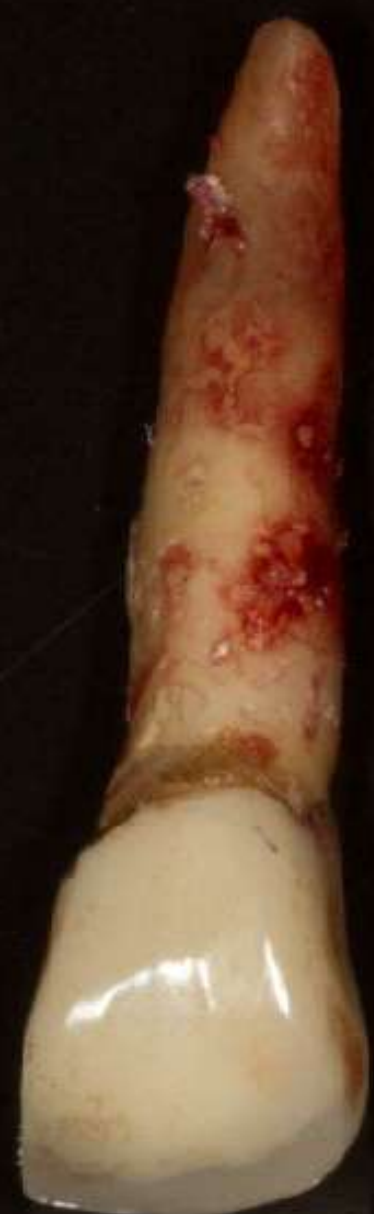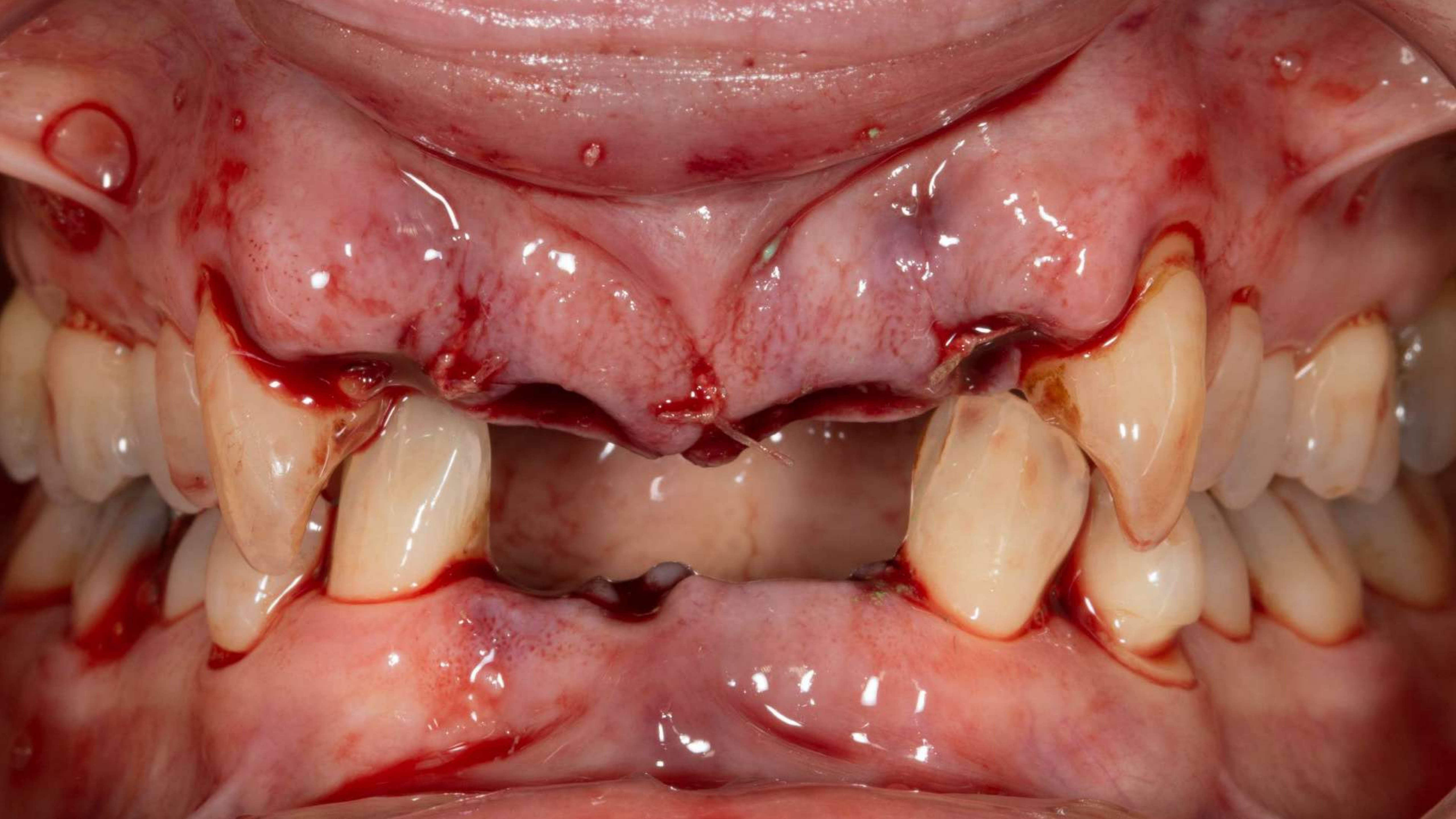




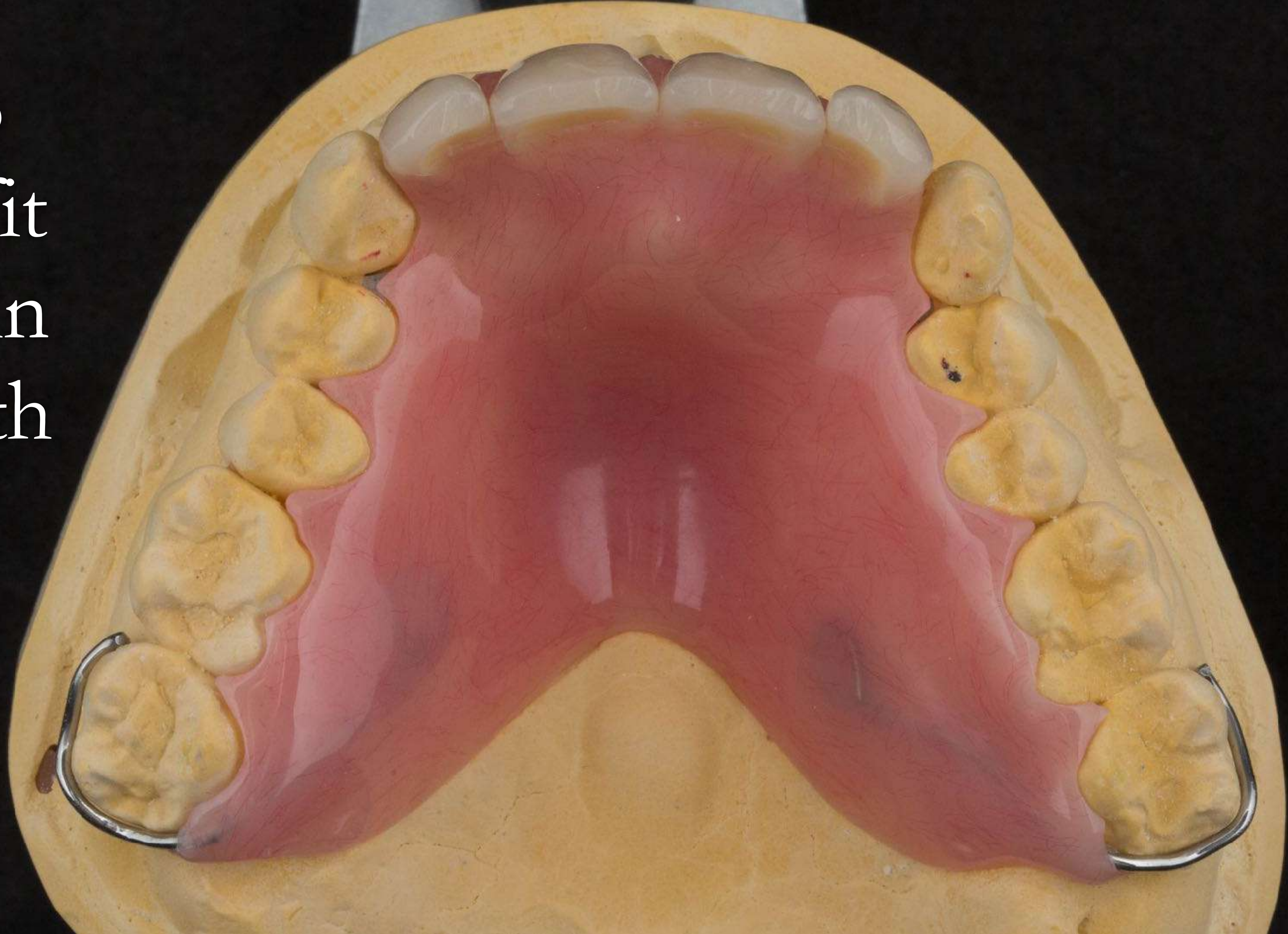Directa Luxators

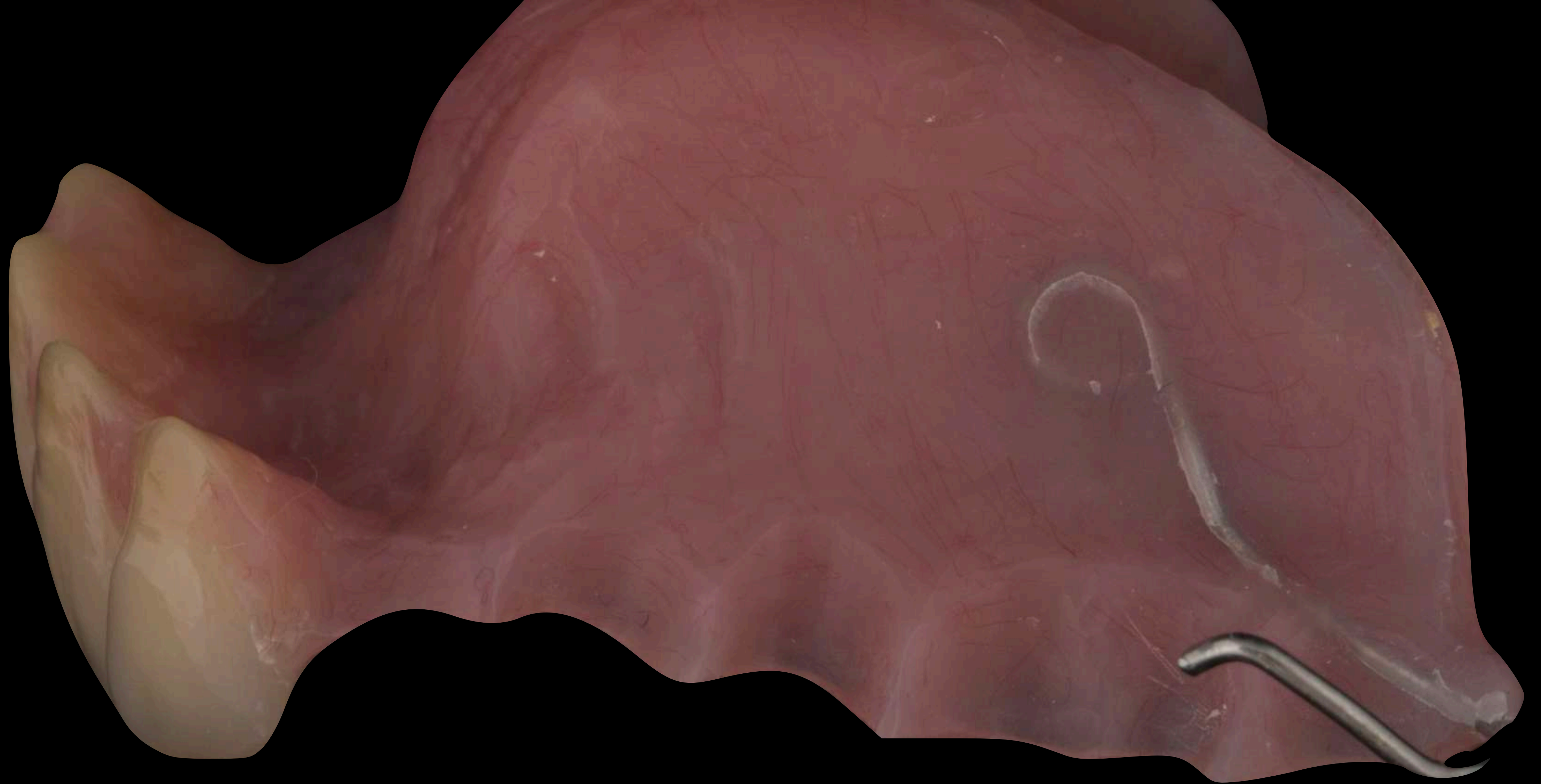






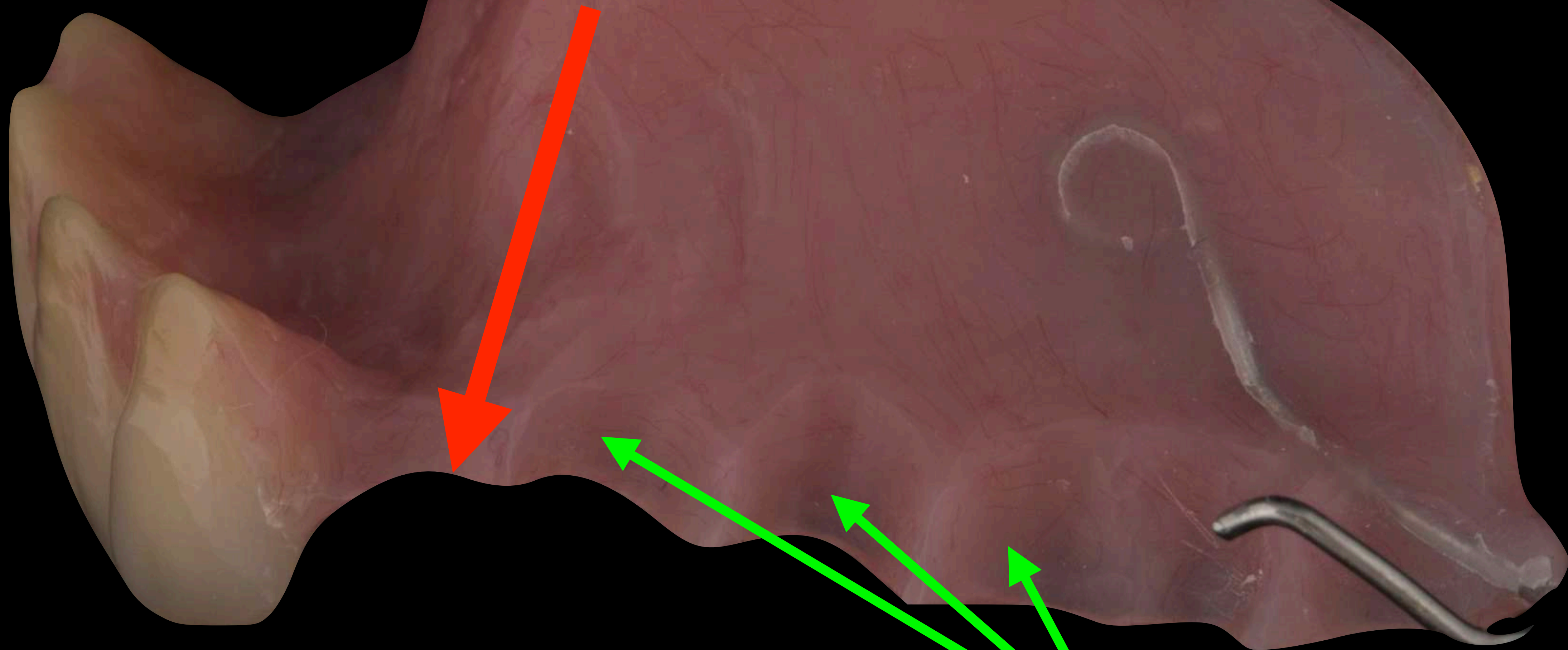
How to
make it fit
like this in
the mouth



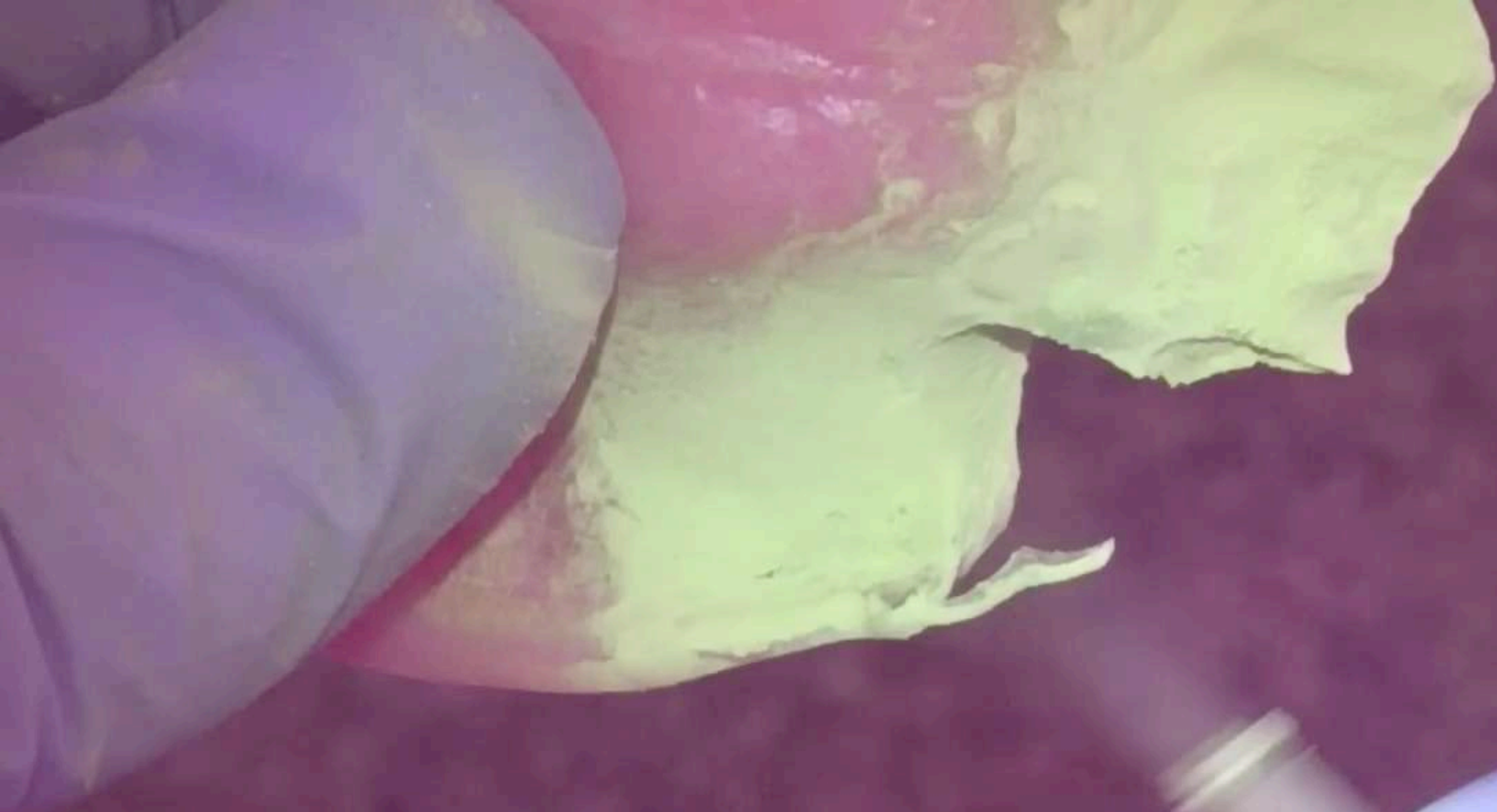


Dentures rarely fit properly

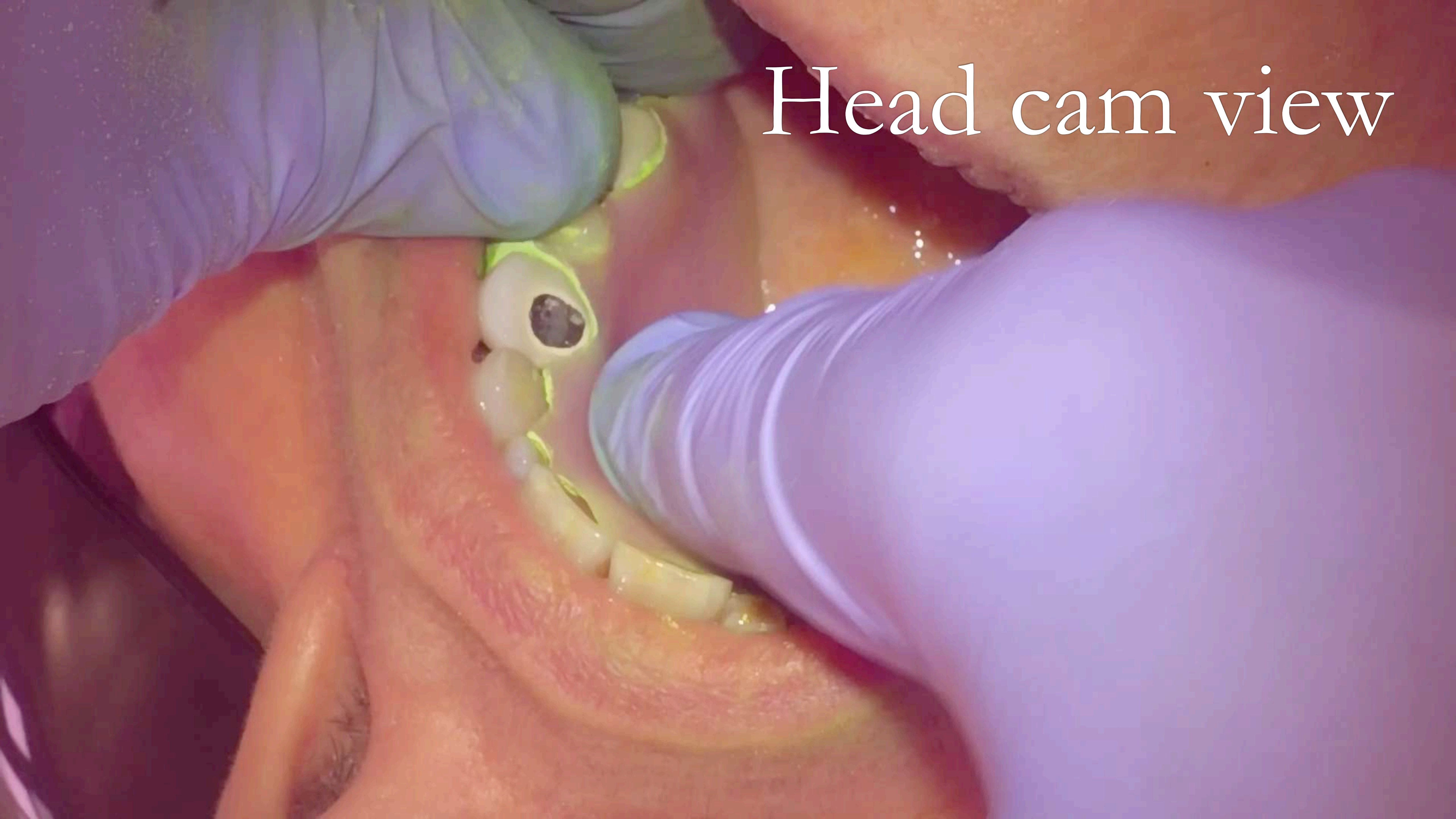Almost never adjust the collet edge

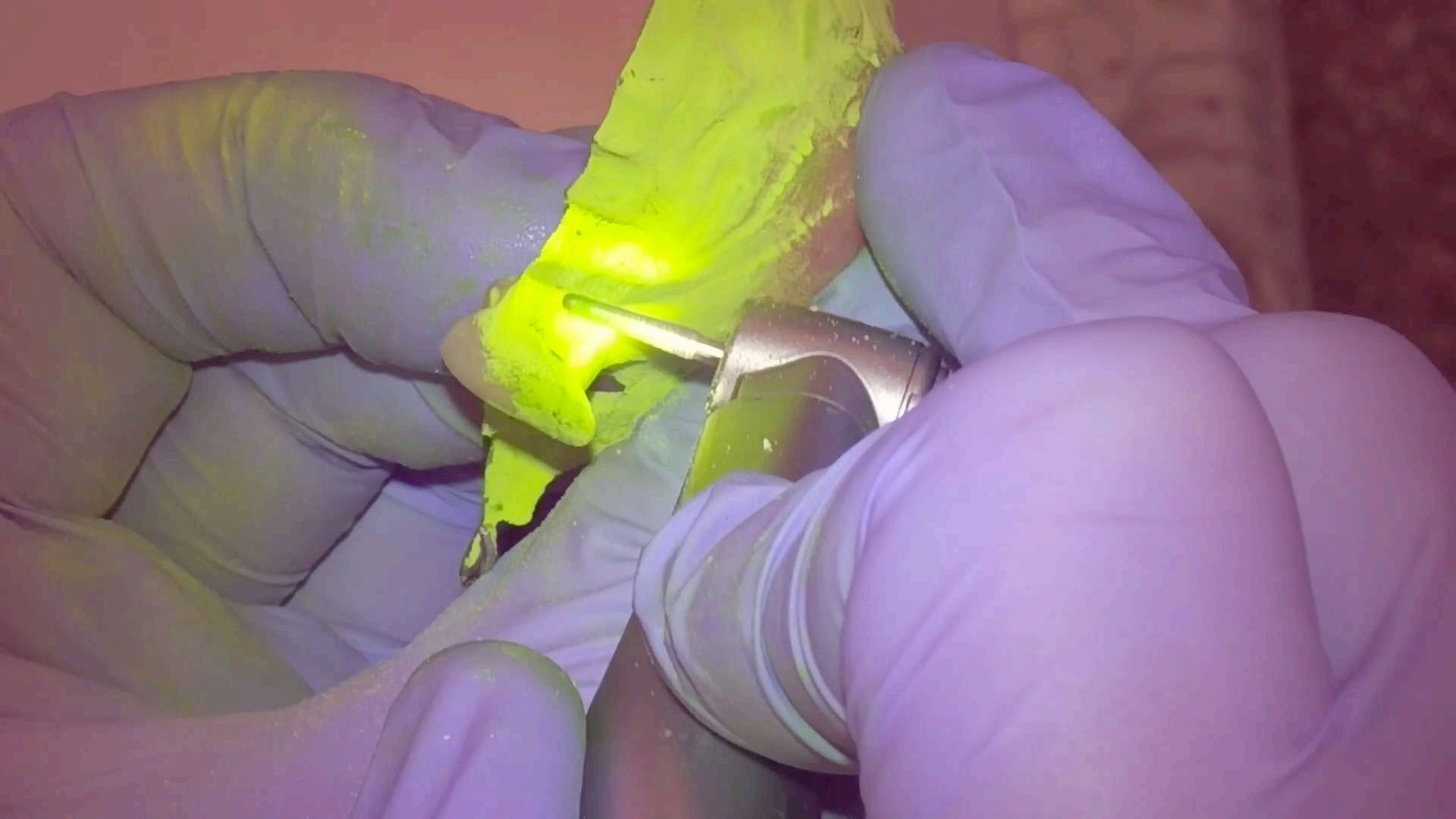


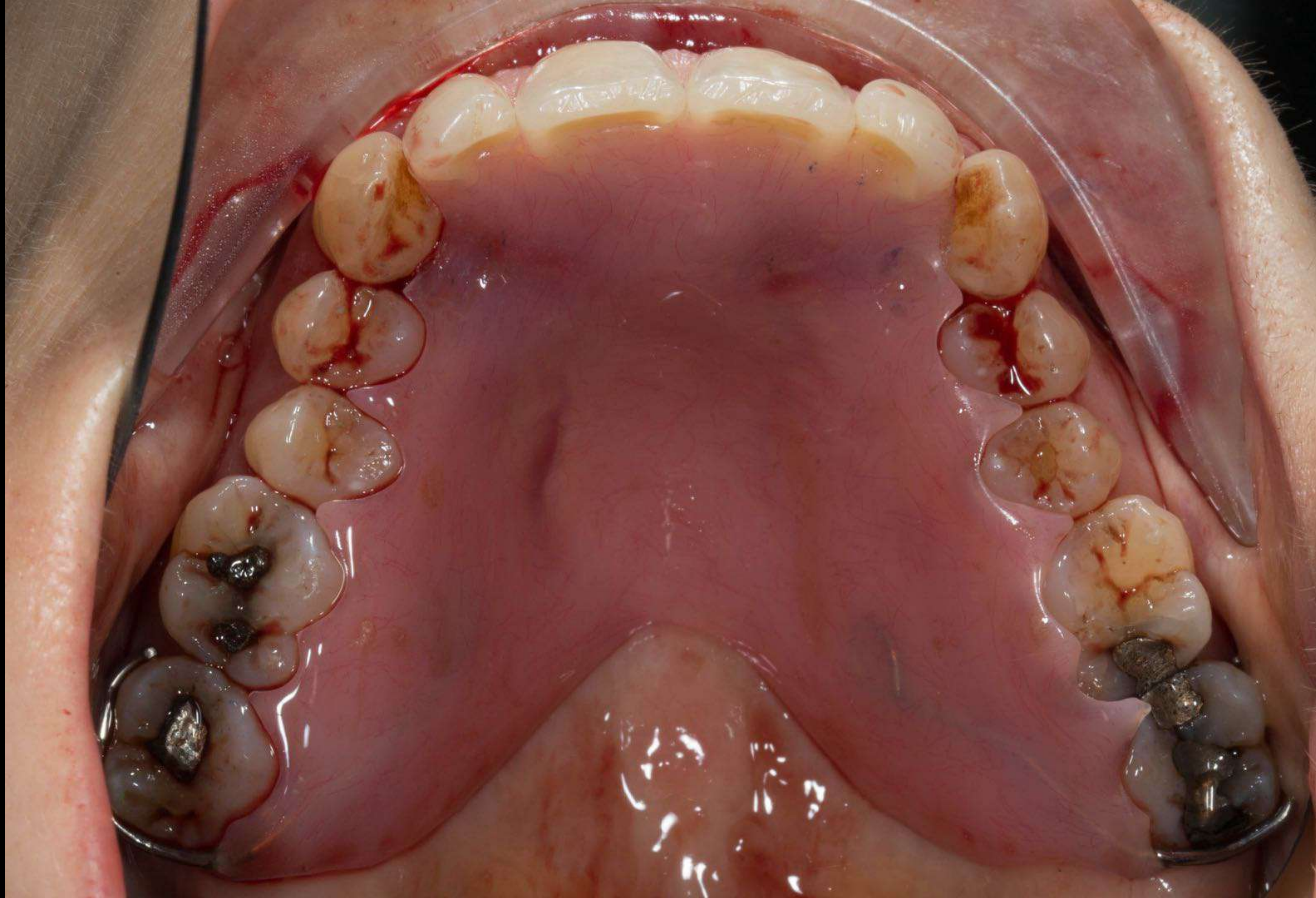
Adjust below the collet edge



Head cam view

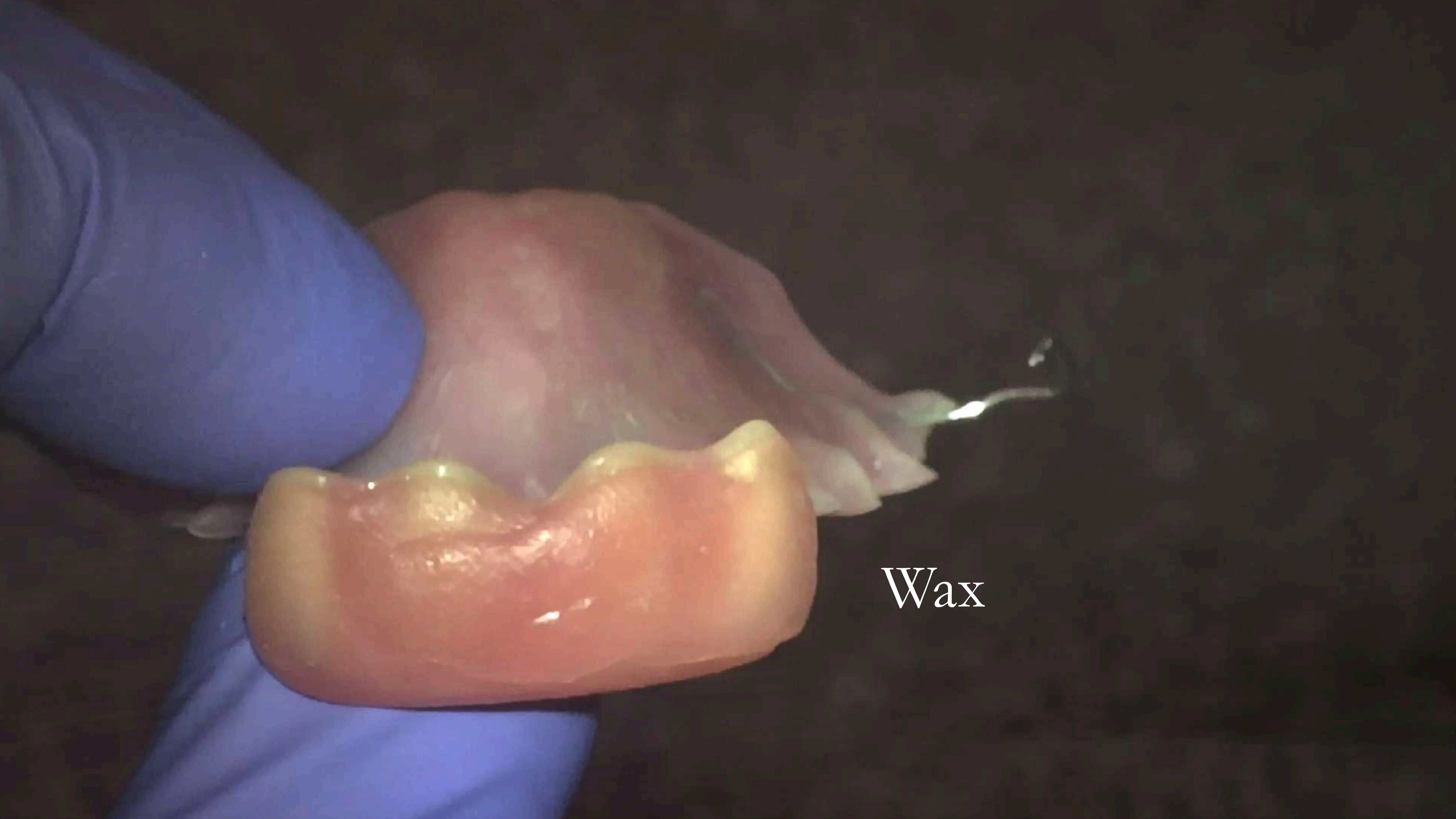





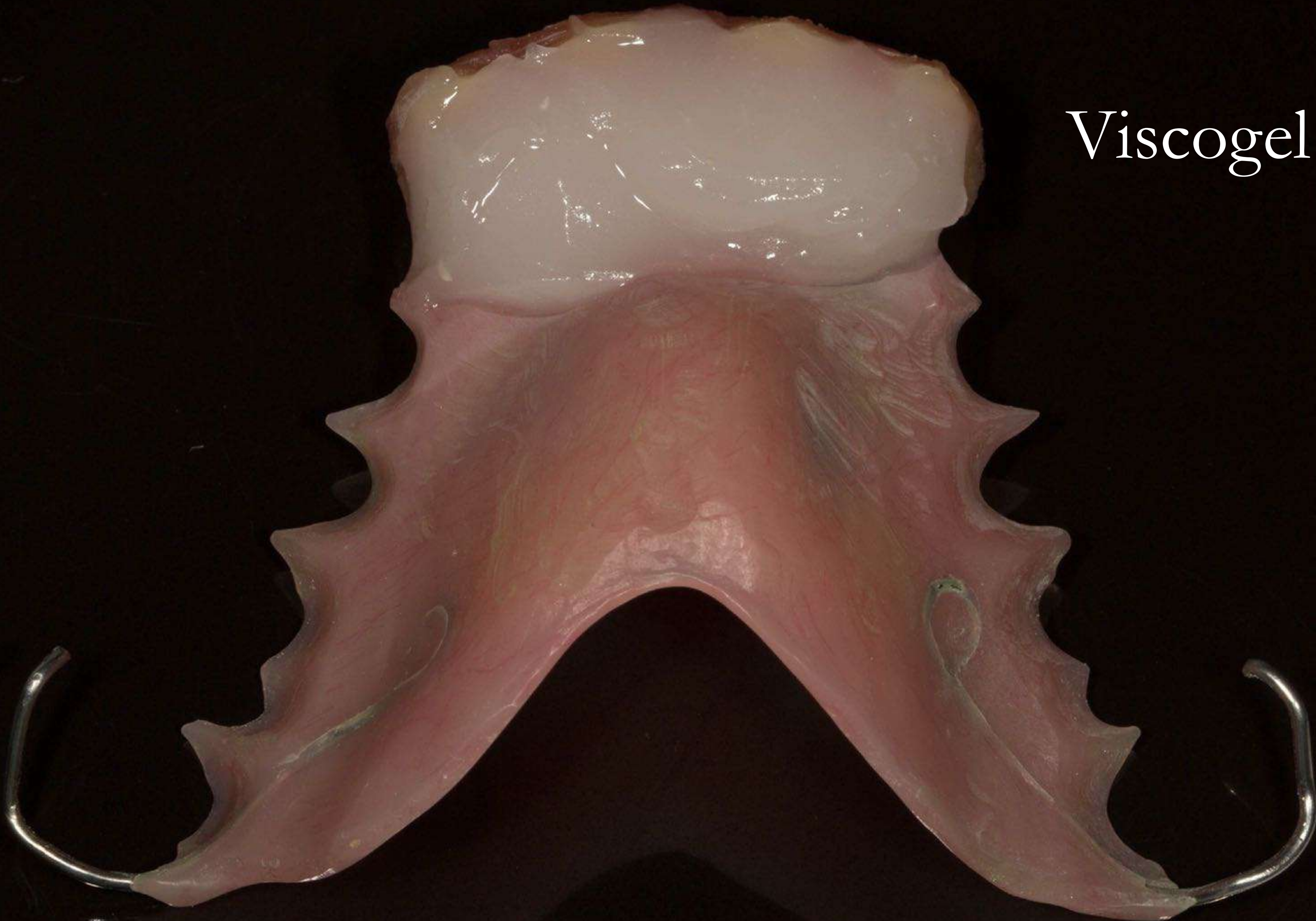
Gap

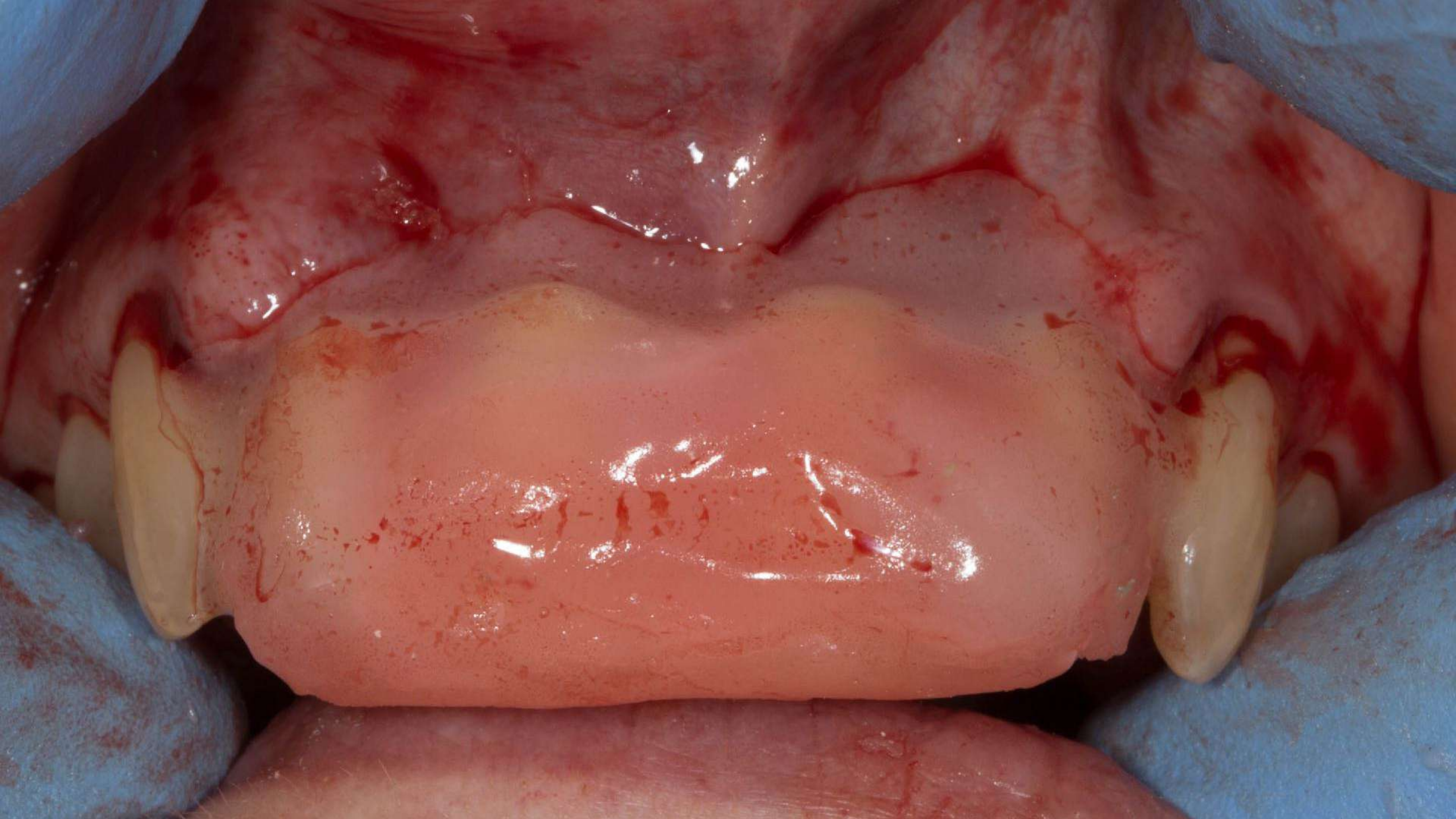


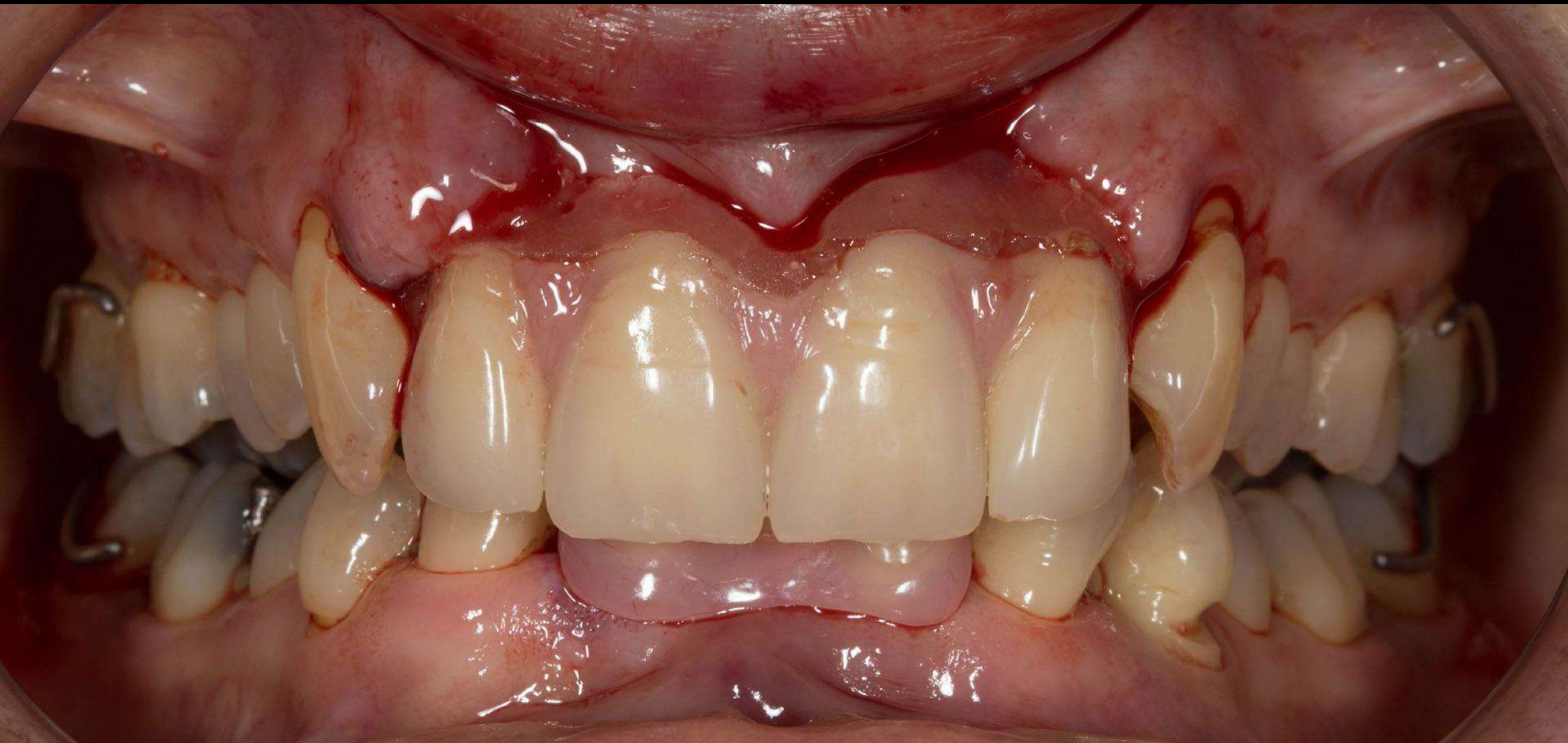

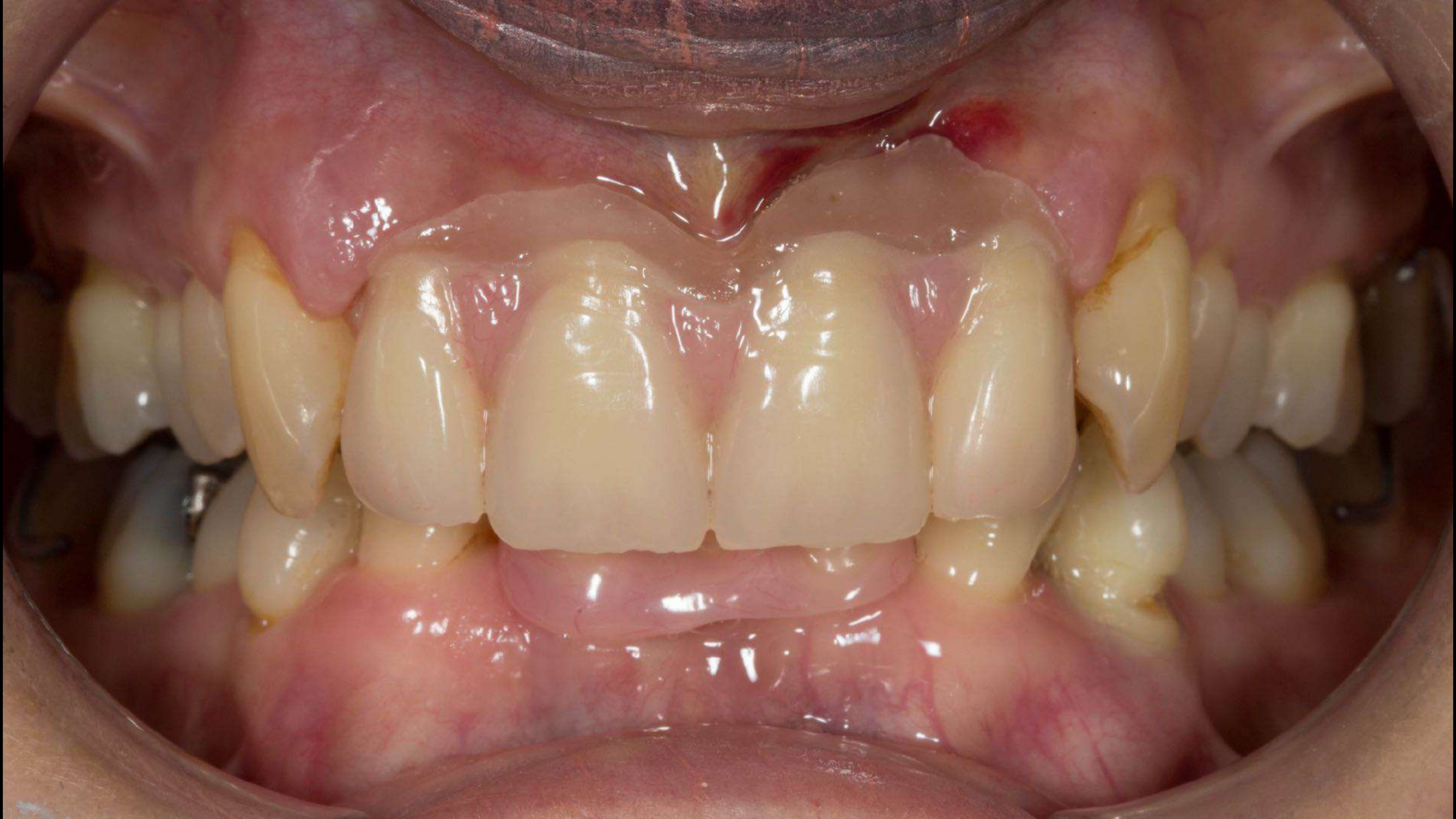Wax

Viscogel

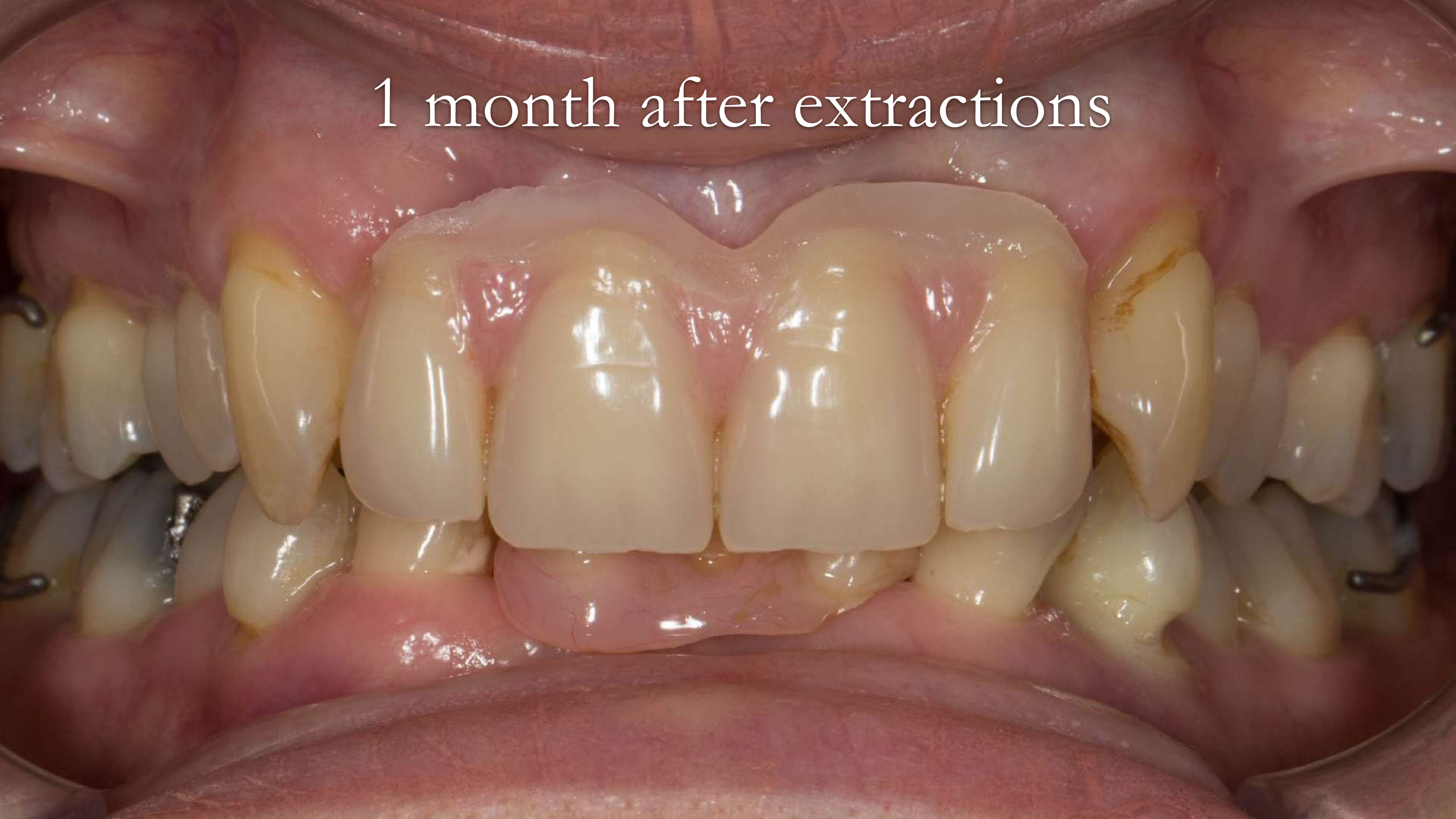




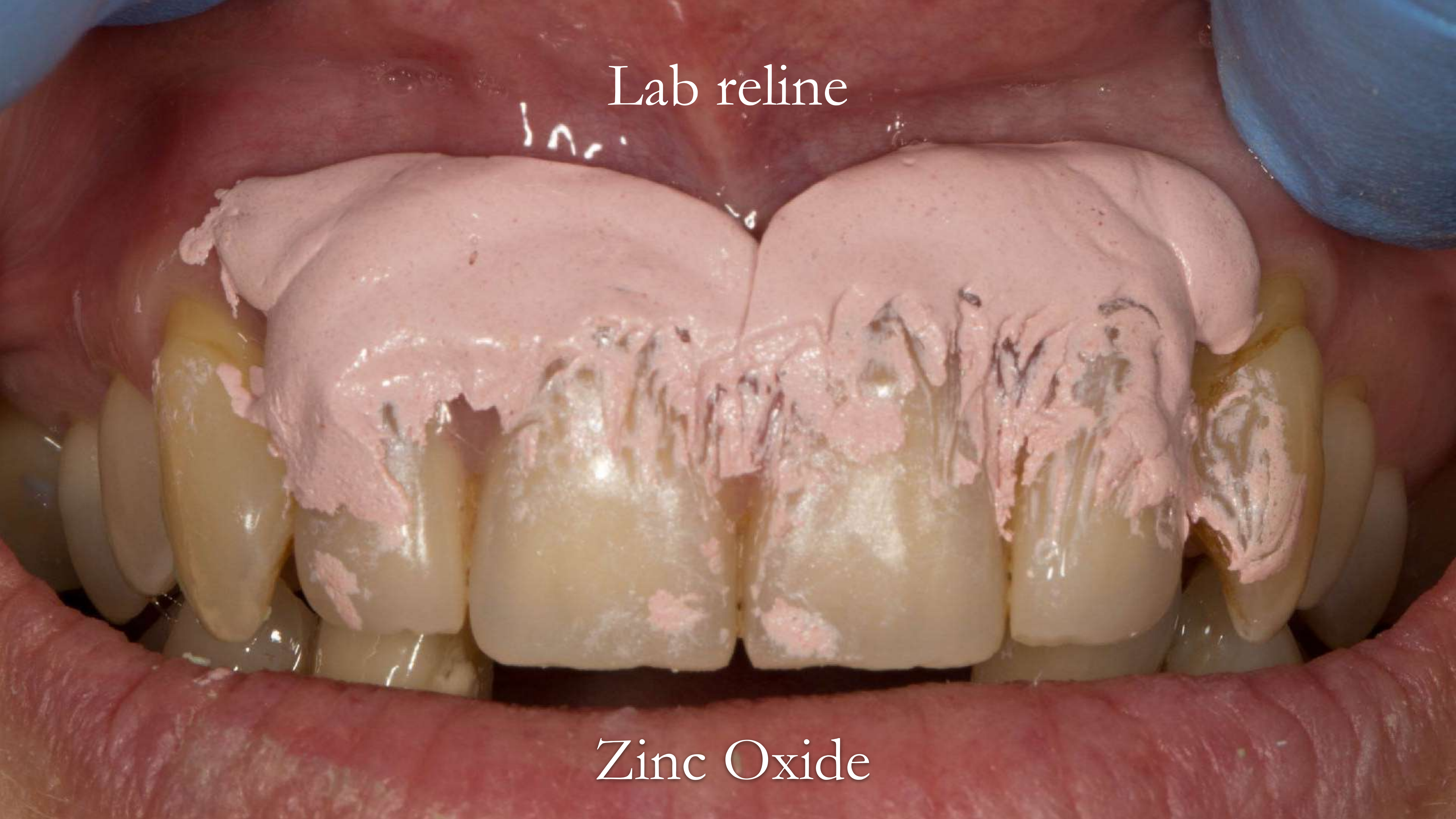


1 month after extractions

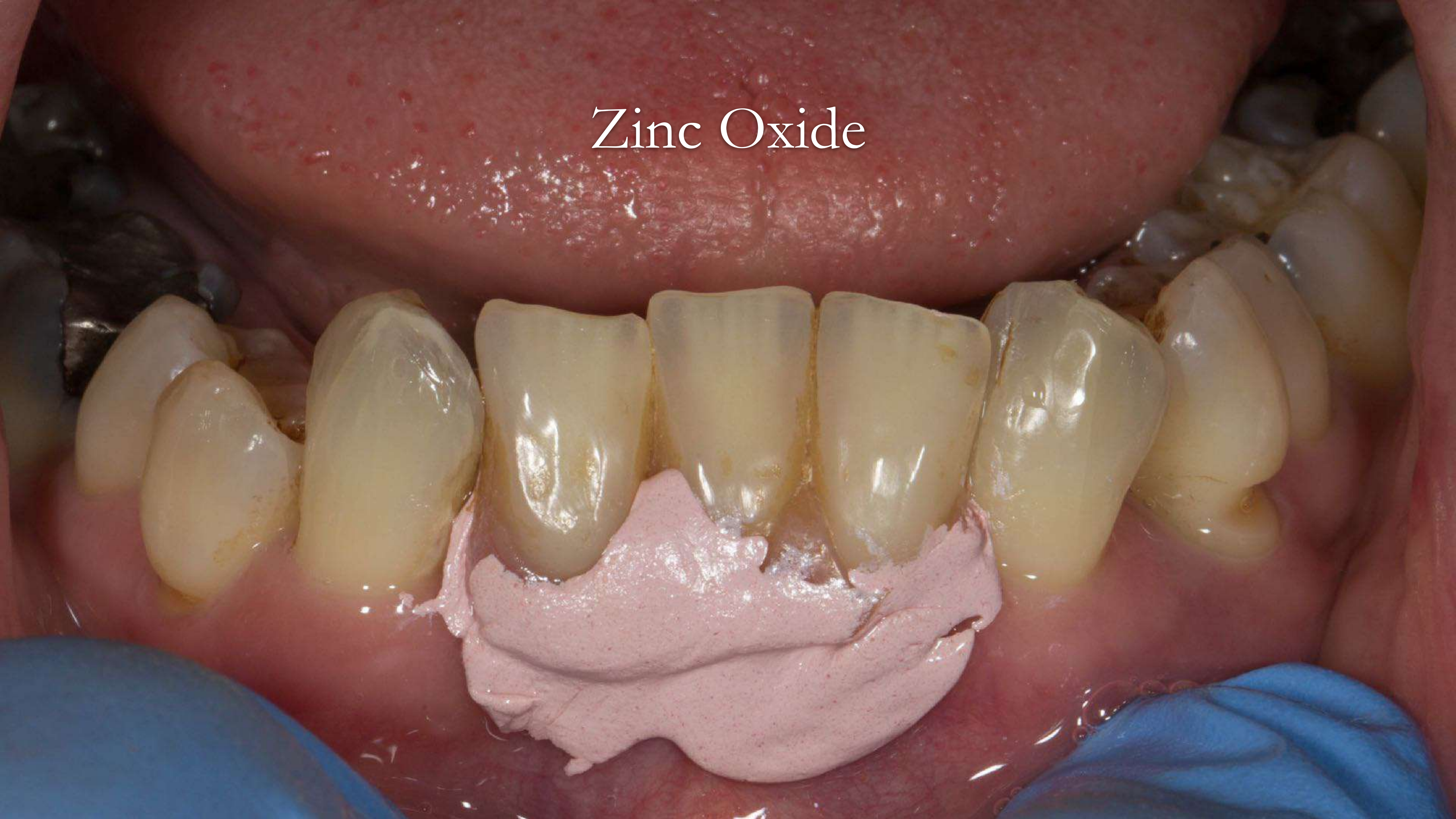

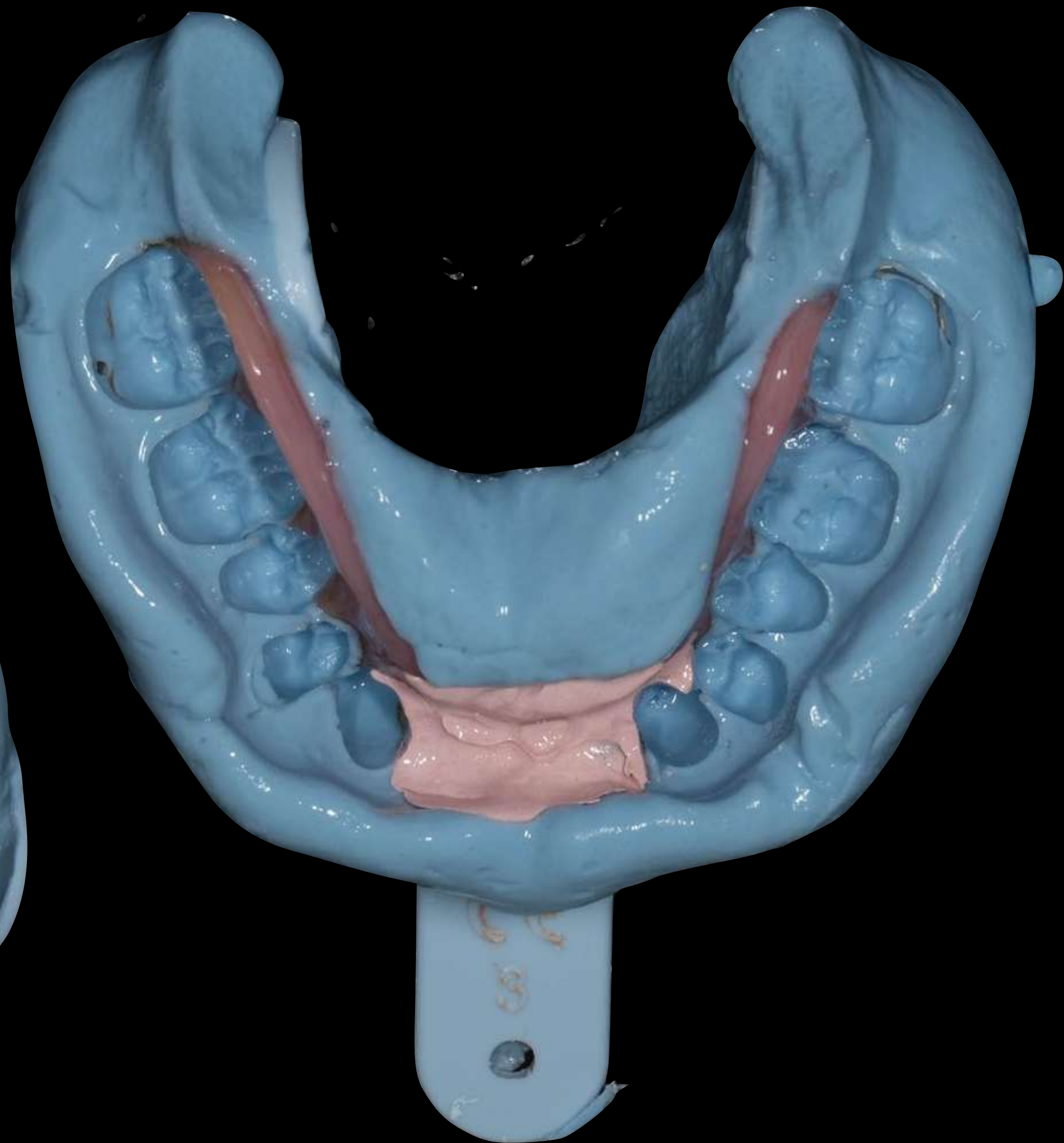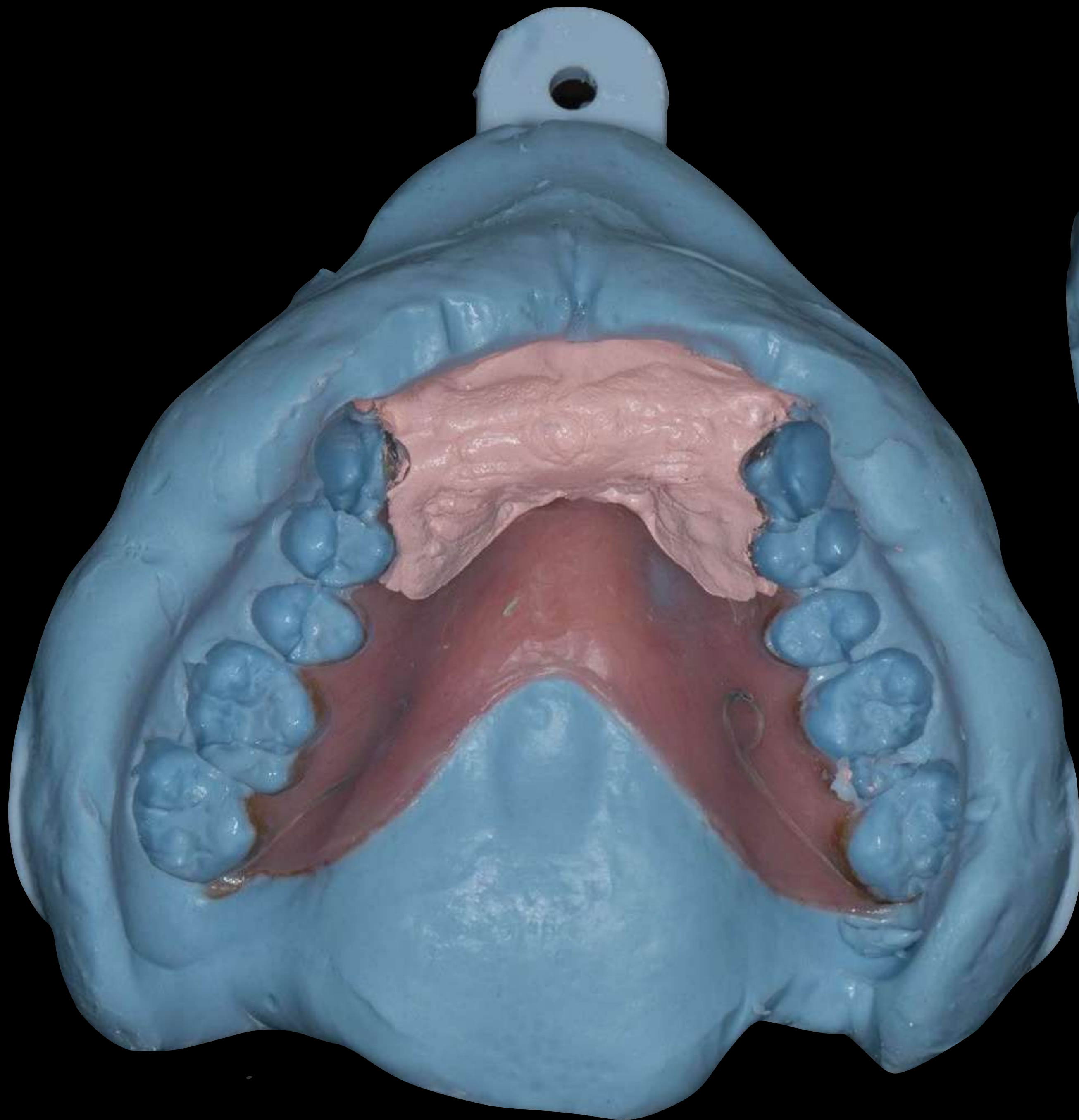
Lab reline



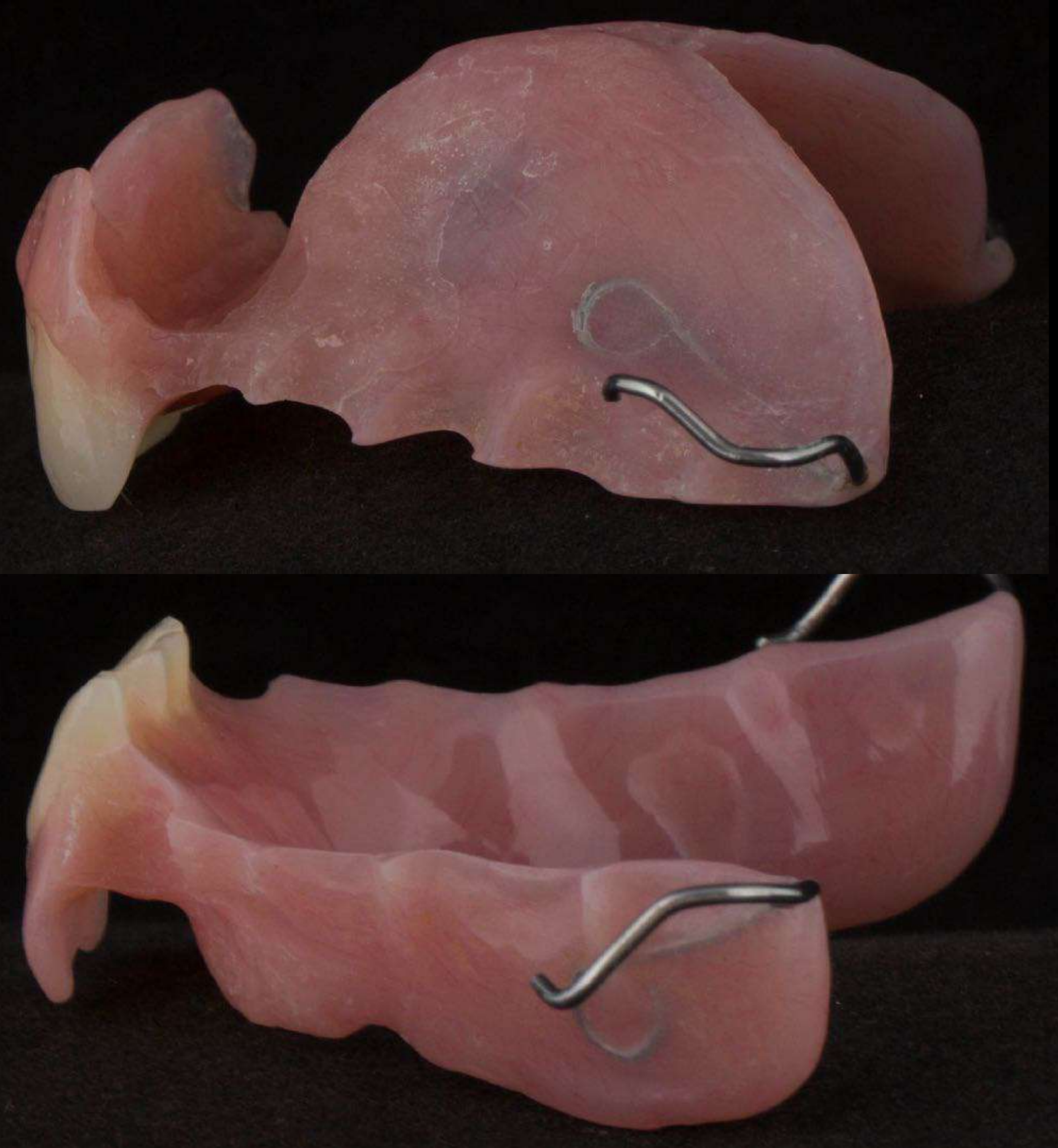
Zinc Oxide

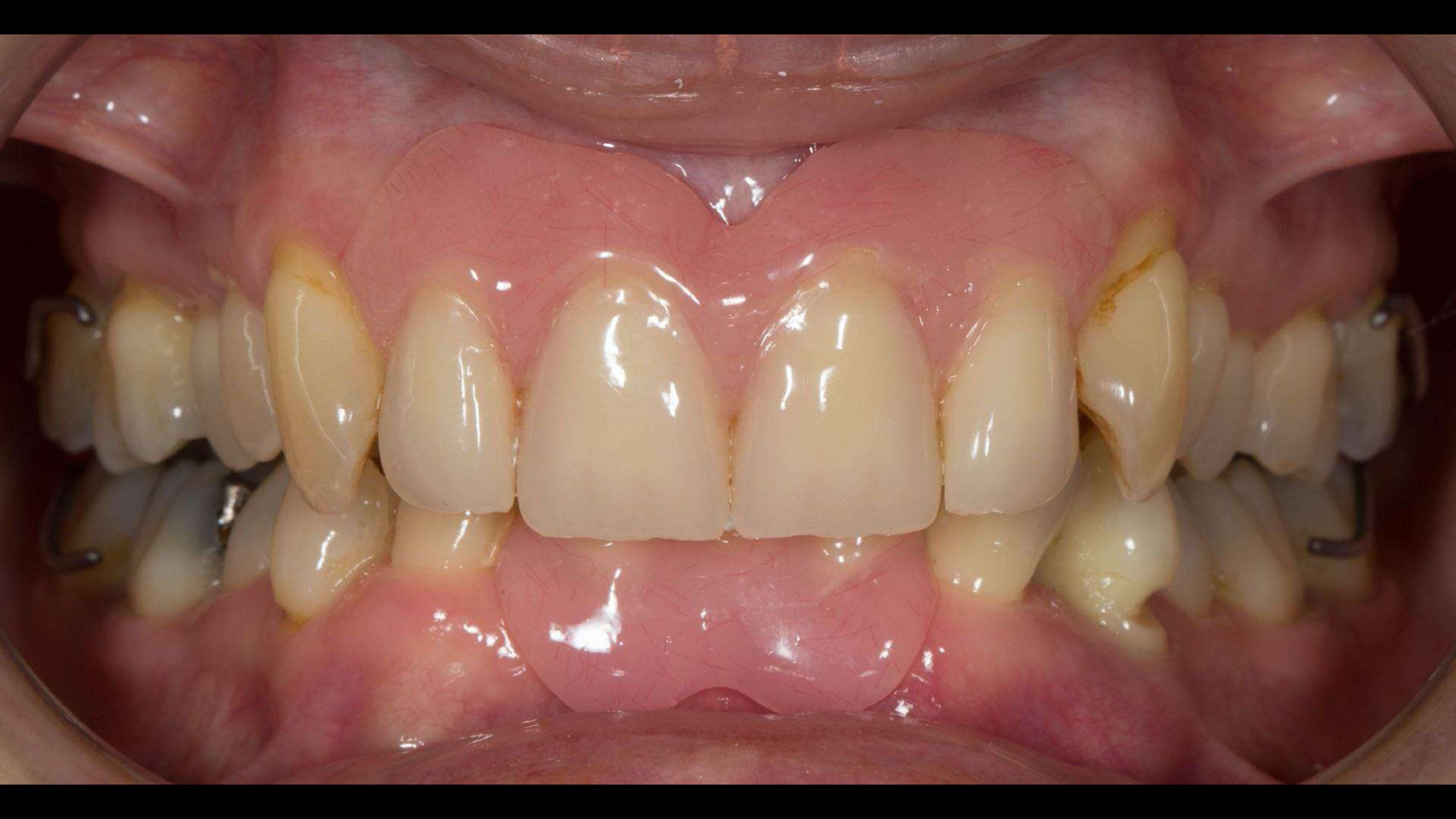Zinc Oxide



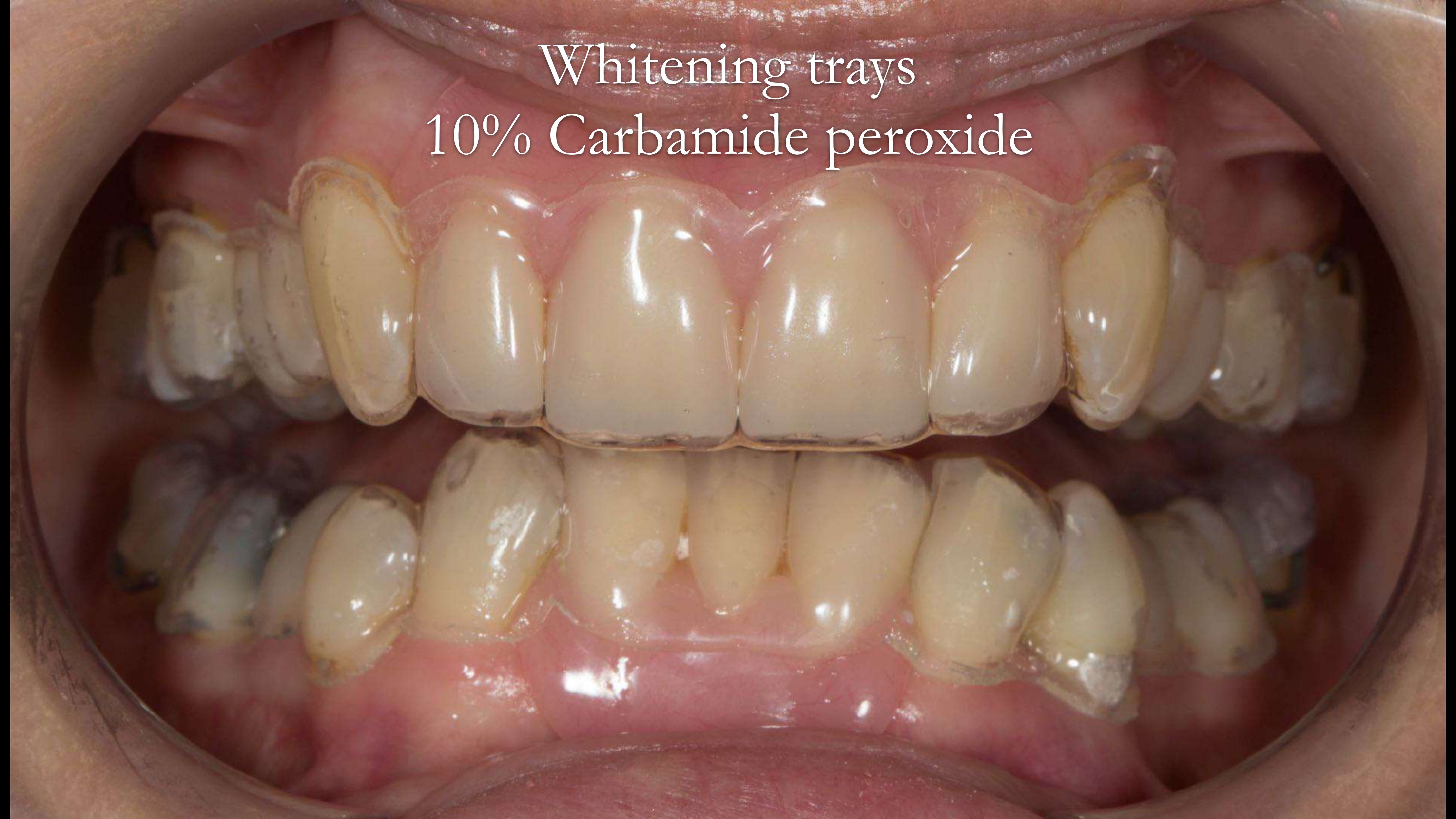


Lab reline

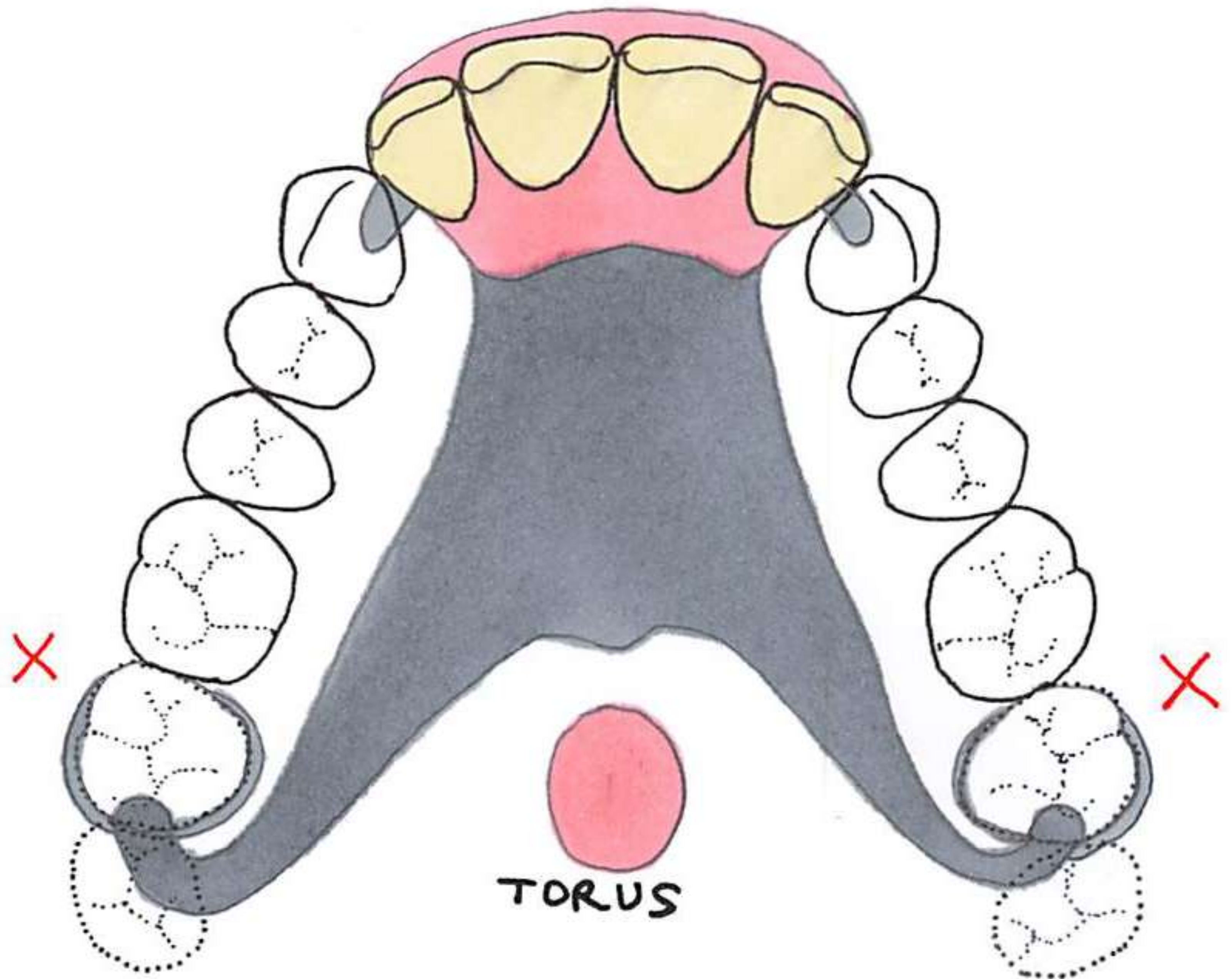




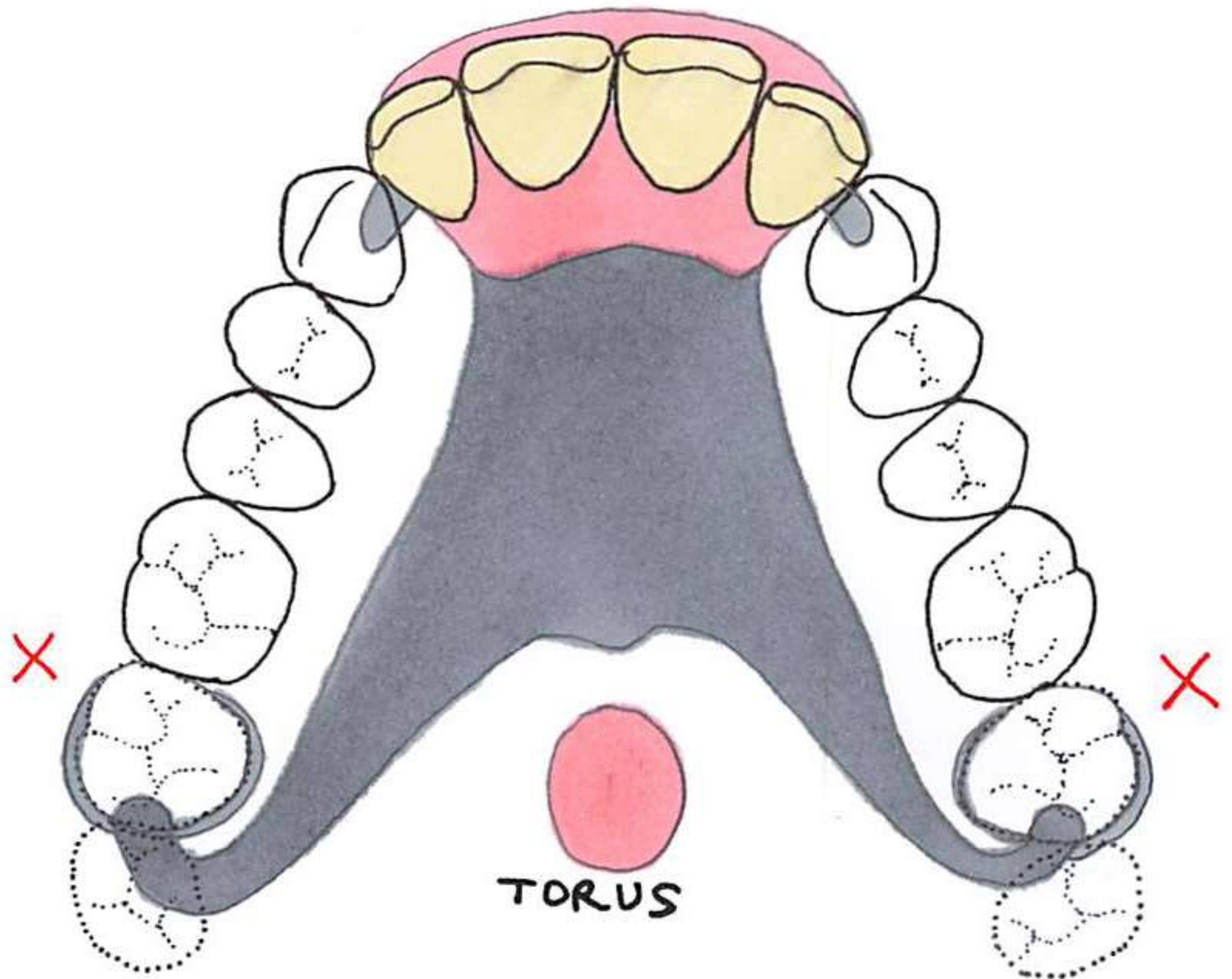
Whitening trays
10% Carbamide peroxide



Upper Mk 2 design



Promarkers



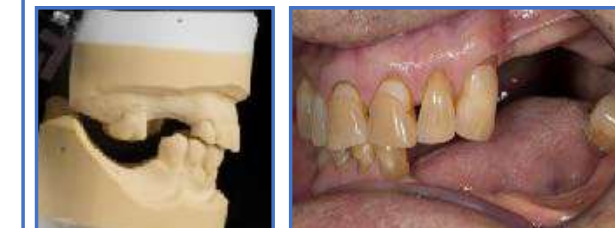RPD design sequence

finlaysutton.co.uk/resources

Removable cobalt chromium based Partial Denture design sequence by Finlay Sutton with Rowan Garstang
(Analogous to “removable” resin bonded bridges)

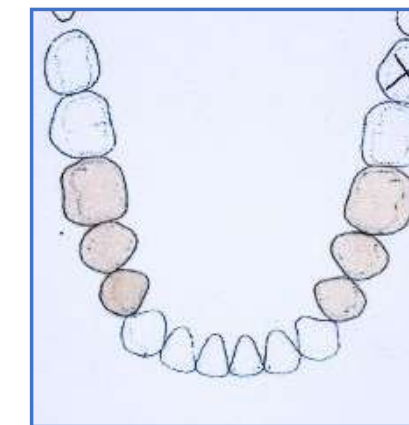1. Intra oral/extra oral photographs and mounted study casts are used to assess:

- a. Occlusal space for artificial teeth and denture components
- b. Need to increase occluding vertical dimension
- c. Visibility and hiding of metal components
- d. Anterior saddles and path of insertion
- e. Need for restorations indirect restorations onlays, crowns etc..



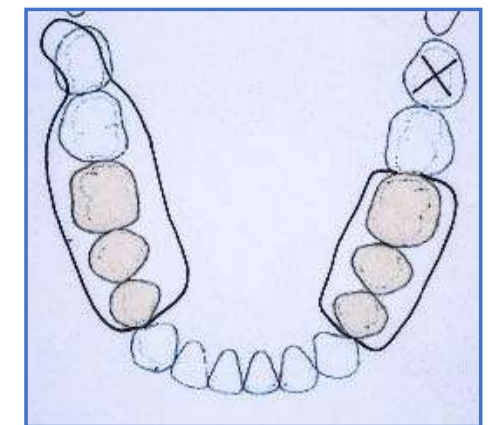
2. Teeth to be replaced

- a. Opposing occluding contacts
- b. Interocclusal space posteriorly - is there space for a prosthetic tooth or a need for metal occluding surfaces?



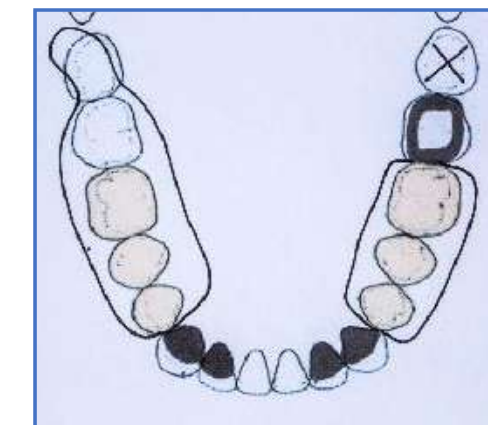
3. Flange outline - drawn

- a. Avoid gingival margins
- b. Optimum extension of free-end saddles to maximise support

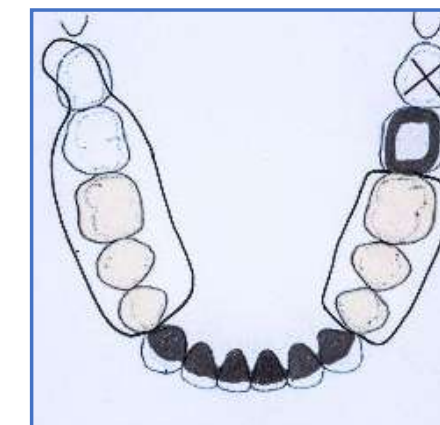


4. Maximise rest tooth support
Examine occlusal space

- a. Additive - in composite
- b. Subtractive - cut into teeth
- c. Need for splinting to mobile teeth

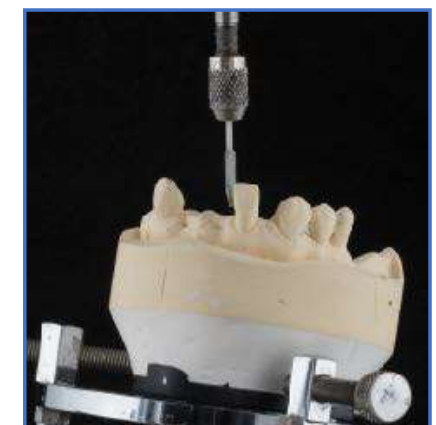

5. Planning for future extractions/
additions/modification

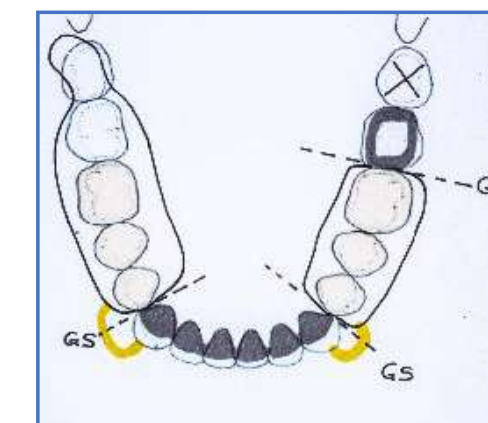


6. Guide surfaces (GS) - using surveyor

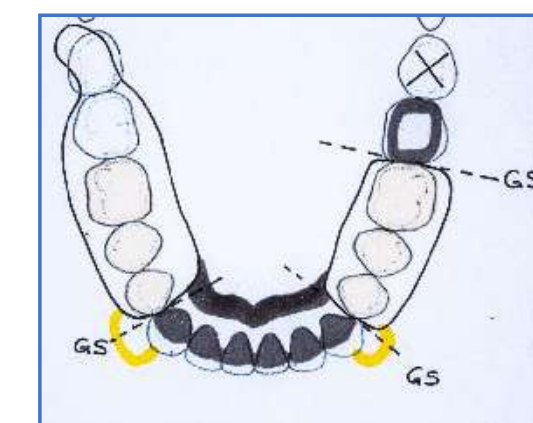
- a. Close gaps - reducing black triangles anteriorly
- b. Path of insertion/withdrawal different to path of displacement with sticky food Assist with retention



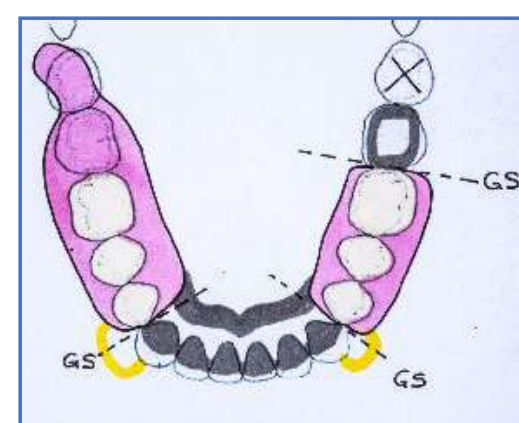
7. Retention, reciprocation and indirect -
No more than 2 clasps per denture

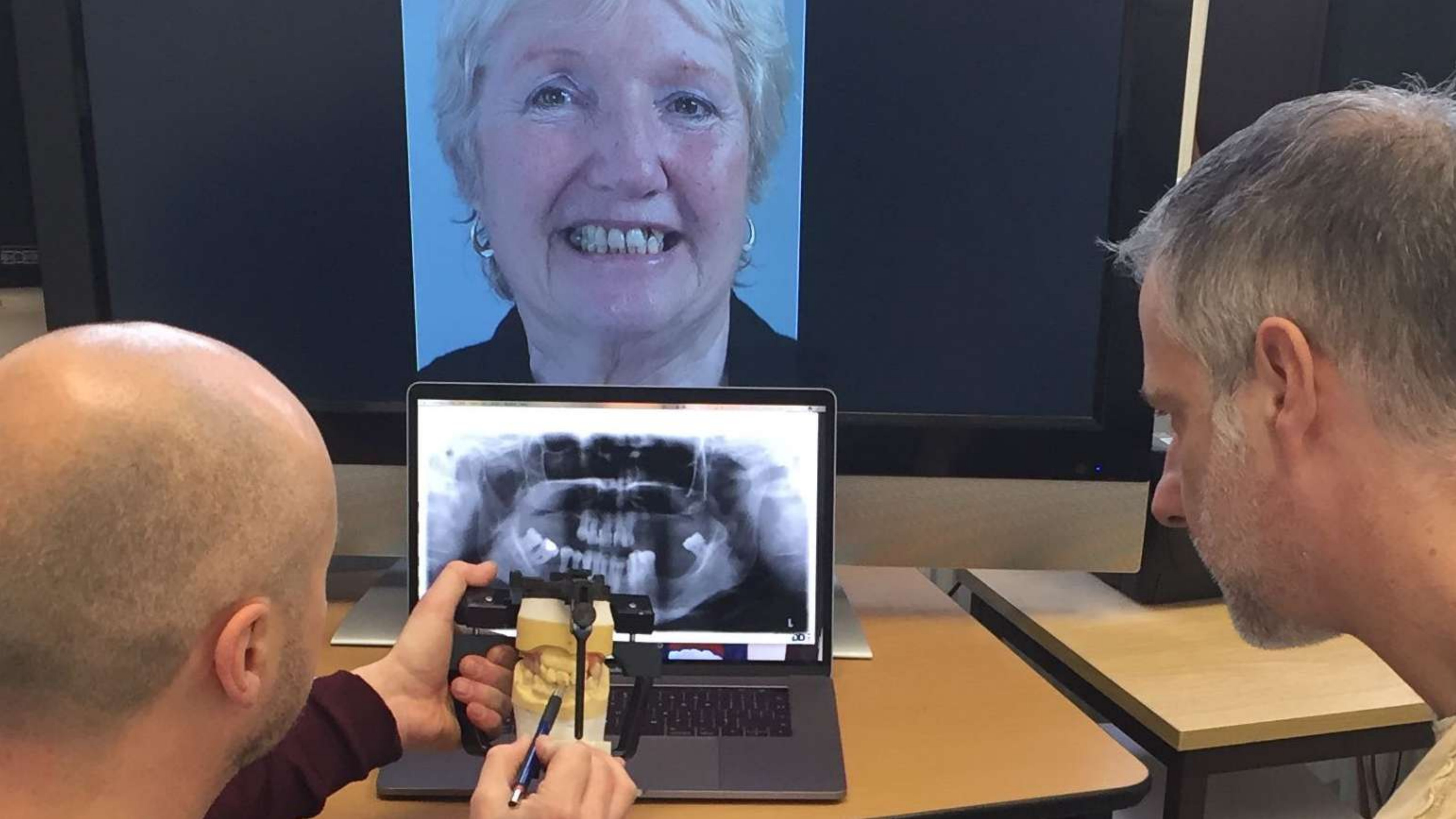


8. Major connector -rigid - chassis as possible avoid palatal coverage of anterior rugae if possible

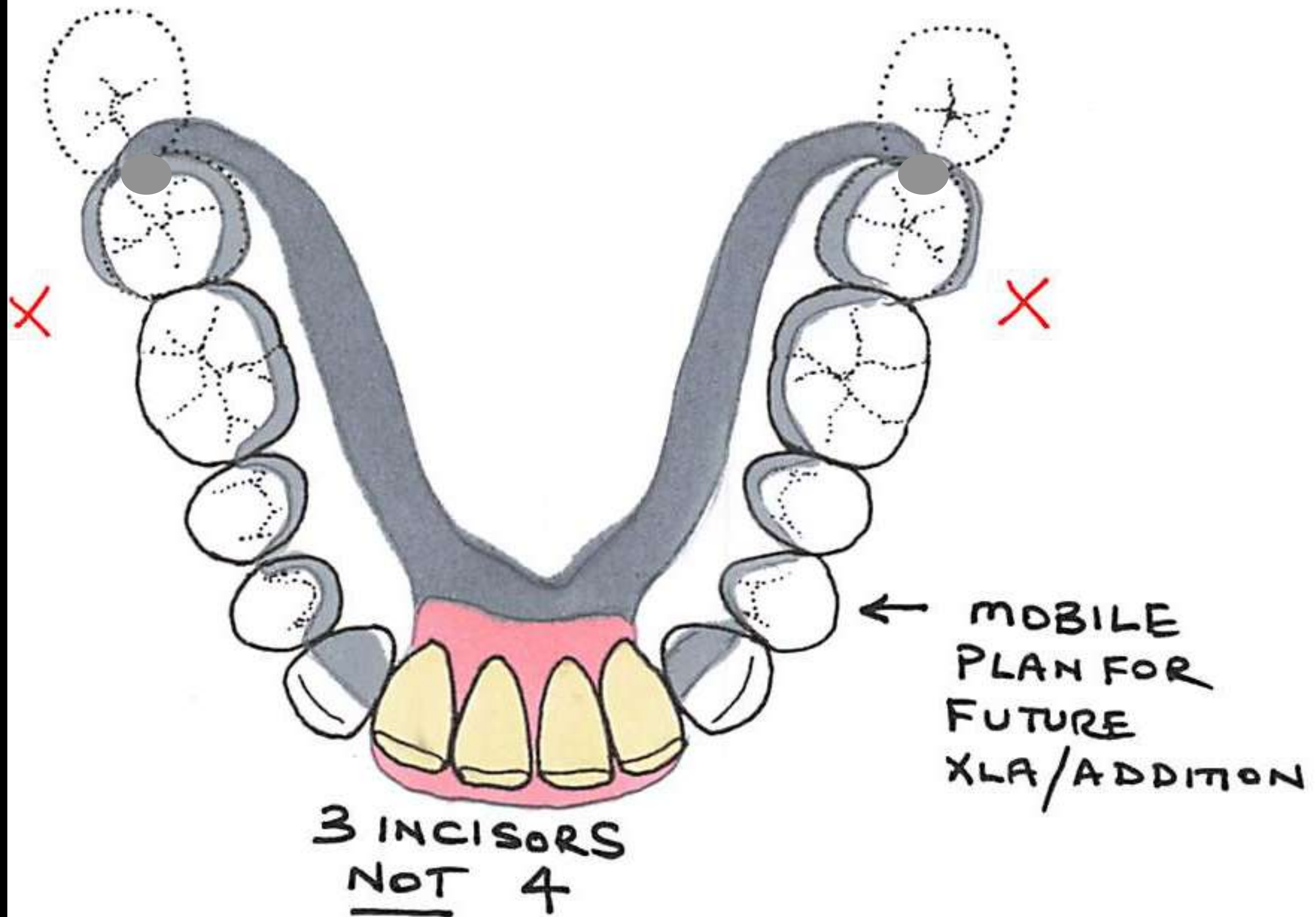


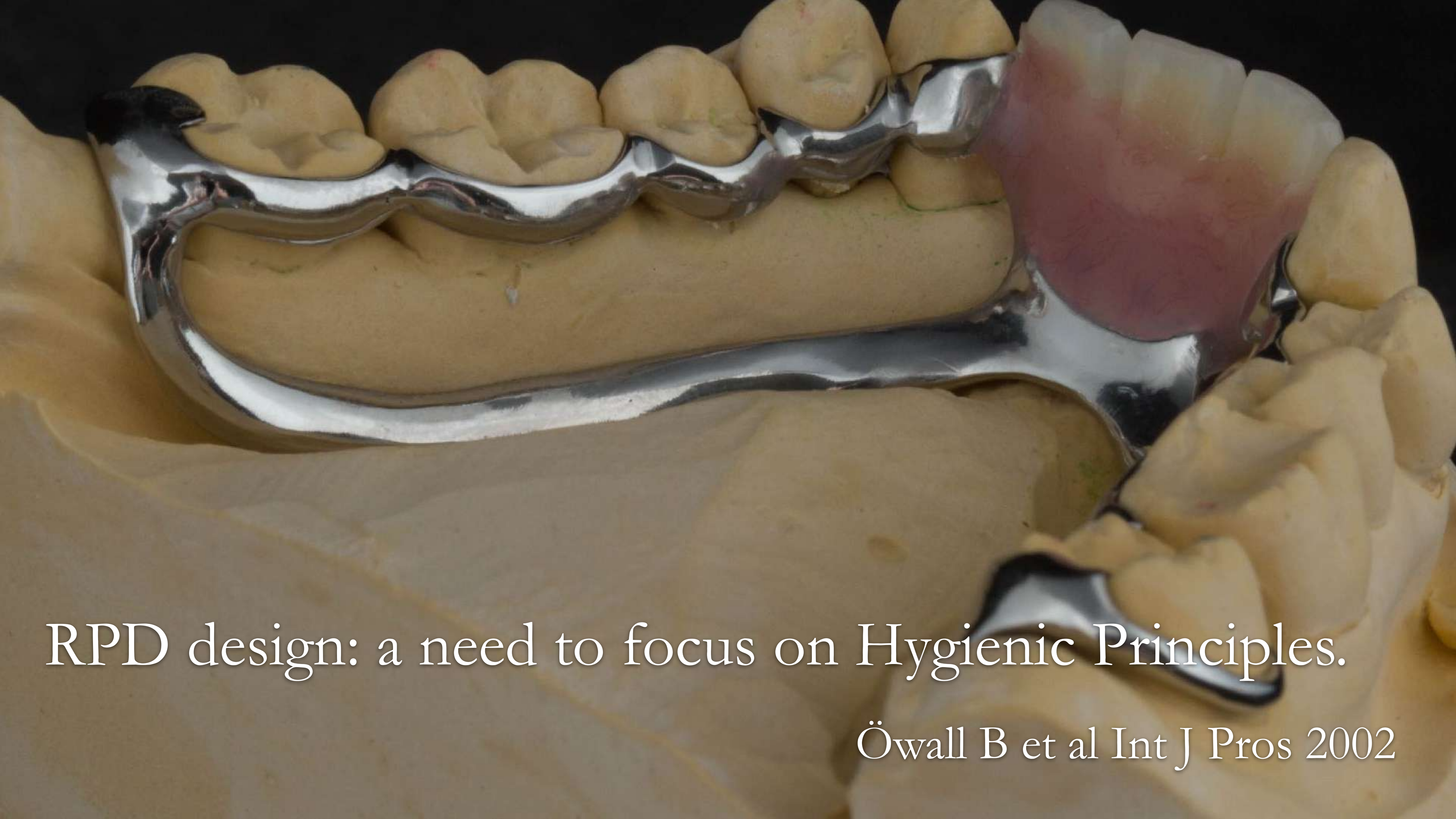9. Finalise design, discuss with patient.
Confirm the patient is aware of visible clasping and metal components





Lower Mk 2 design



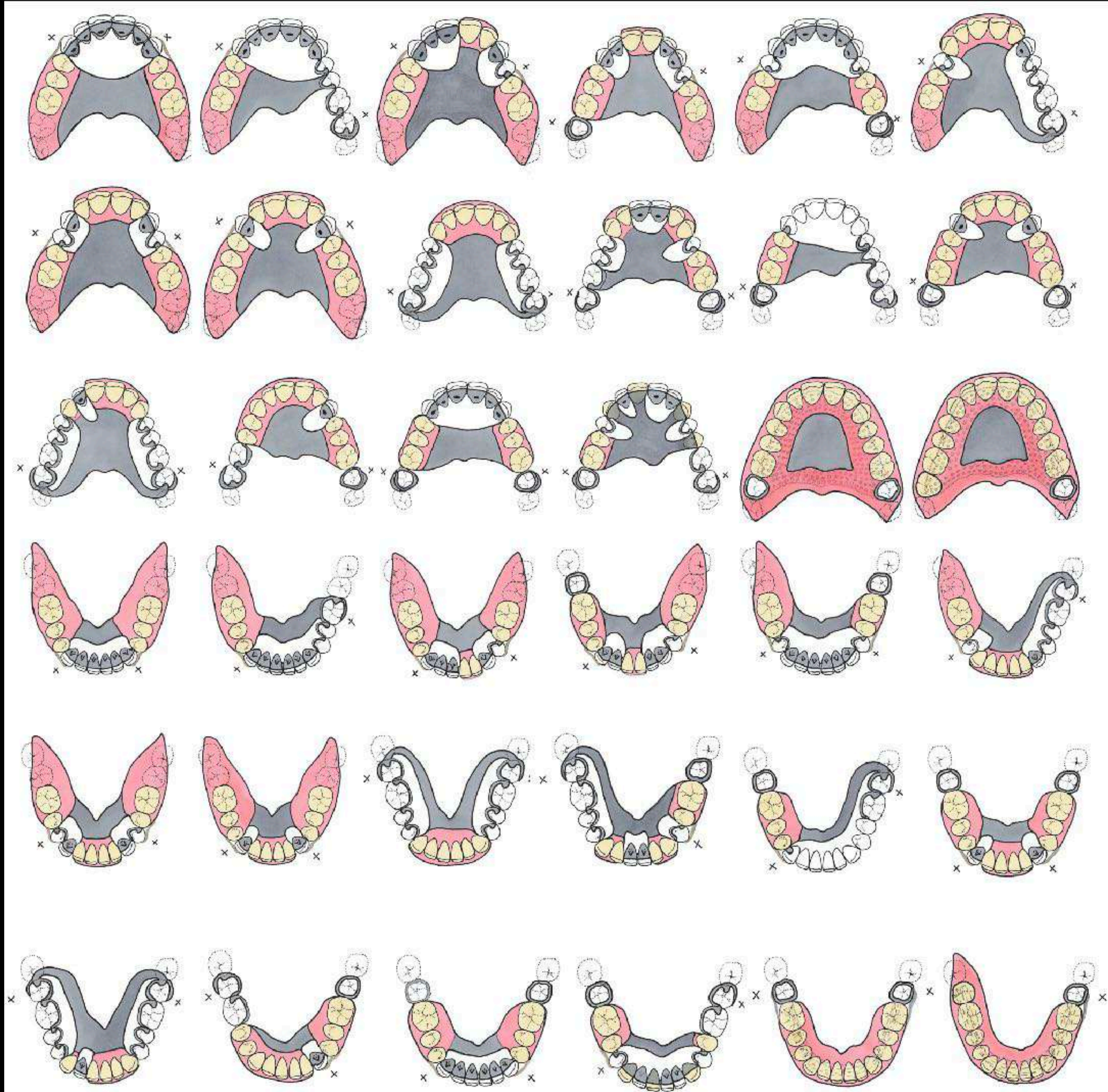


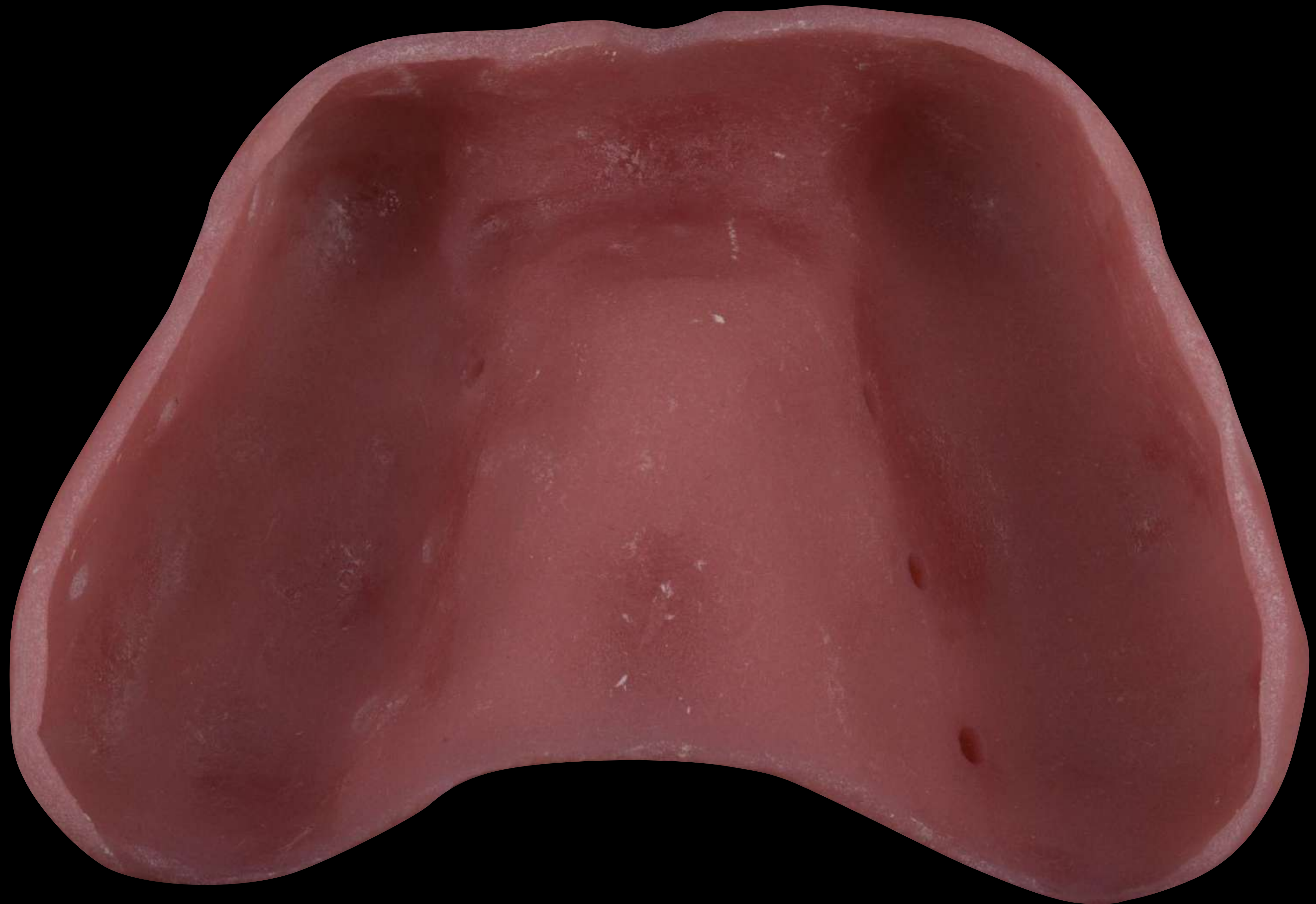
RPD design: a need to focus on Hygienic Principles.

Öwall B et al Int J Pros 2002

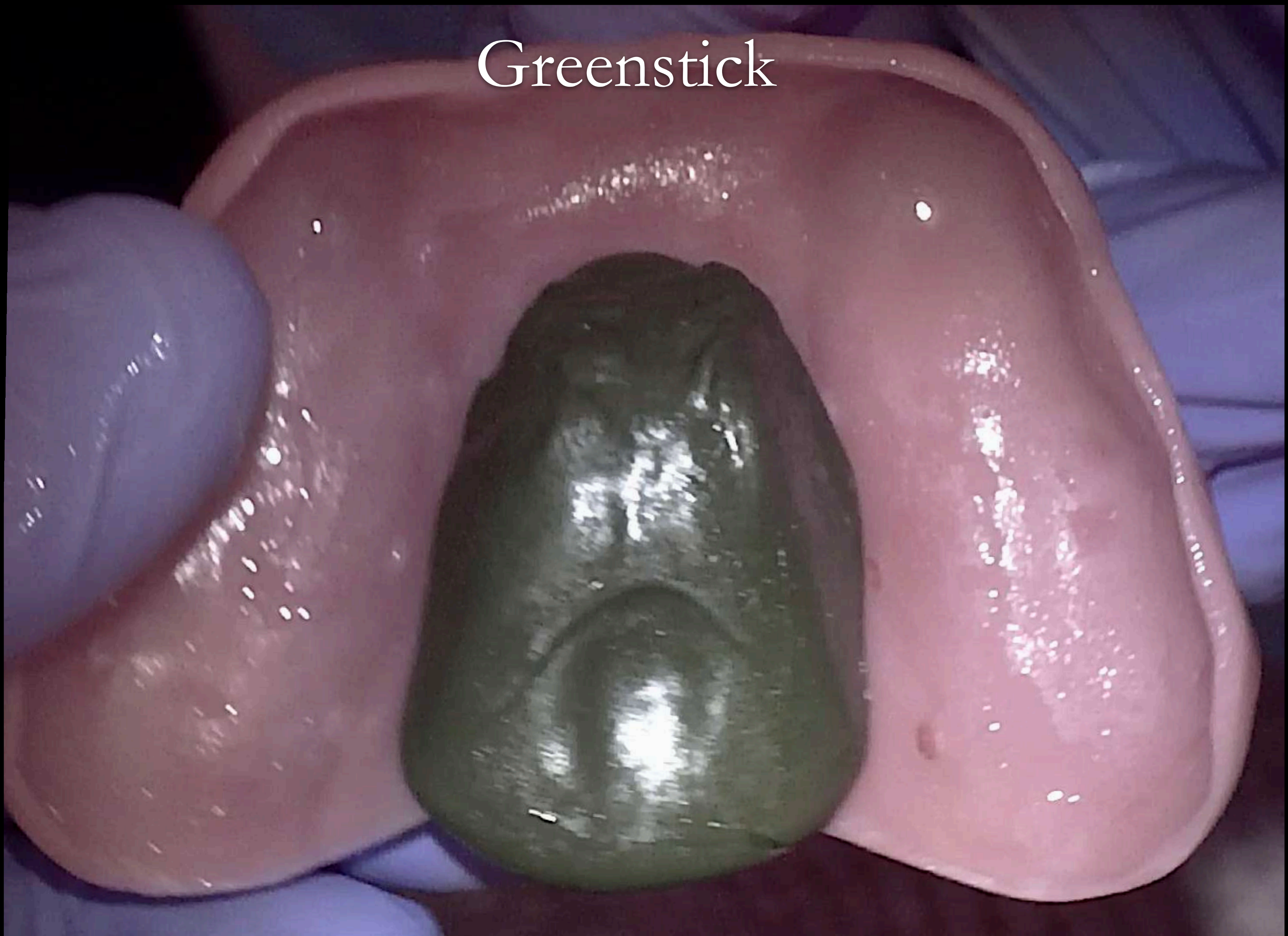RPD Designs

finlaysutton.co.uk/blog

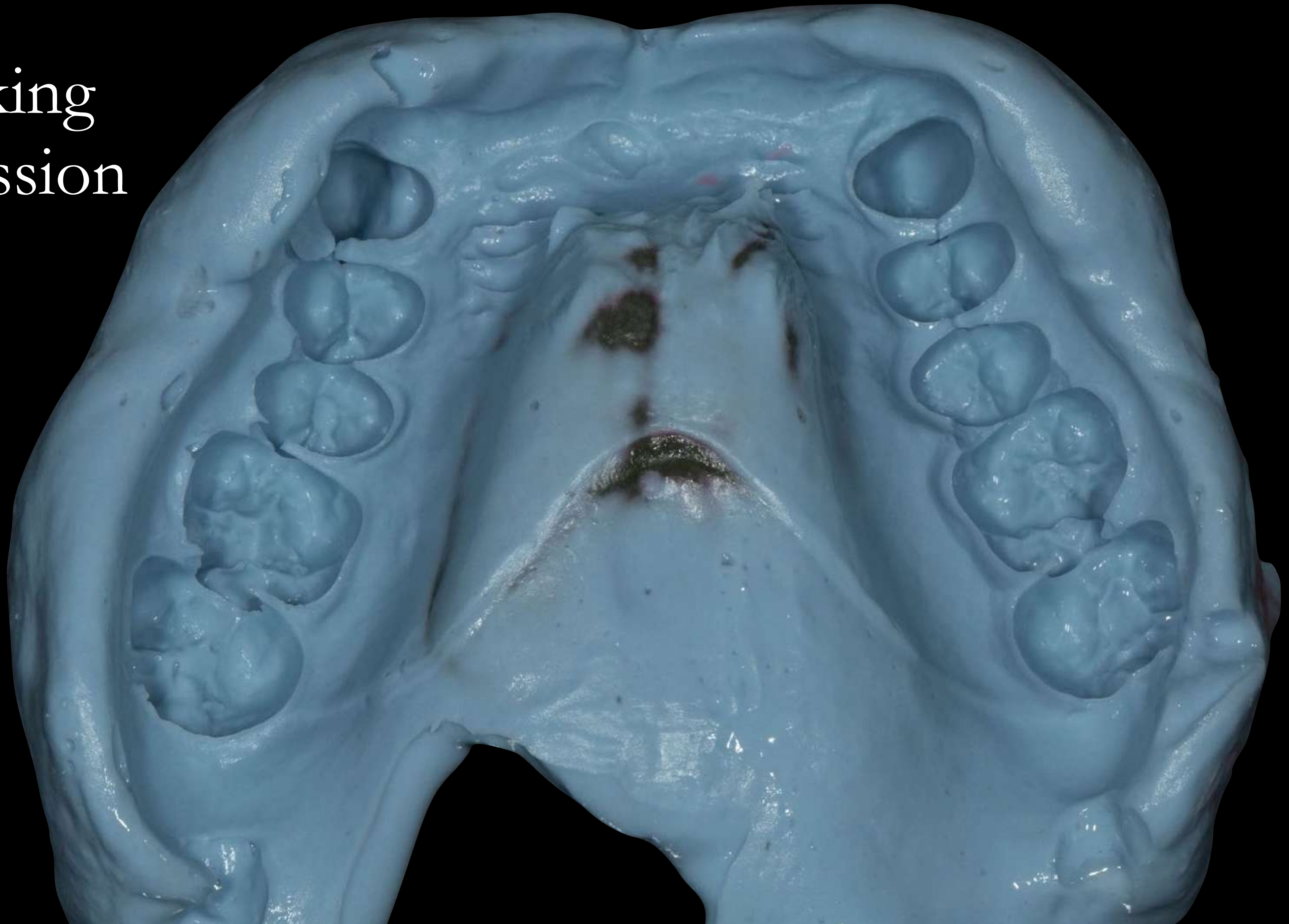


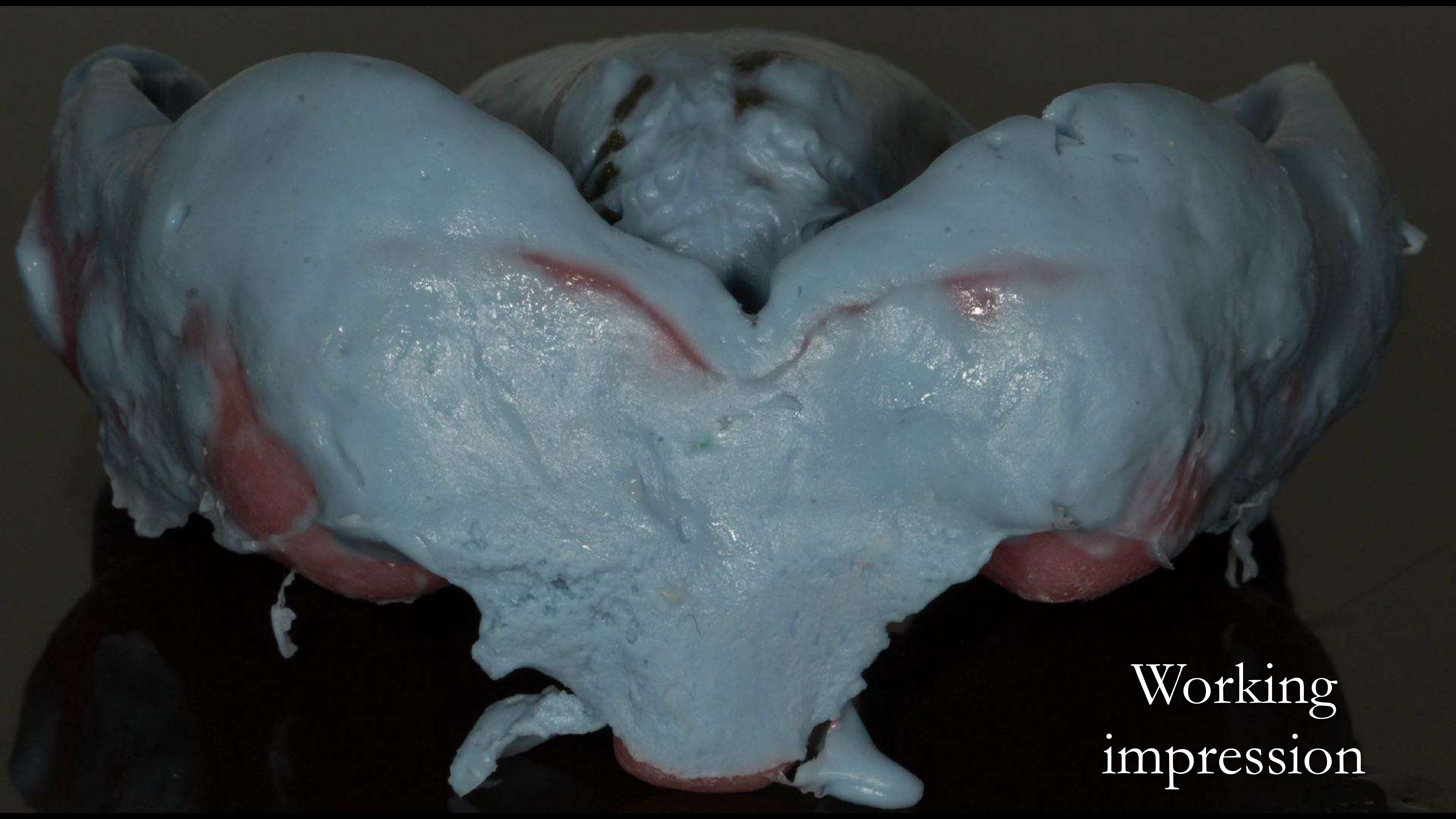

Greenstick



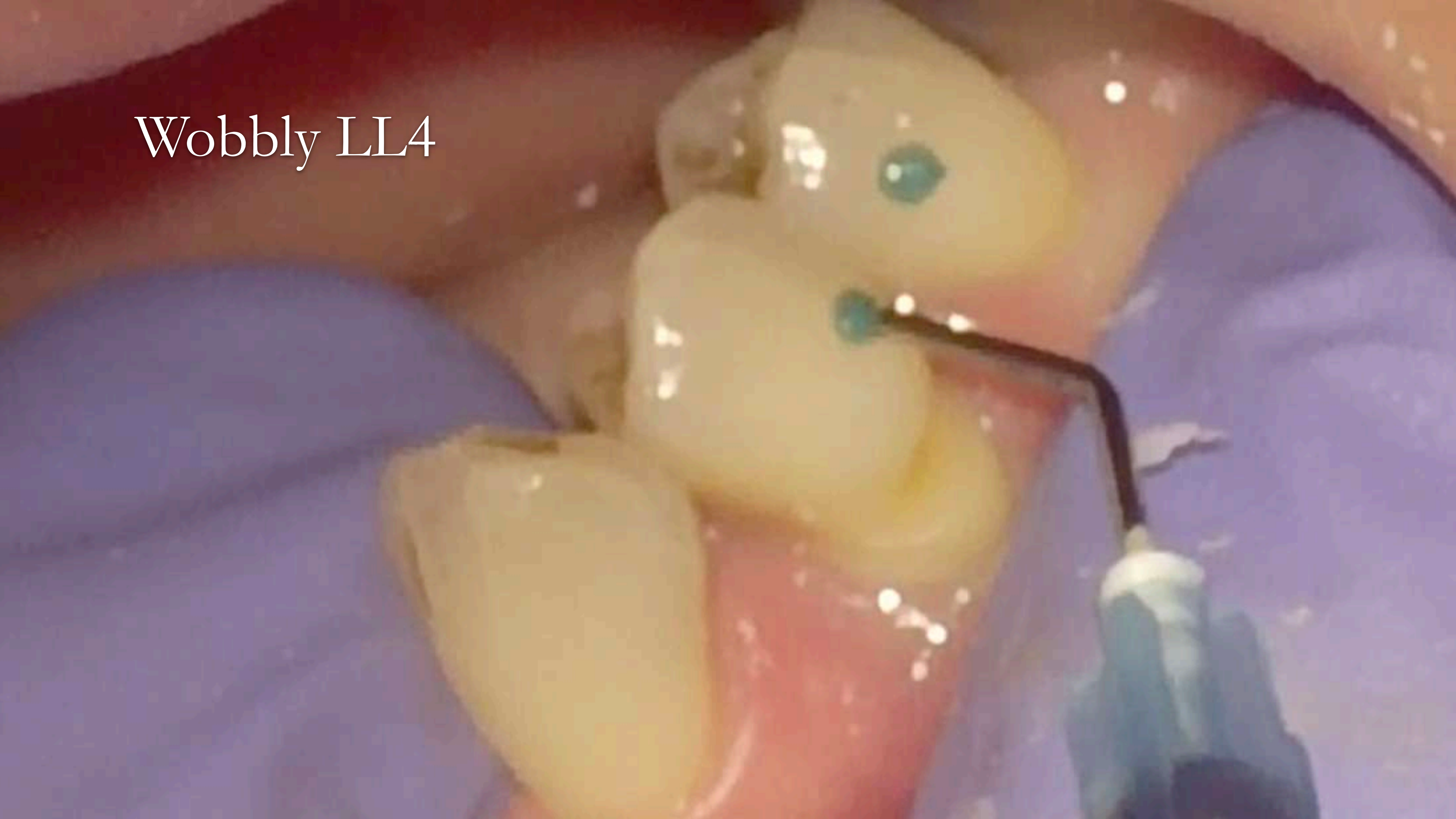Working
impression



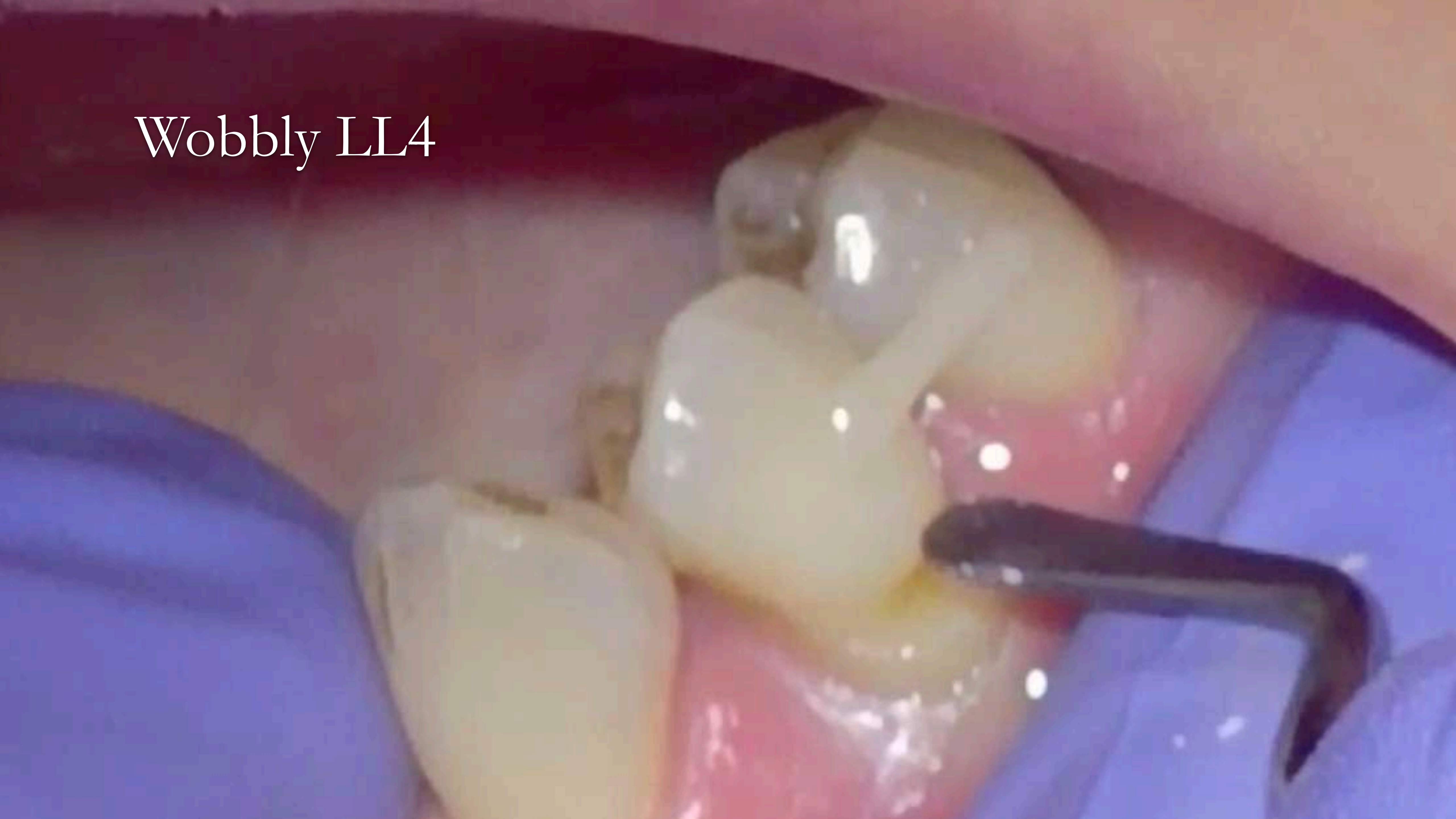

Working
impression

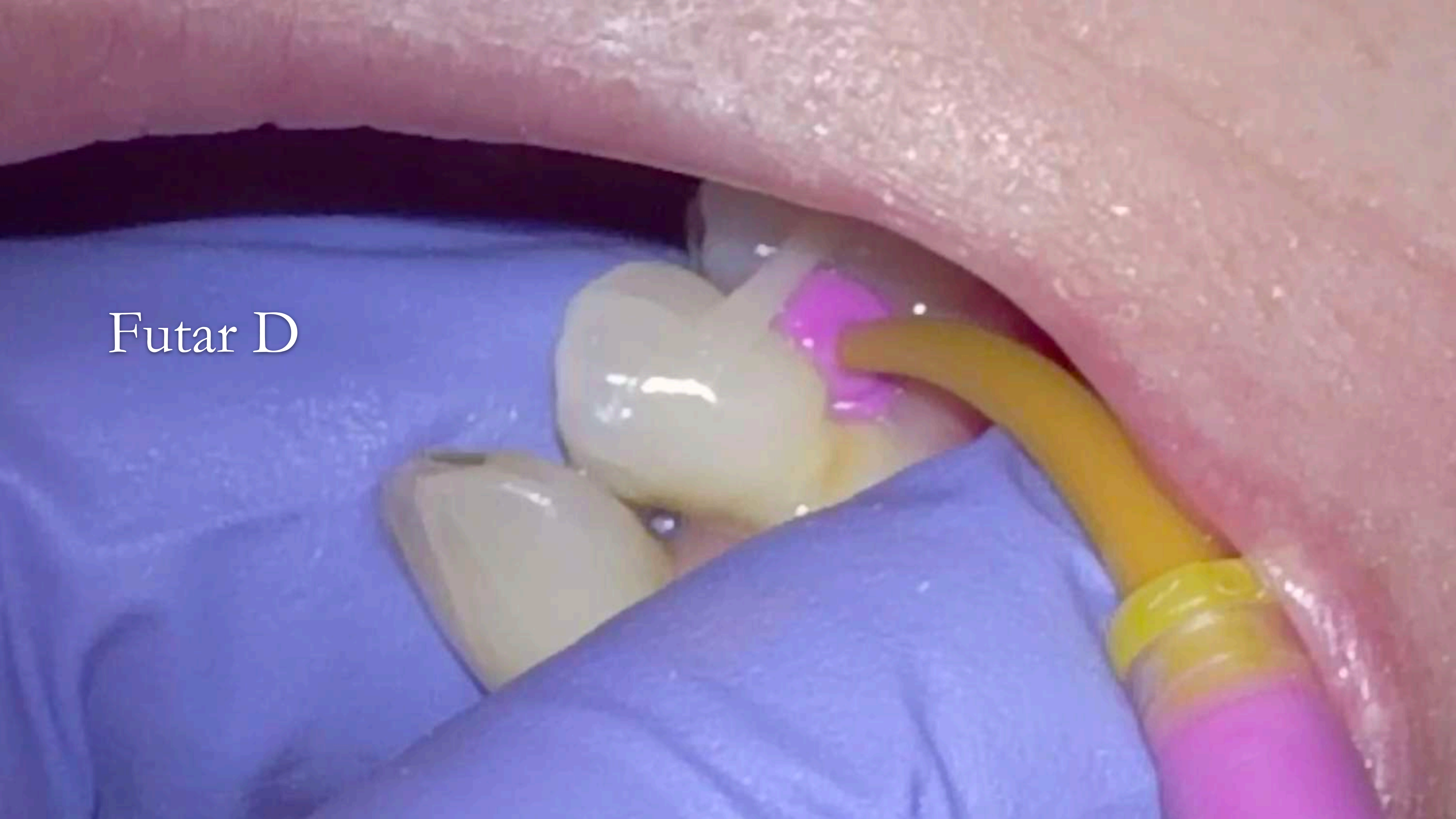
Wobbly LL4



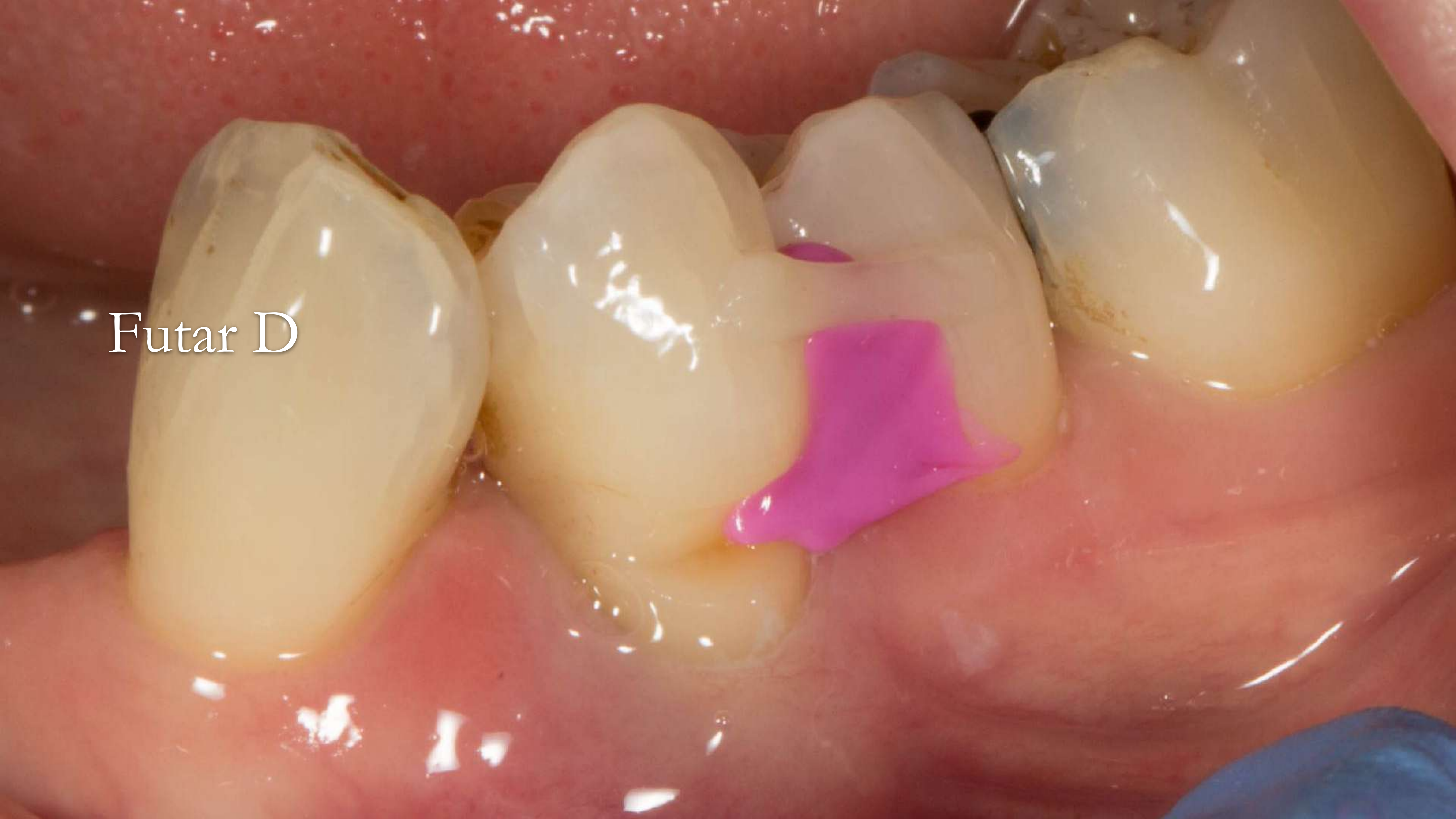Wobbly LL4



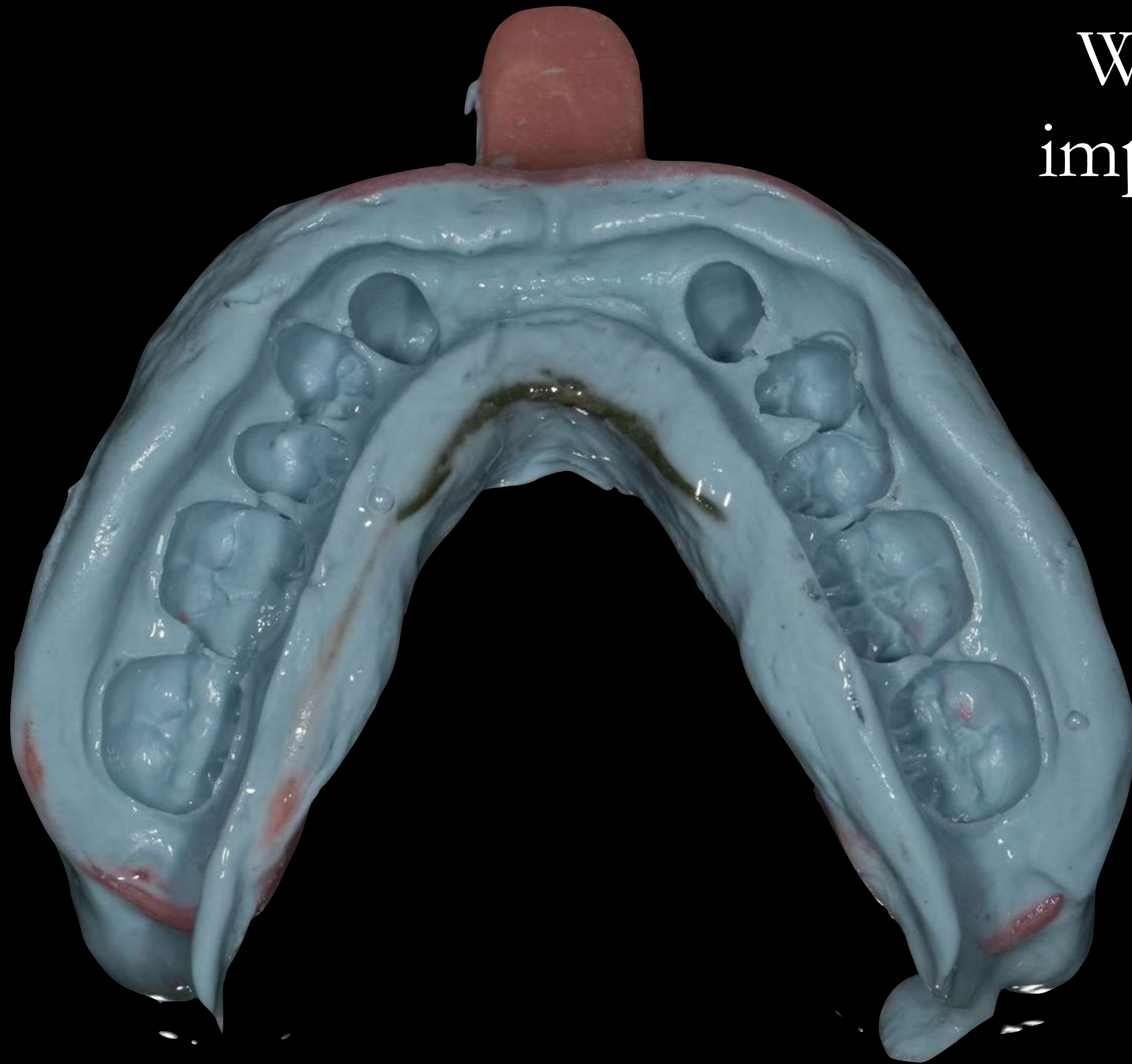
Futar D



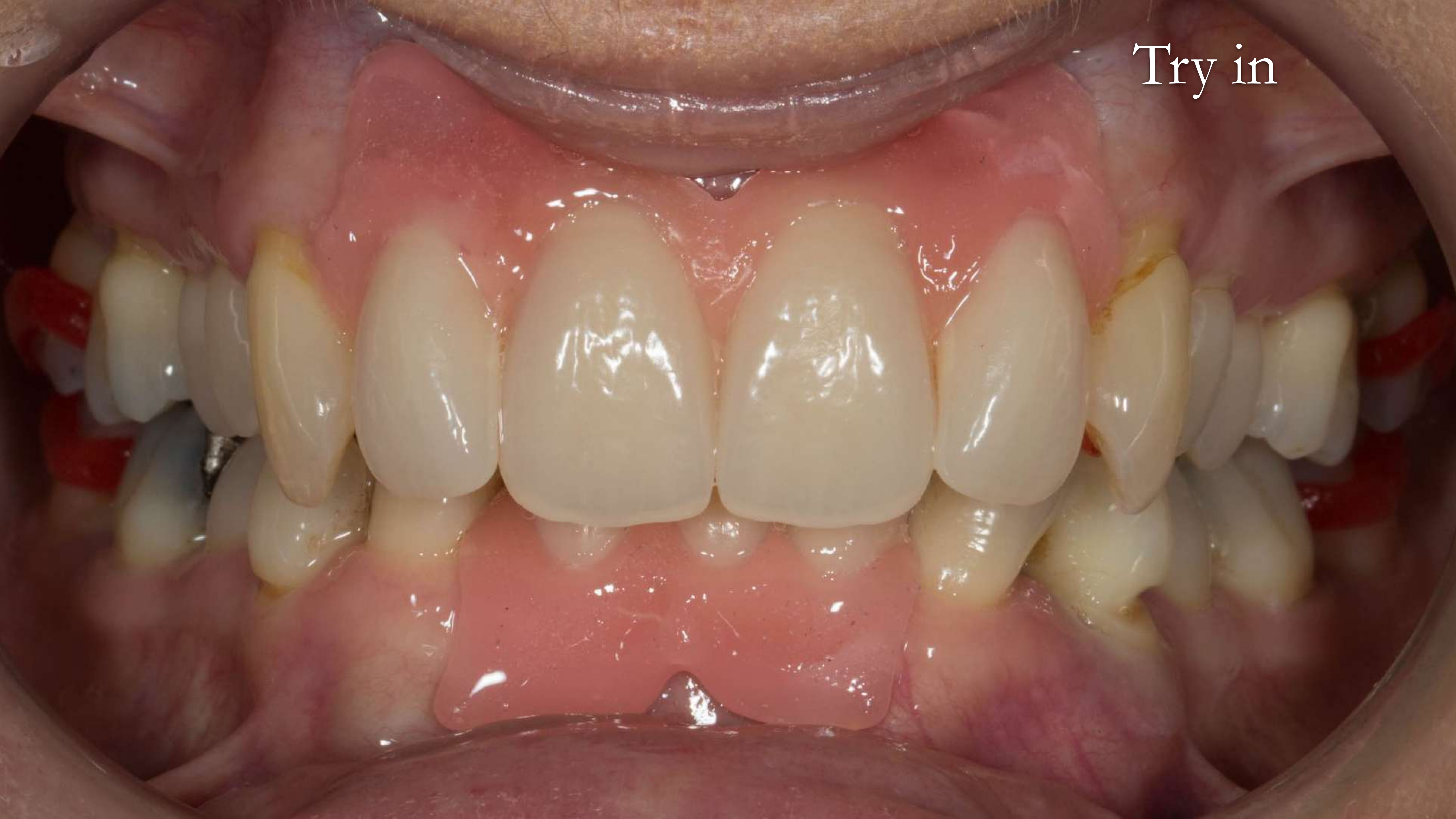Futar D

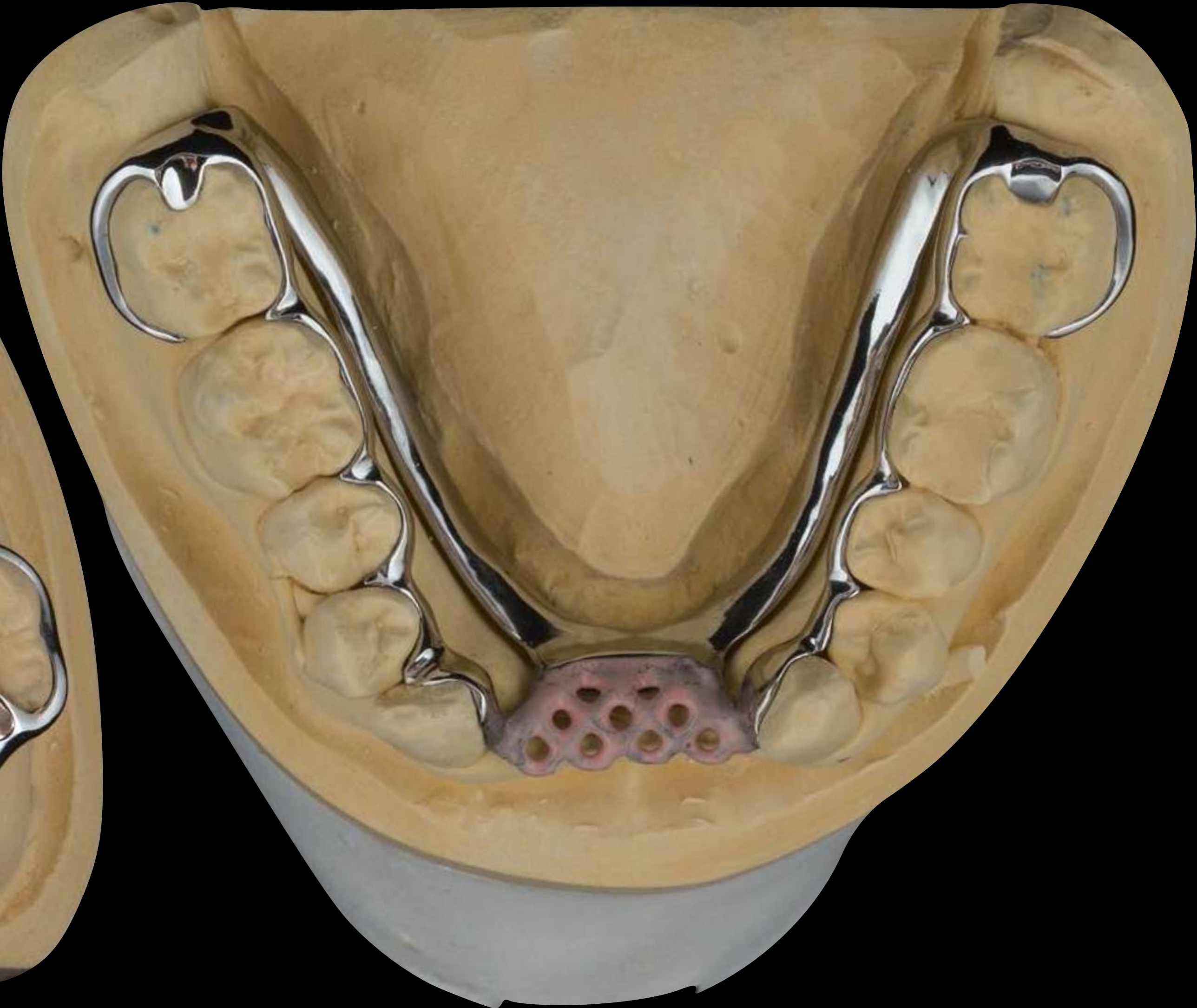
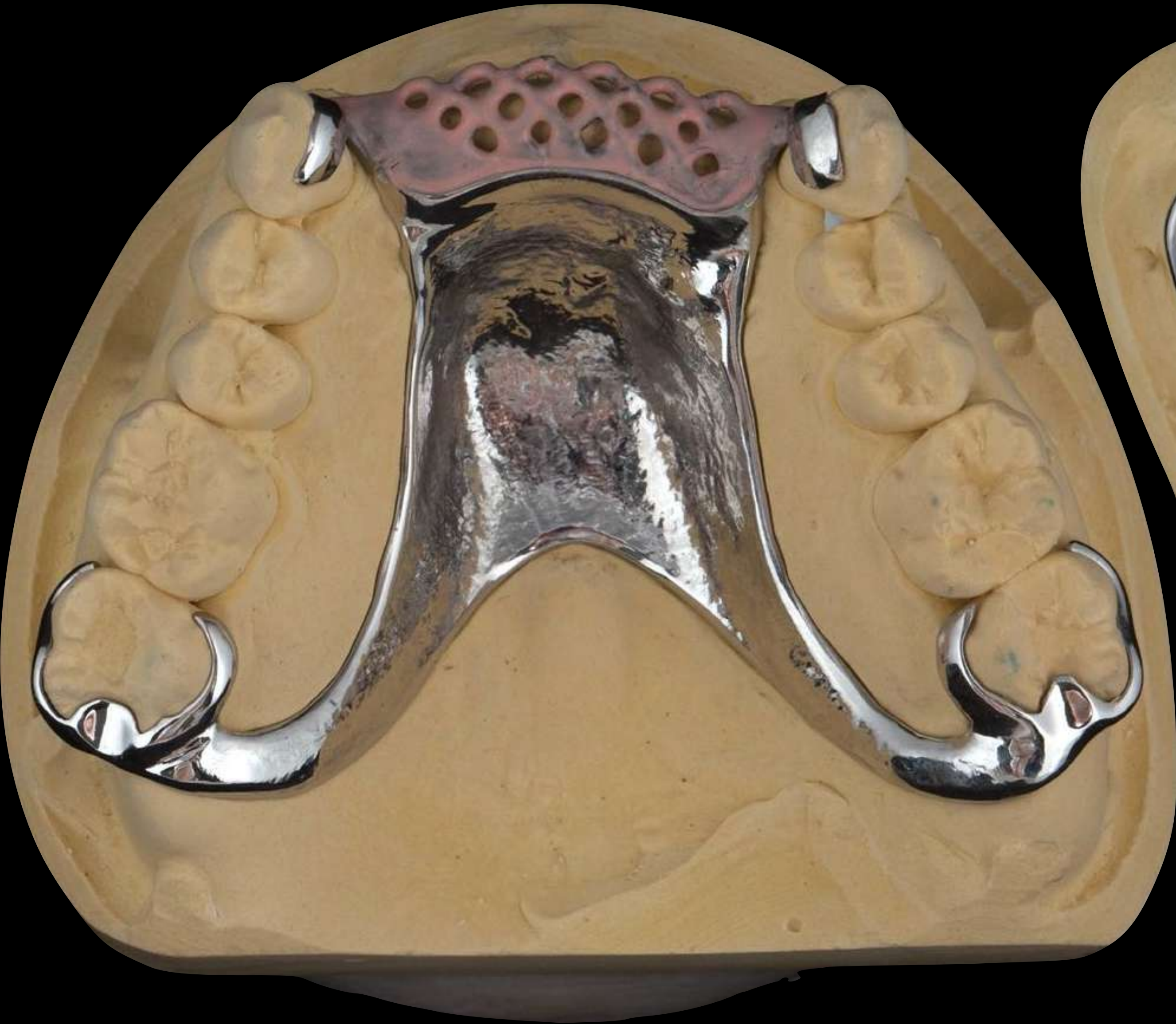


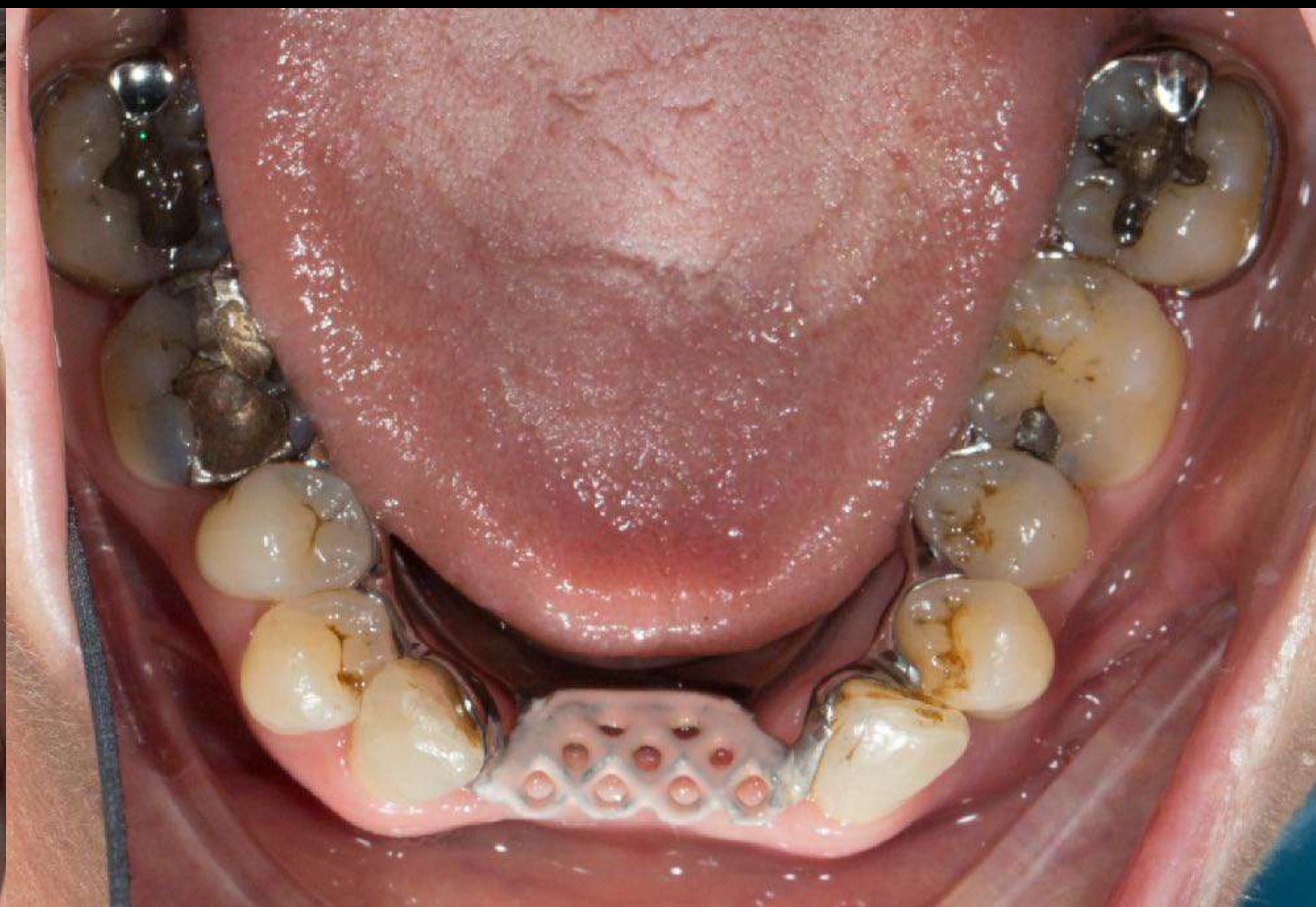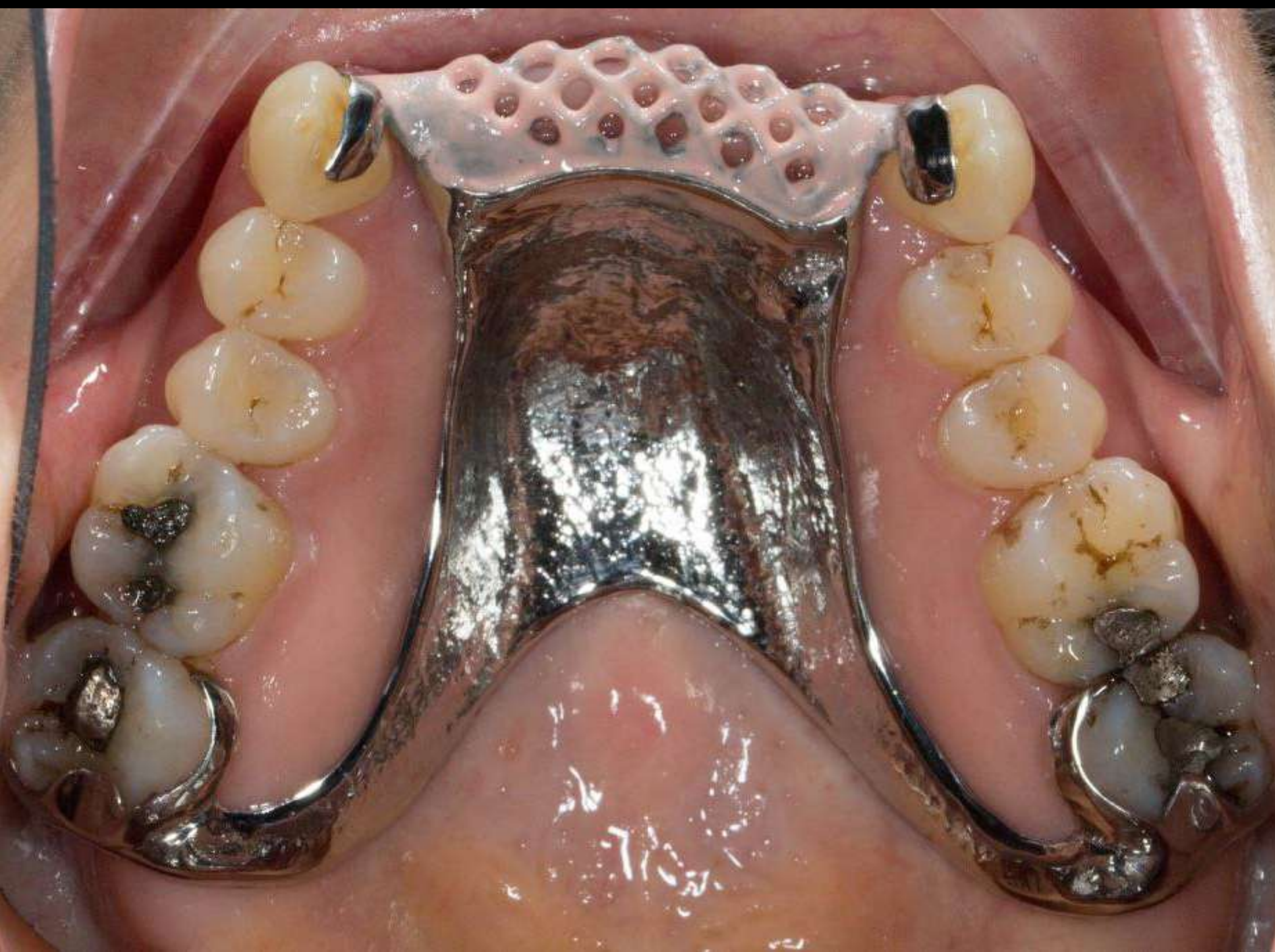Working
impression

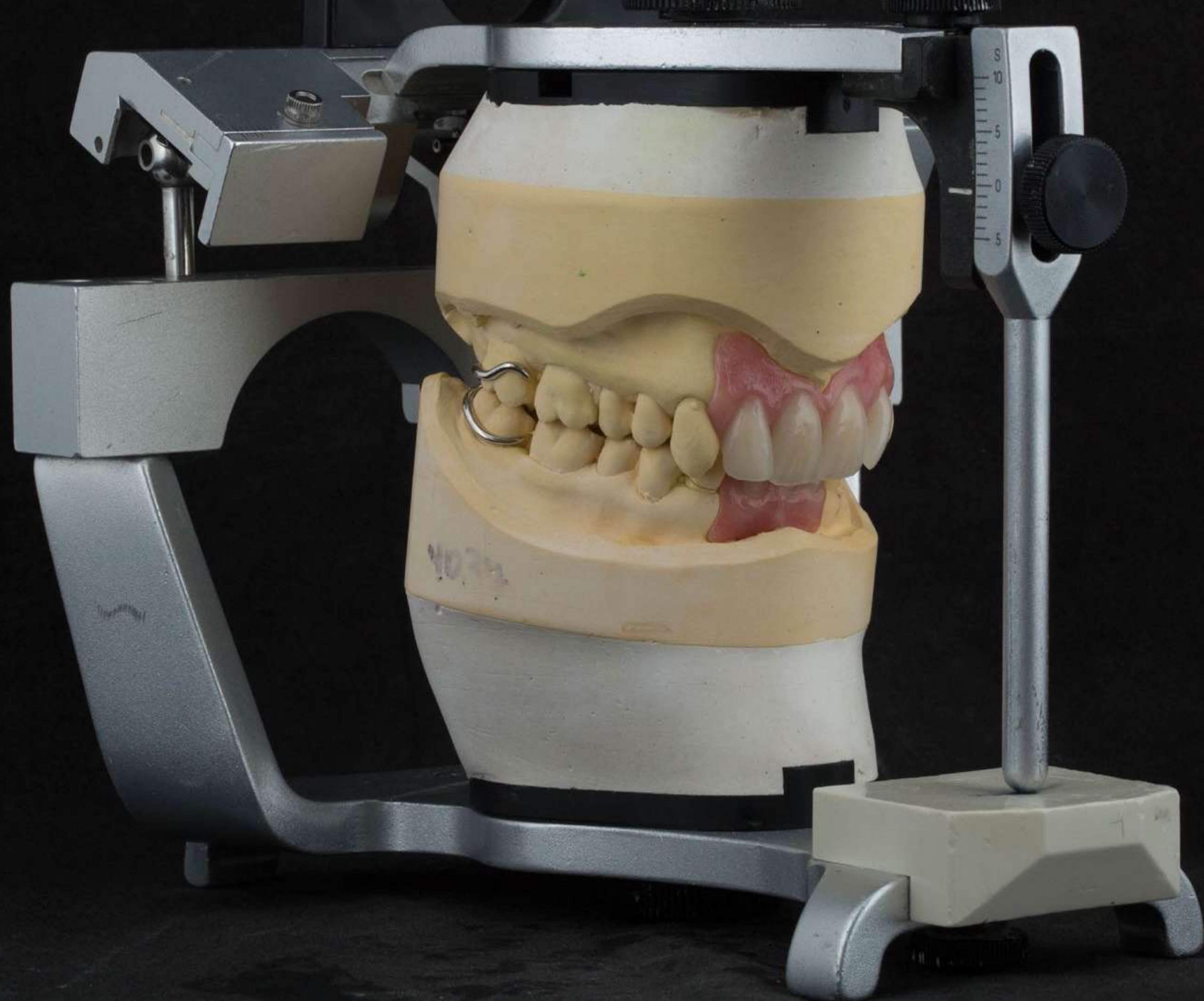

Try in

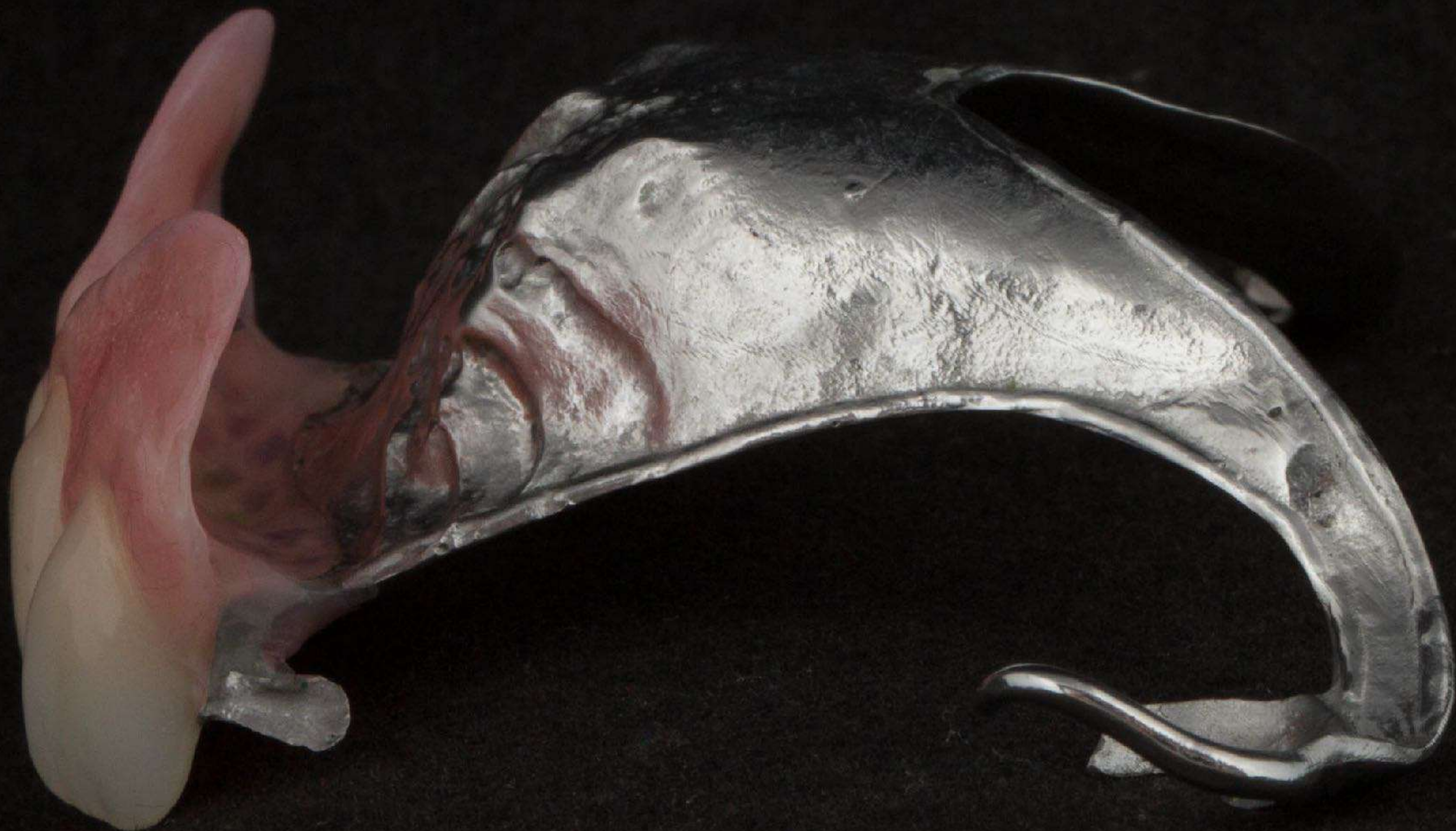


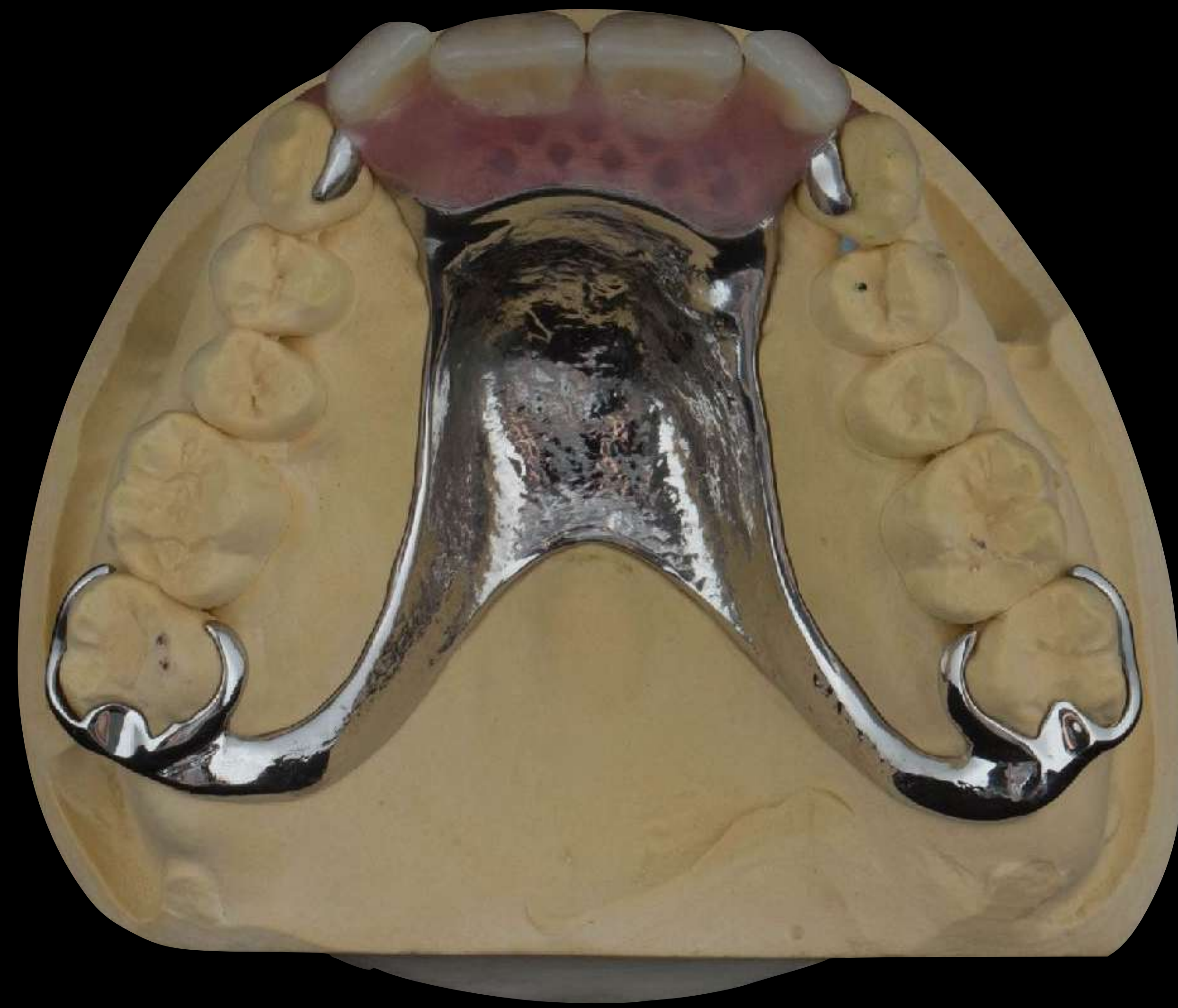


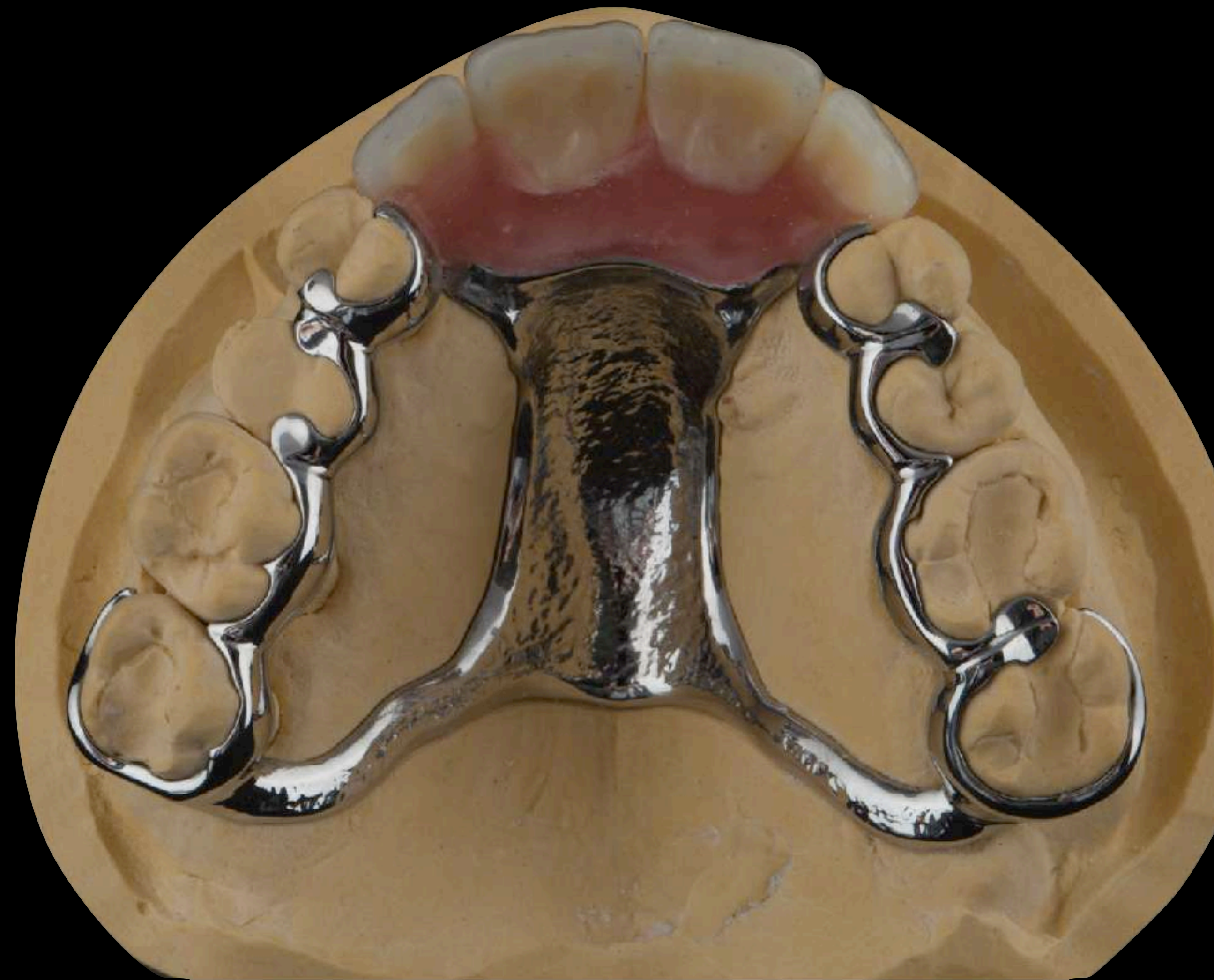


Finish

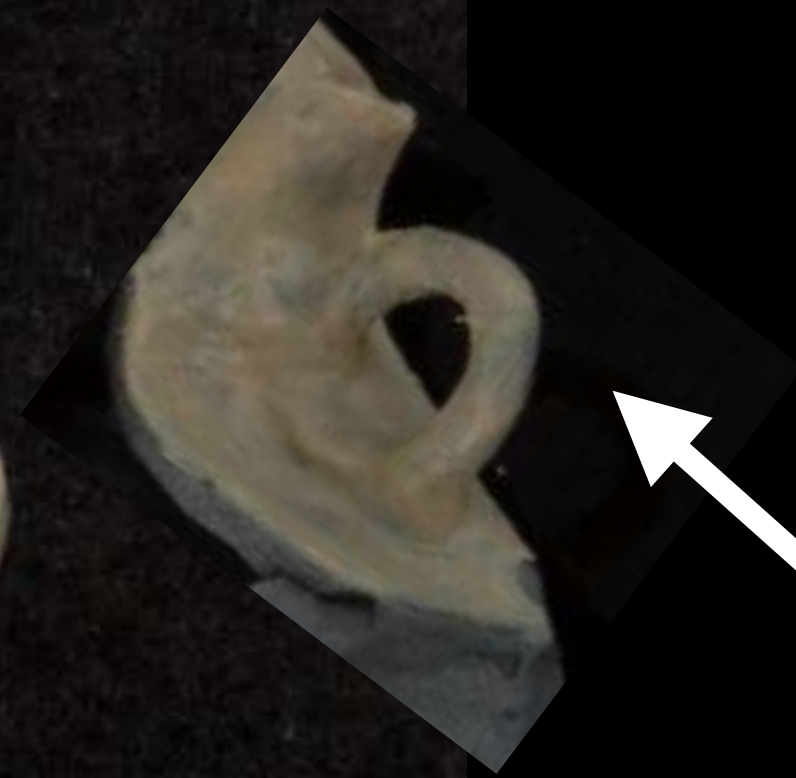
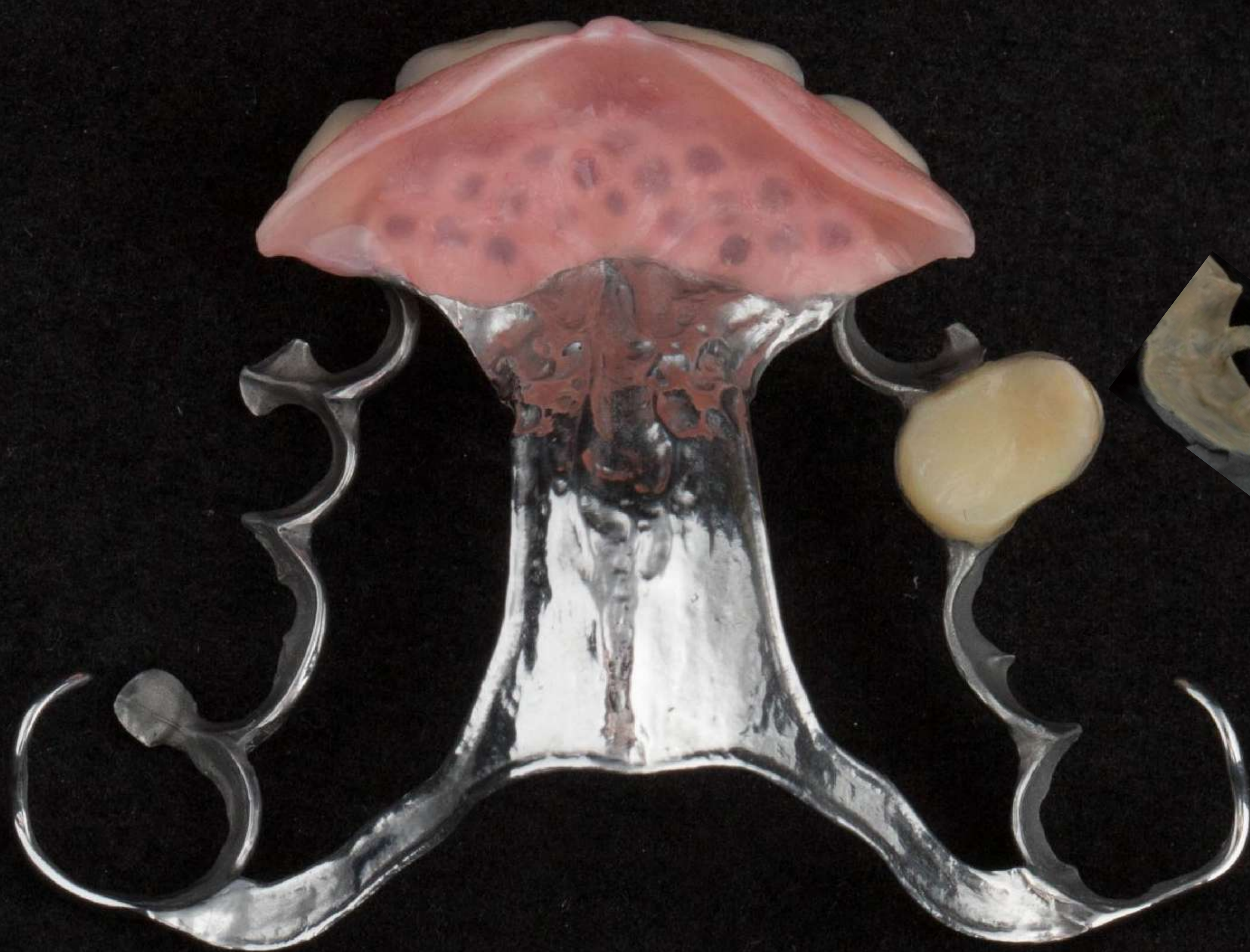



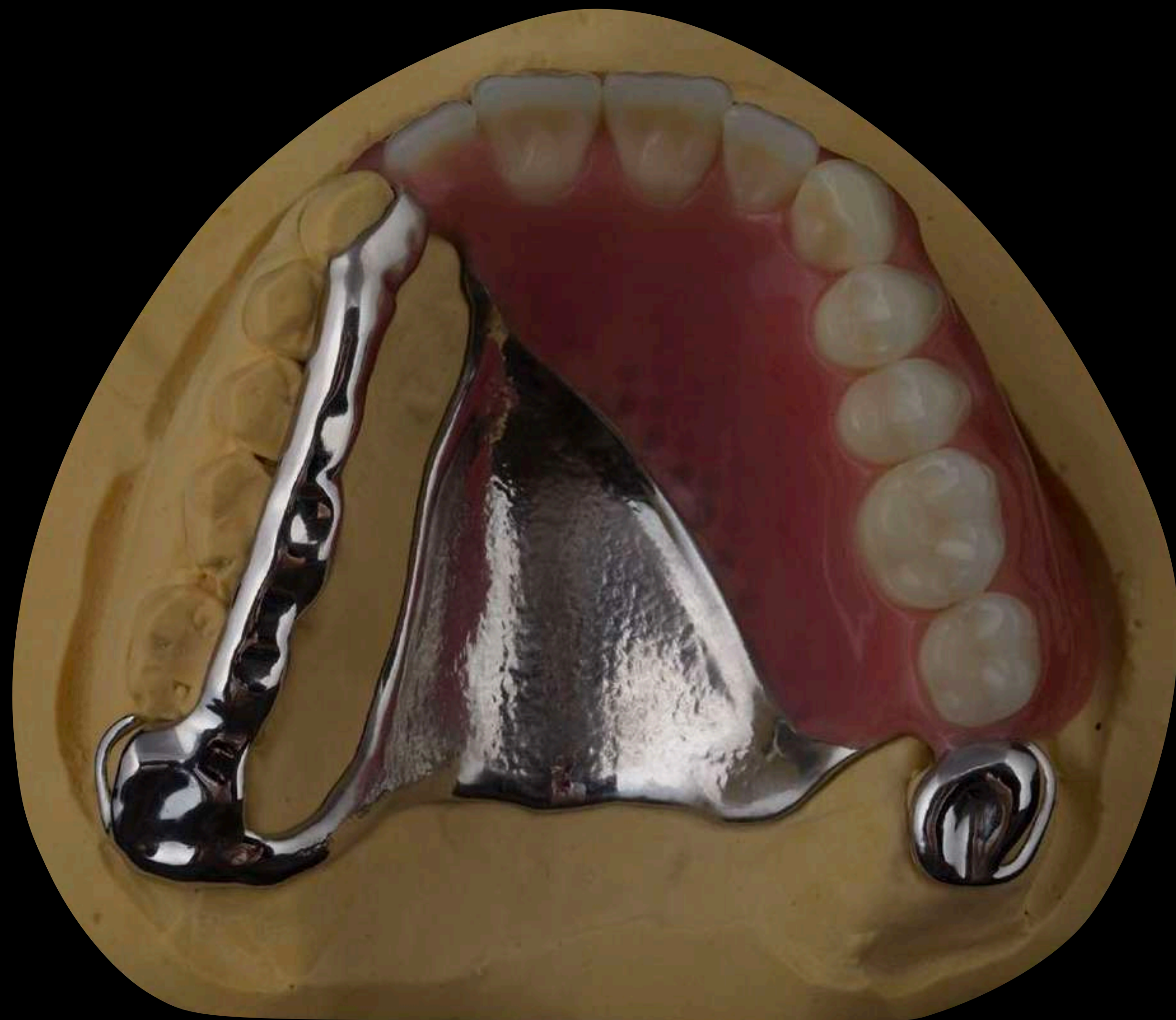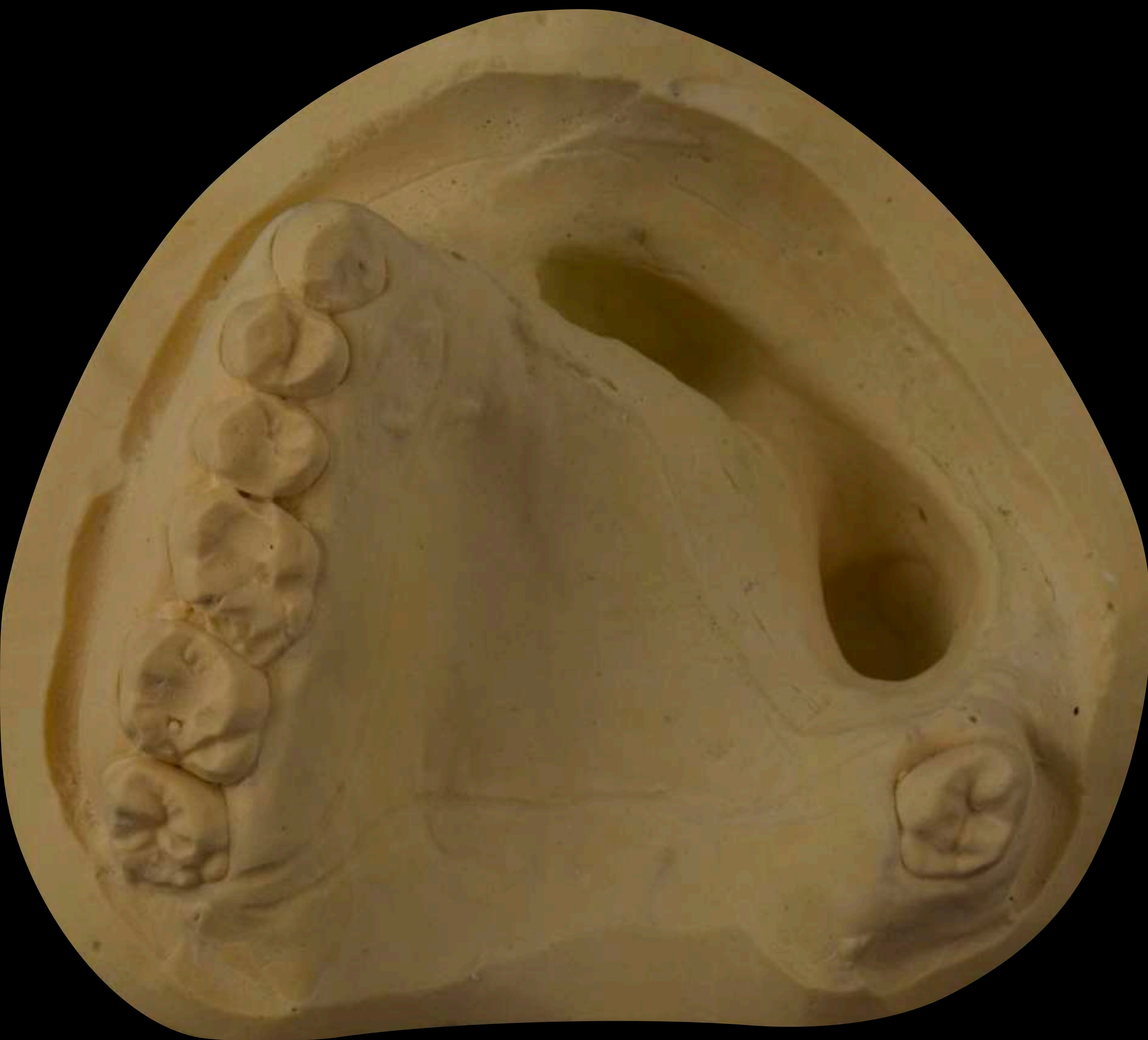Good prognosis



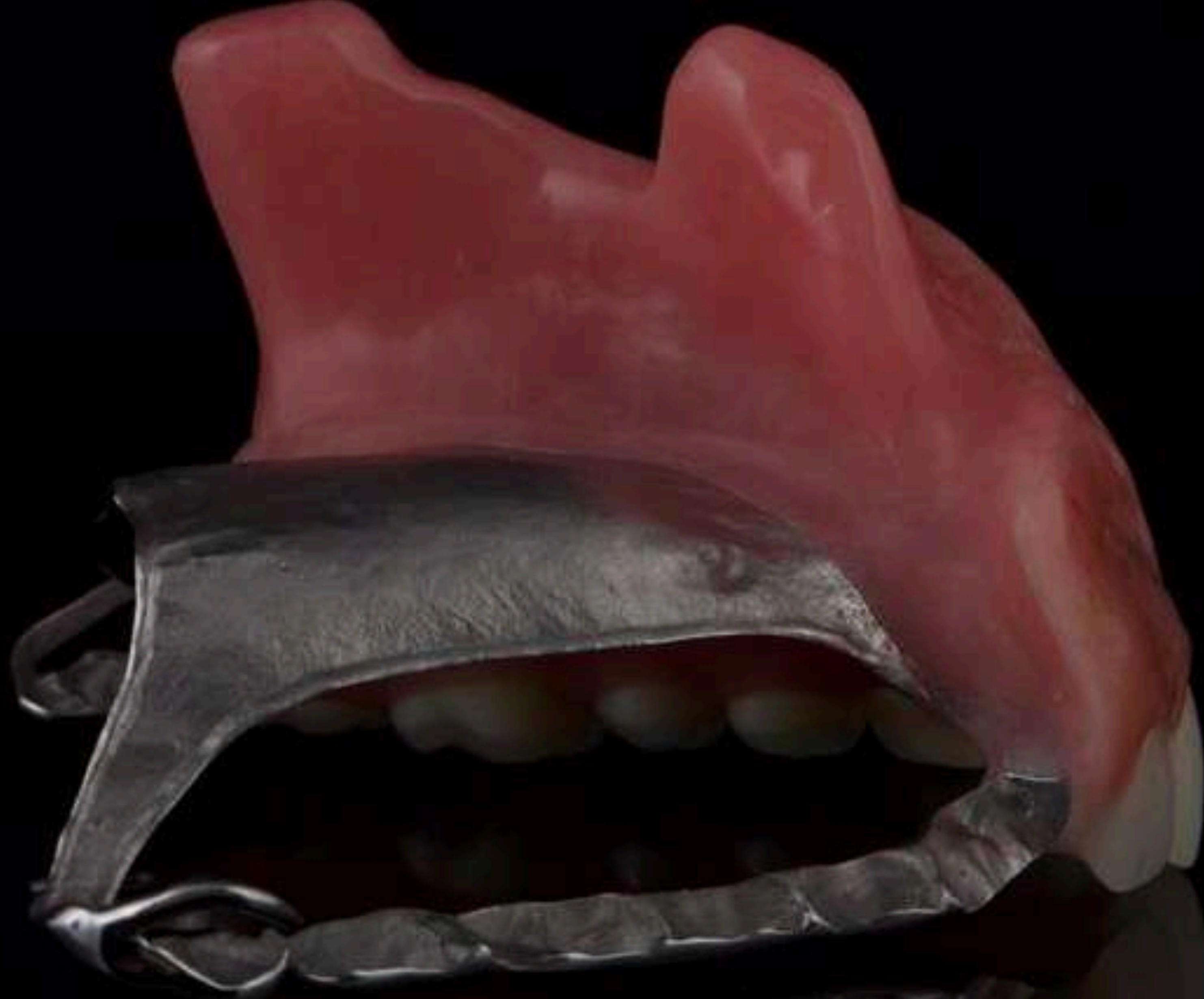Poor prognosis



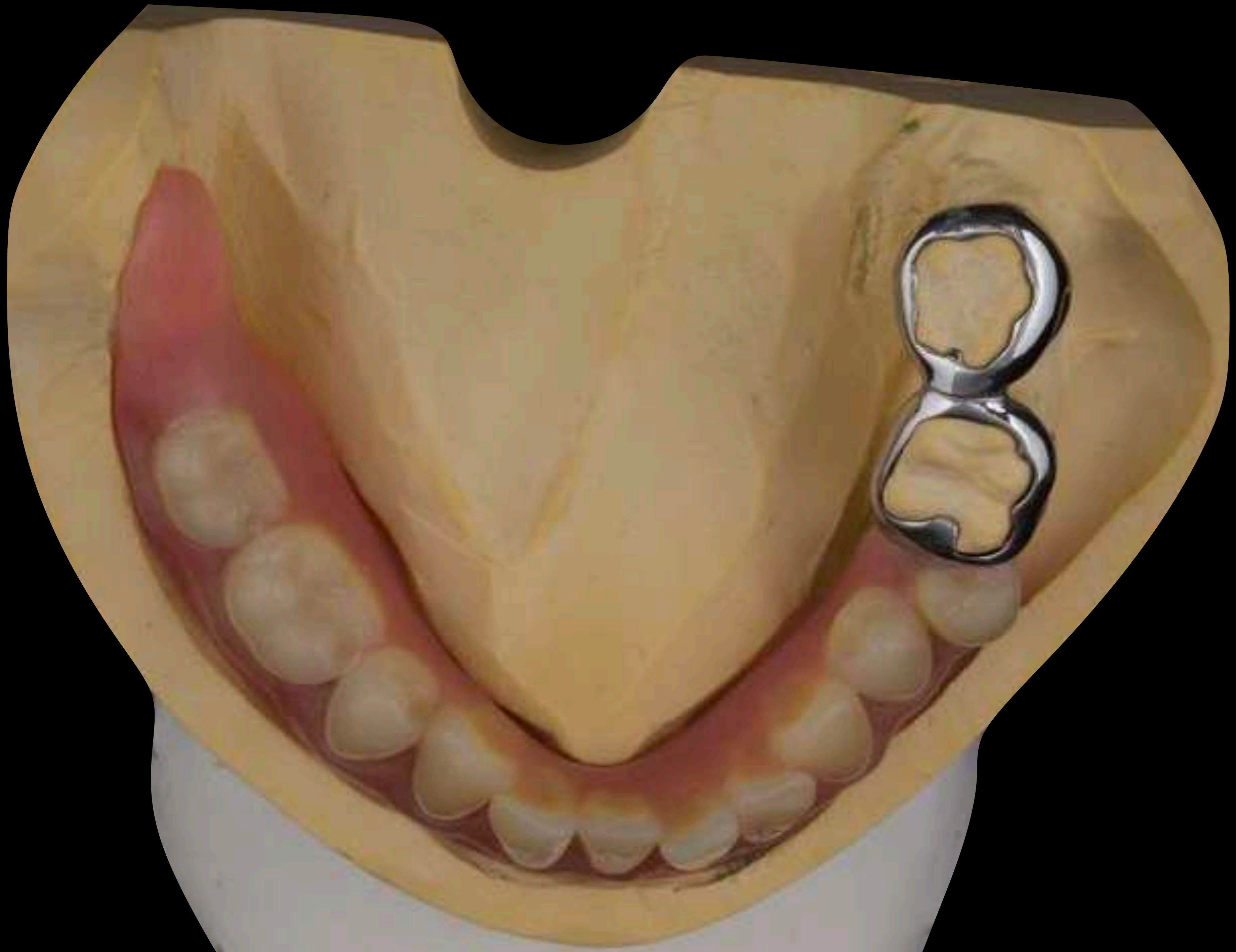Welded tag
attaches
tooth

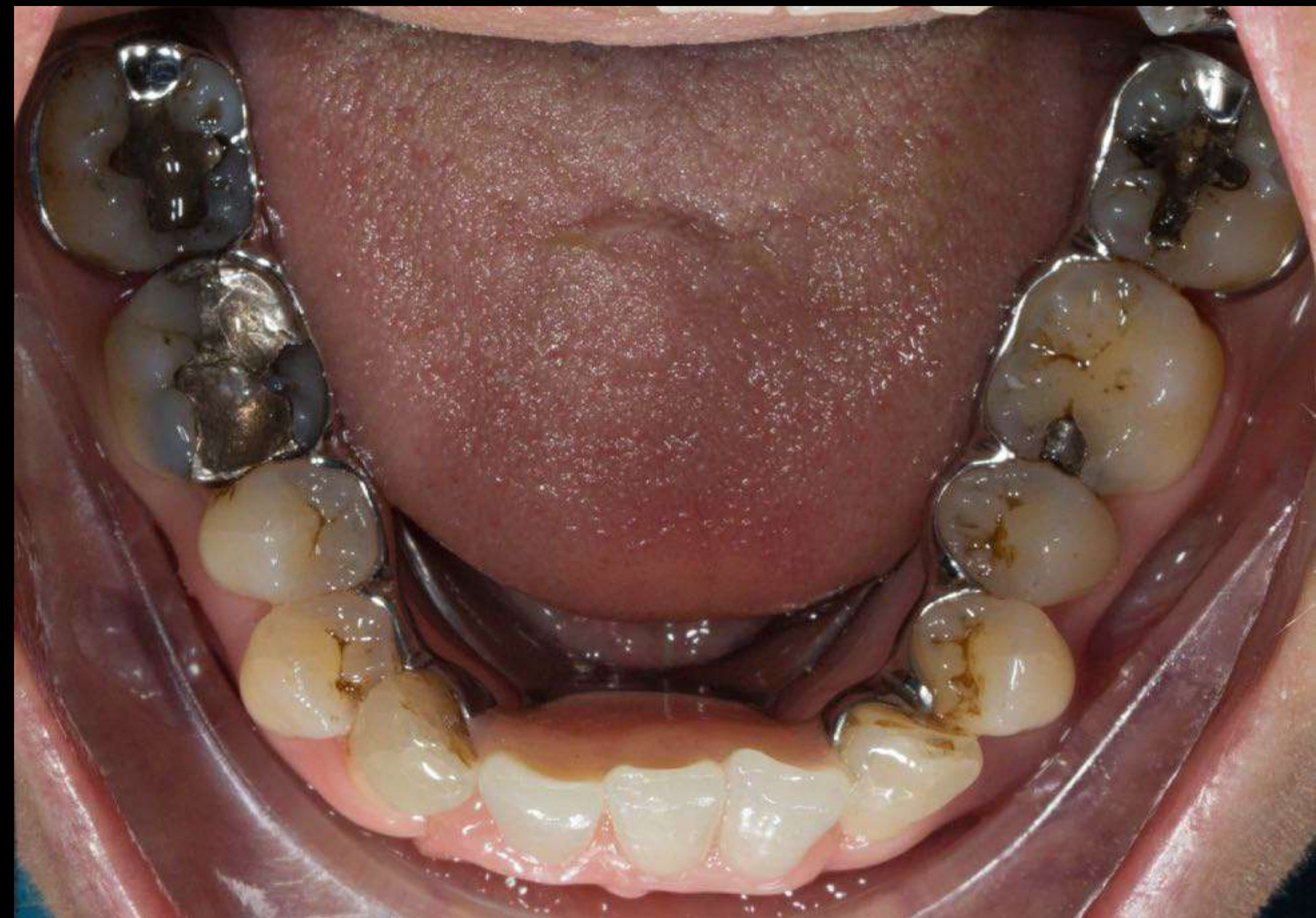
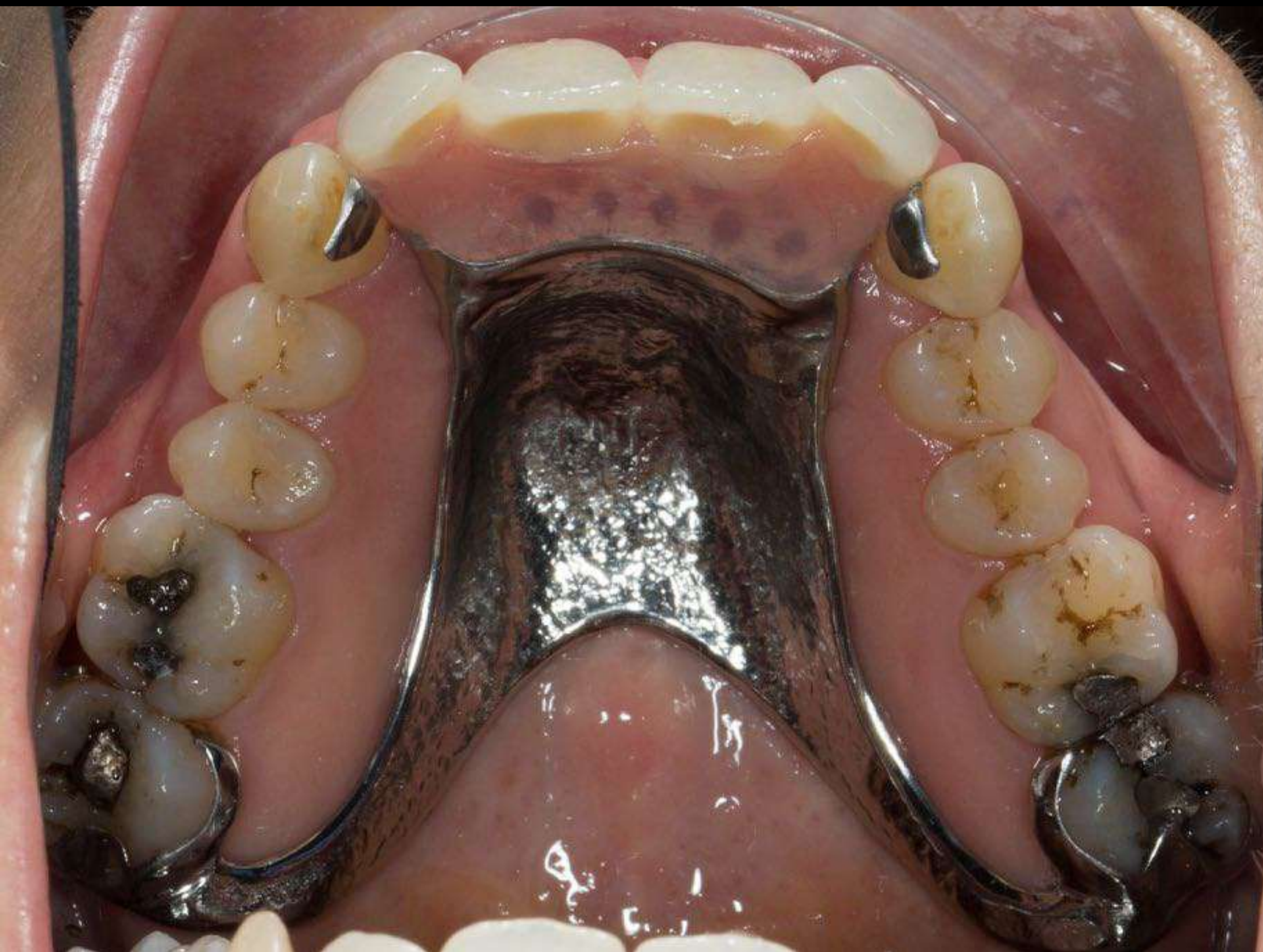

Finished RPD, splint/obturator

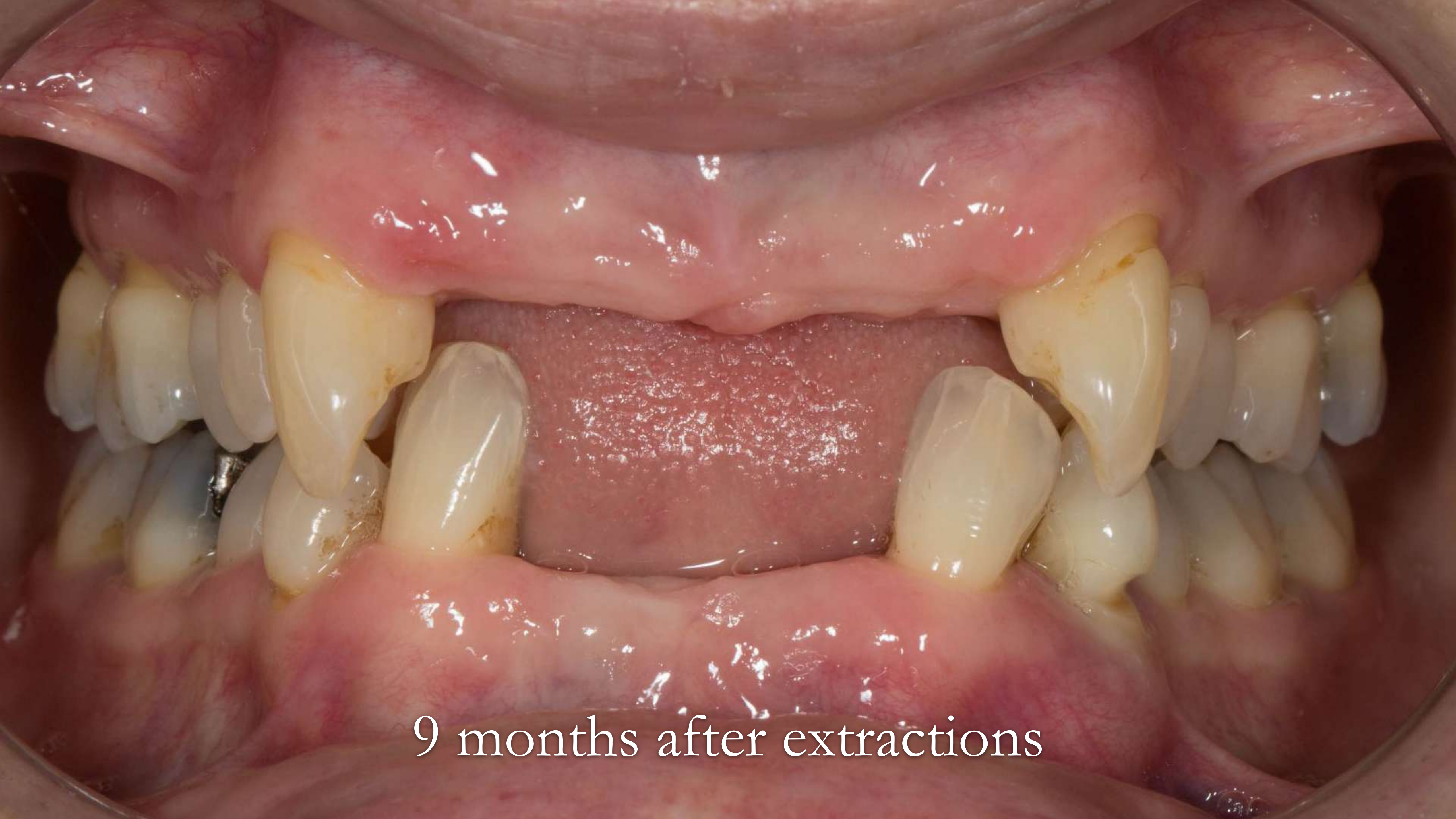

Finished denture with polished solid acrylic obturator

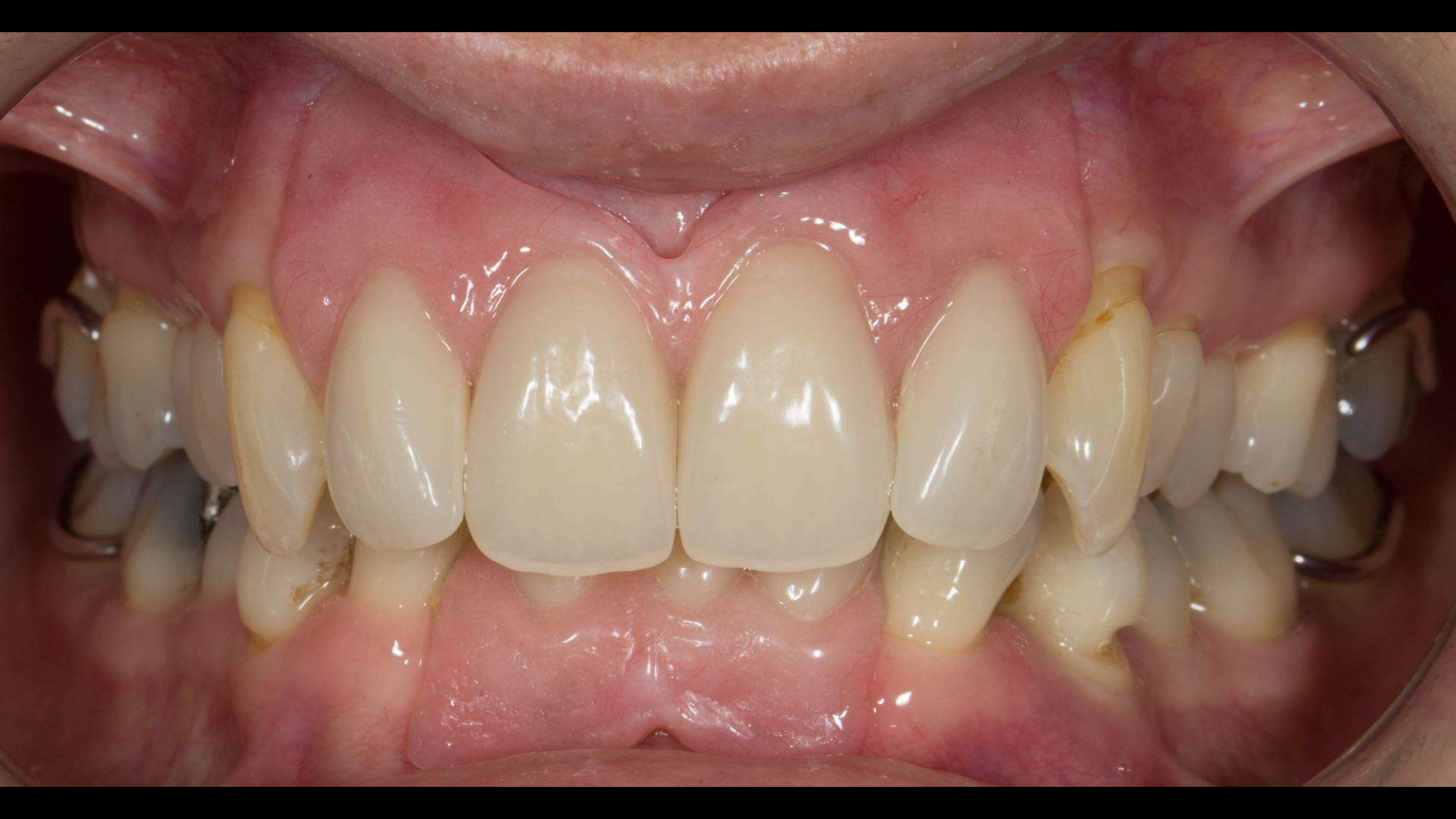


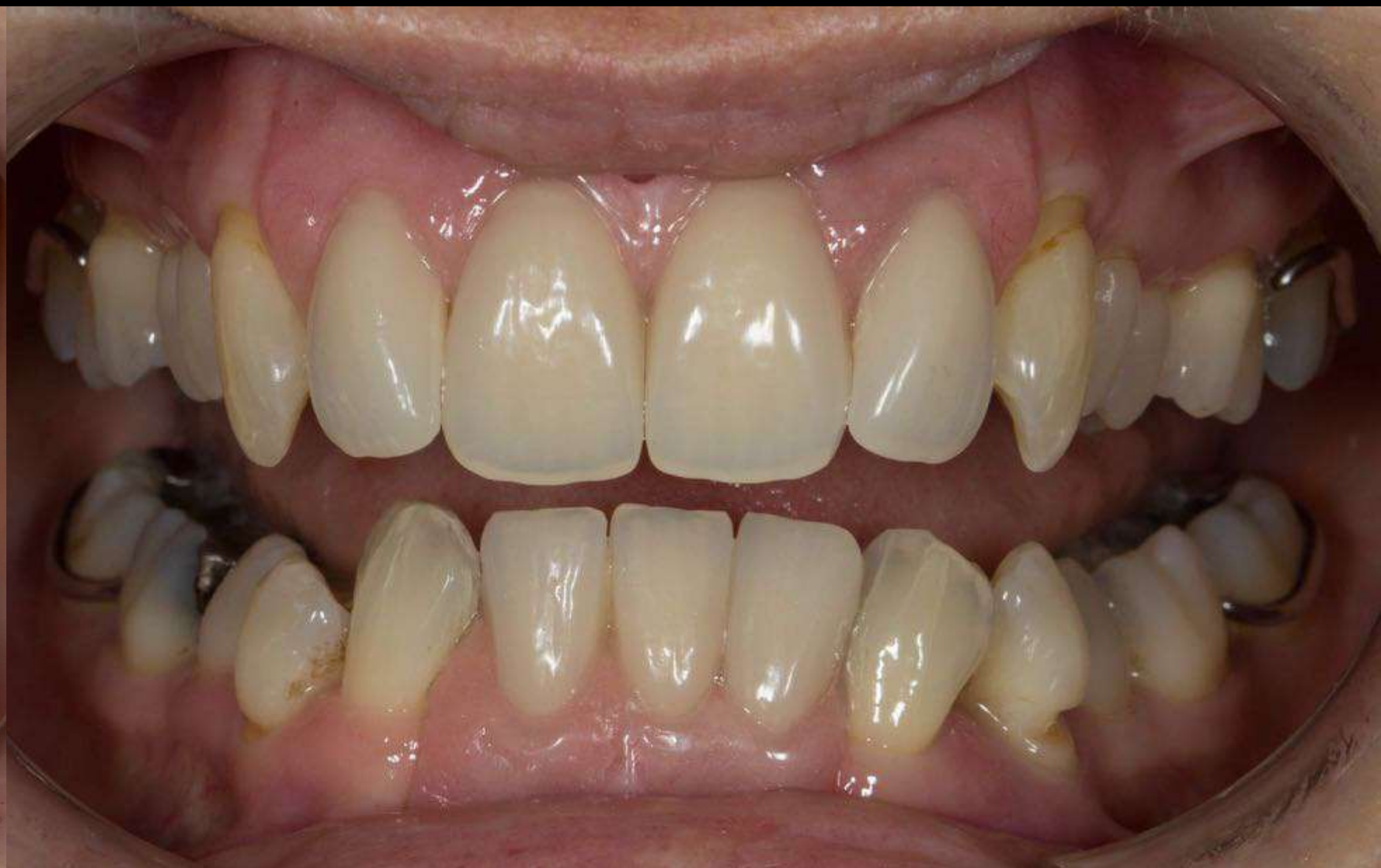
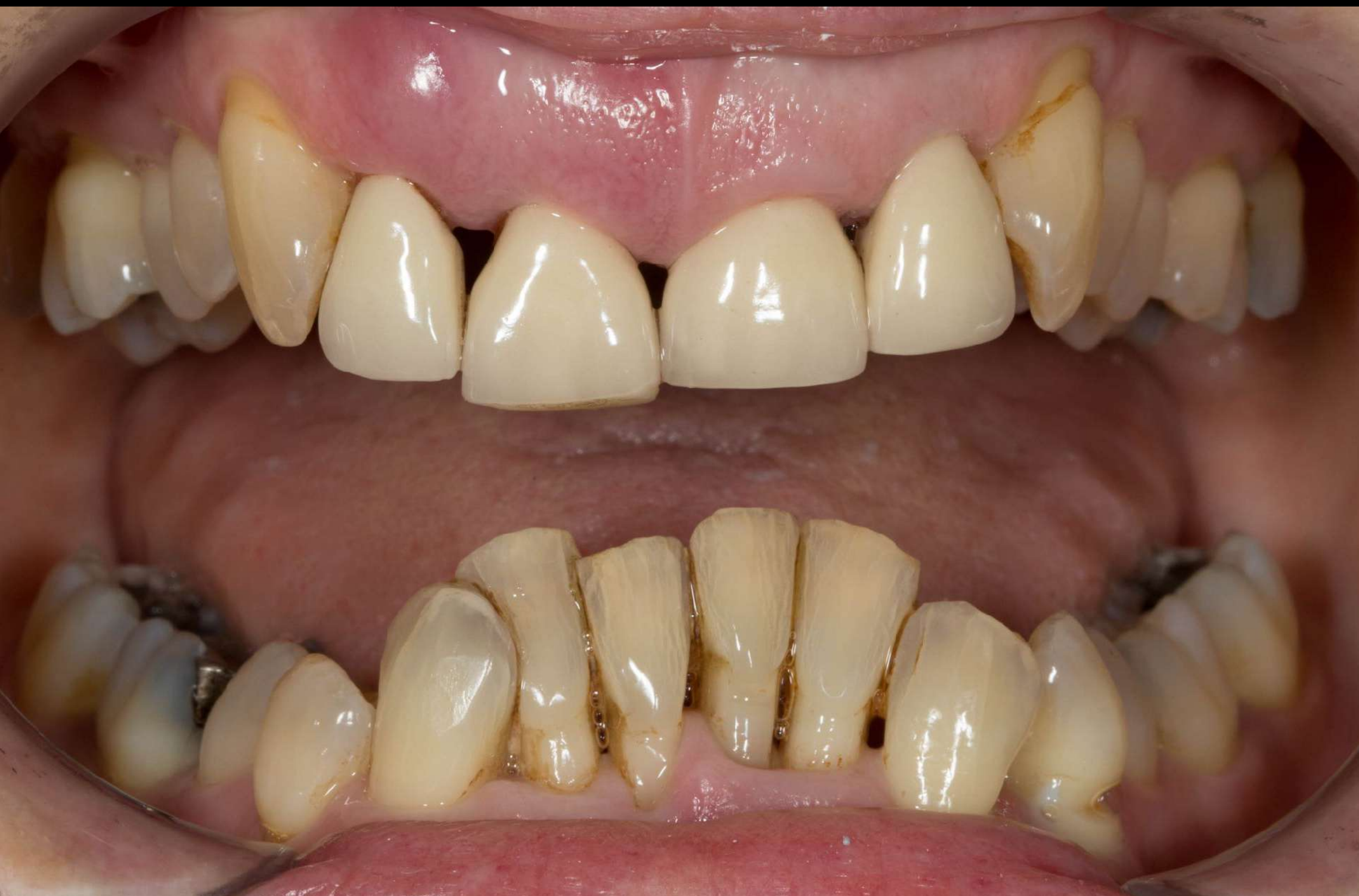Definitive dentures fitted 9 months after extractions

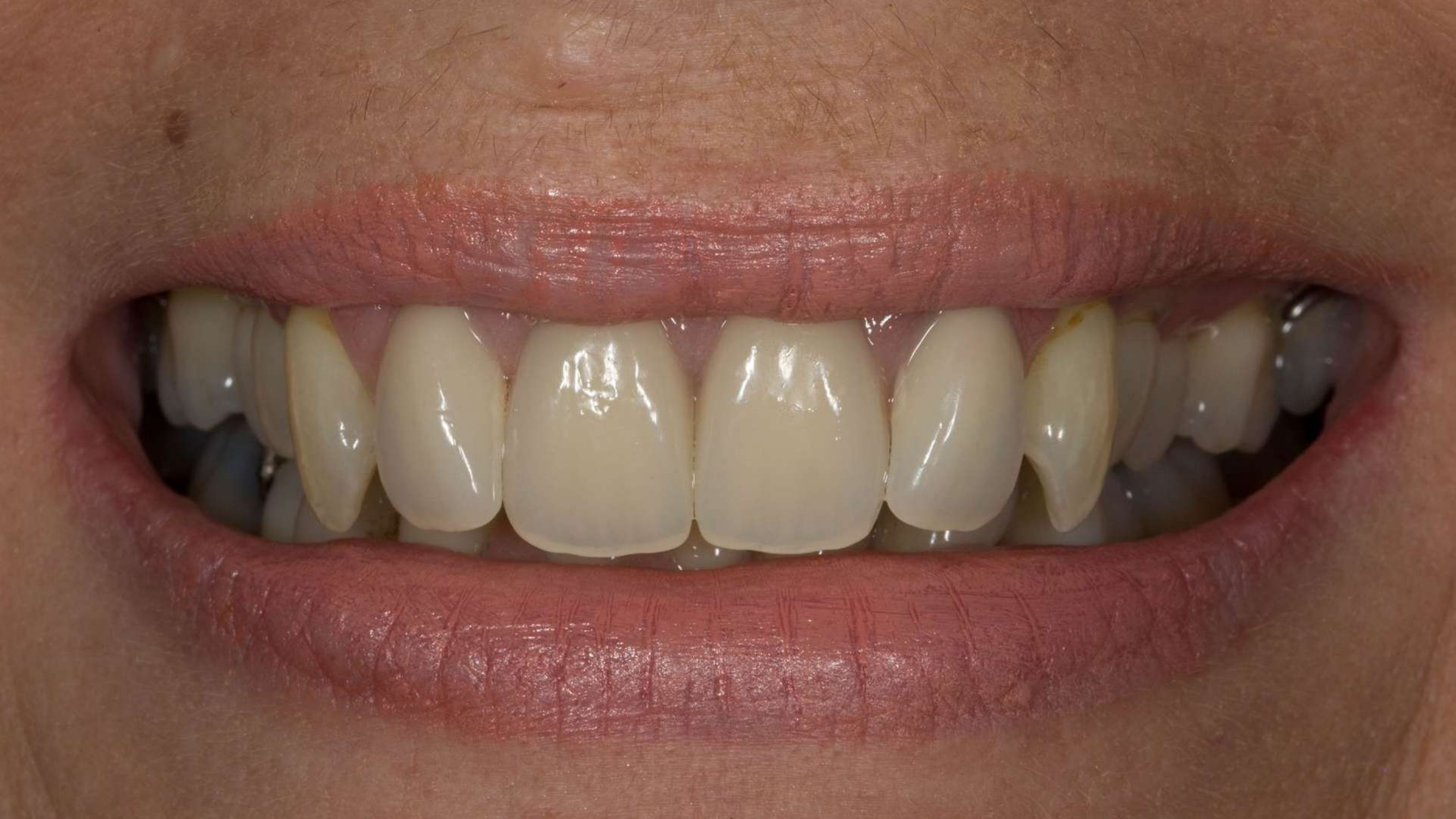

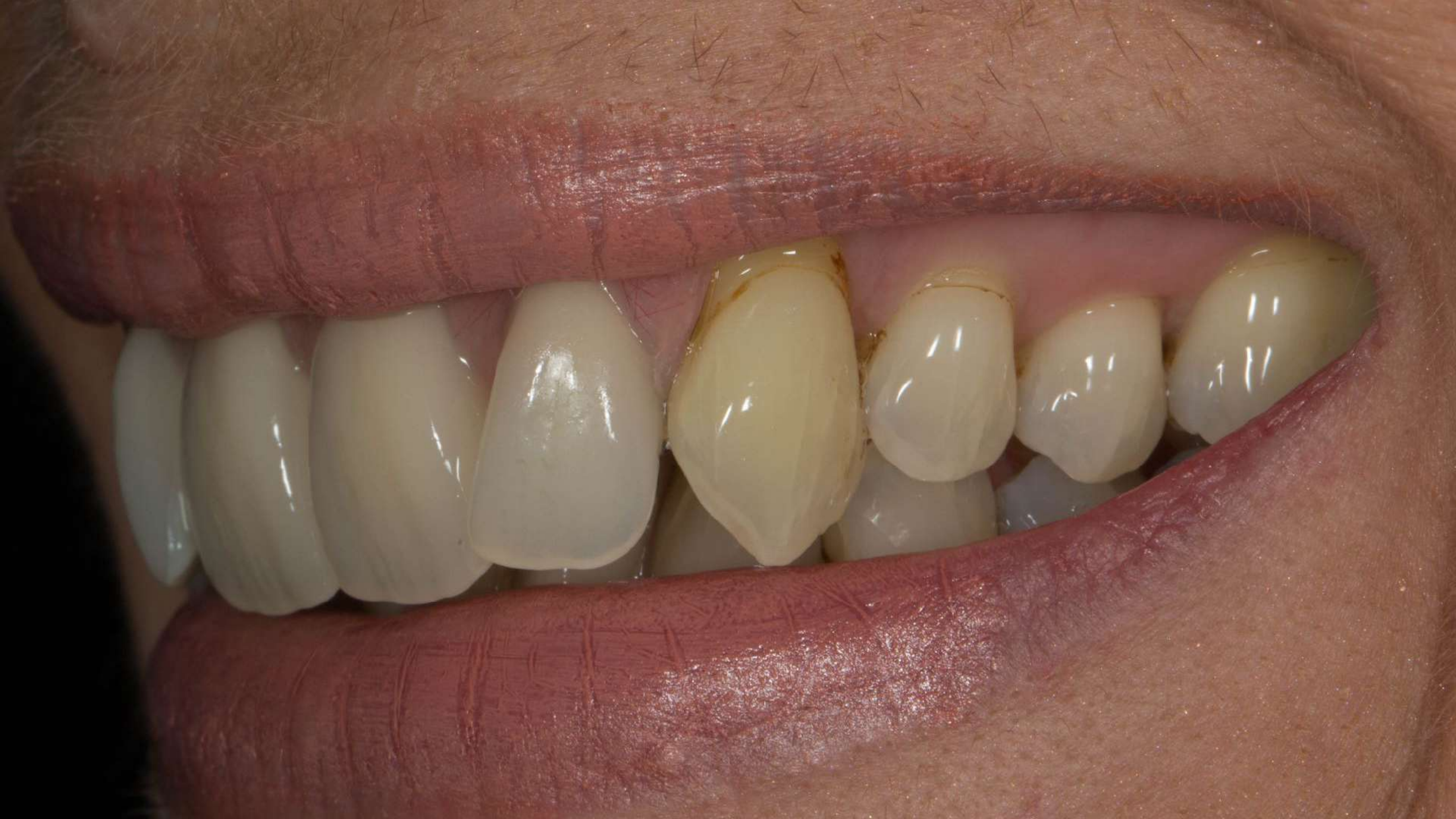9 months after extractions

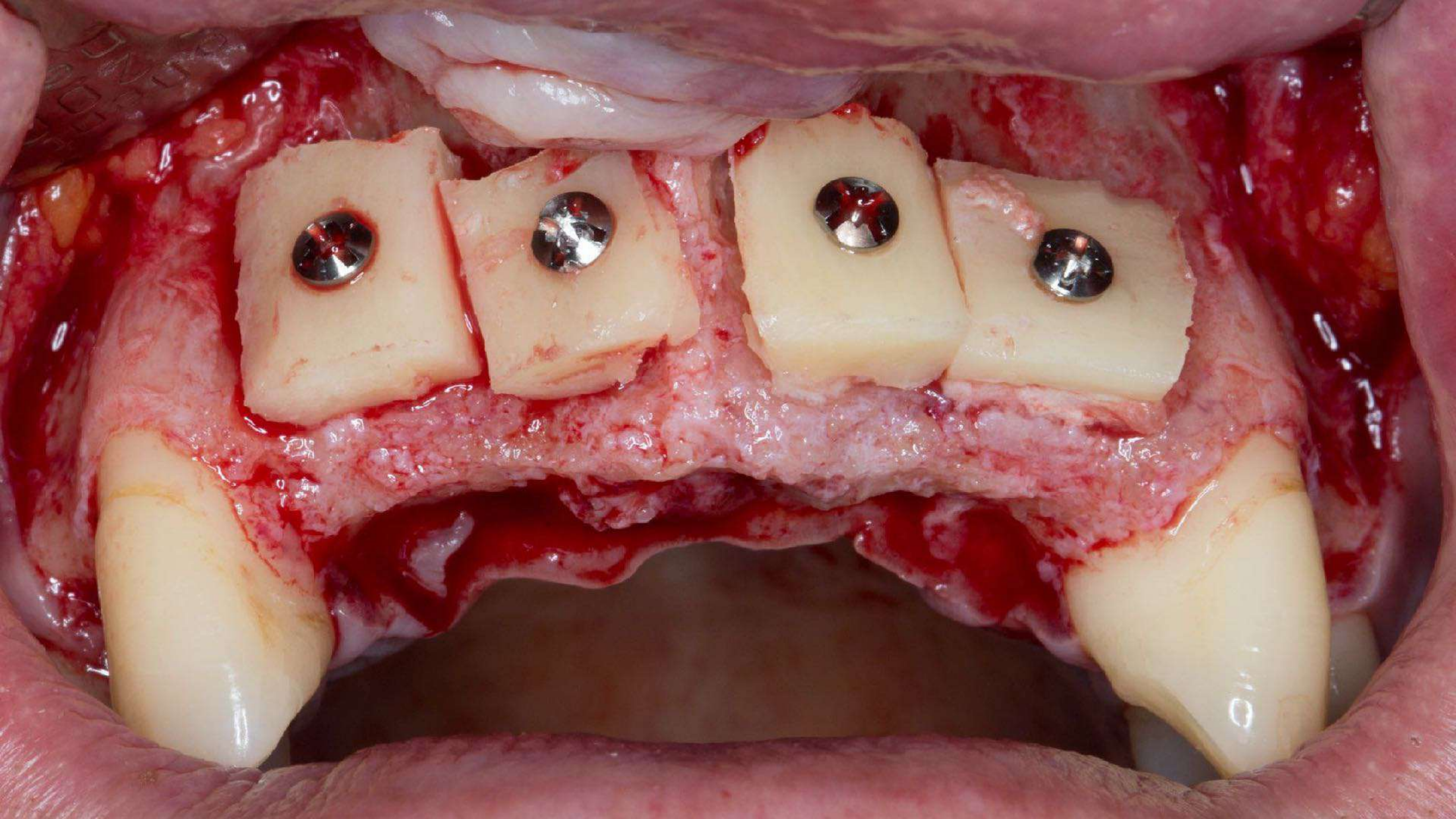


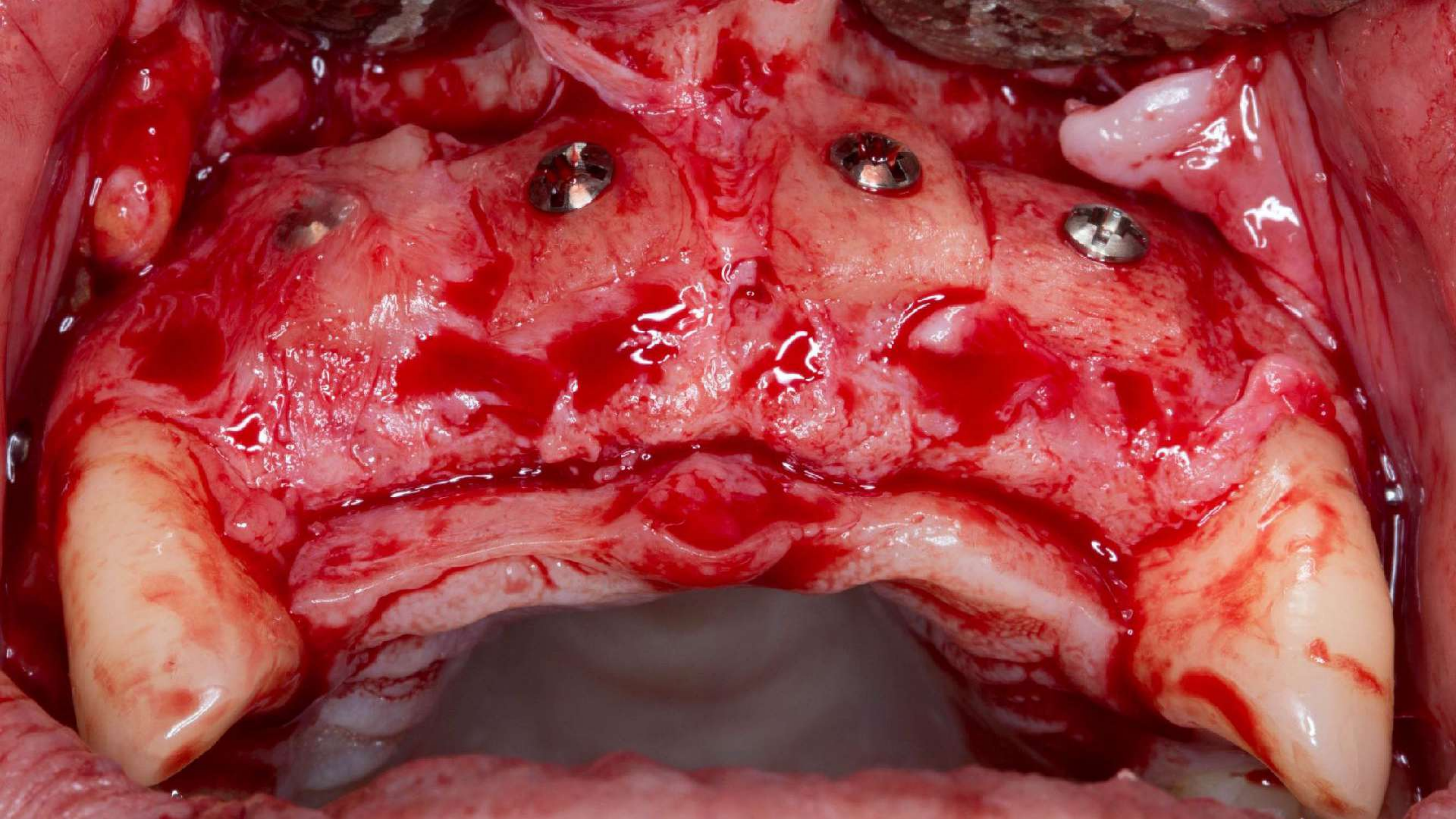


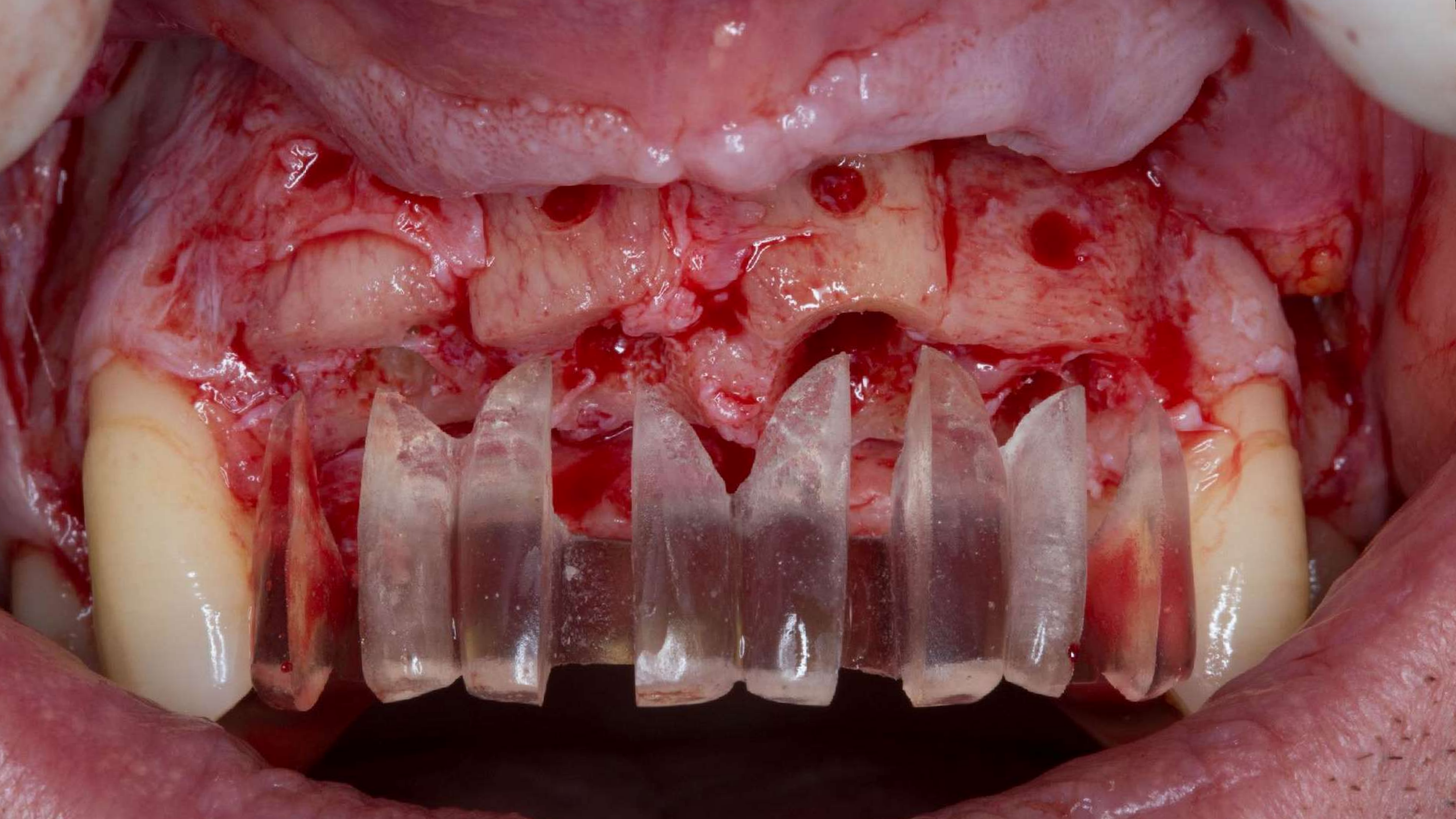
Definitive dentures fitted 9 months after extractions

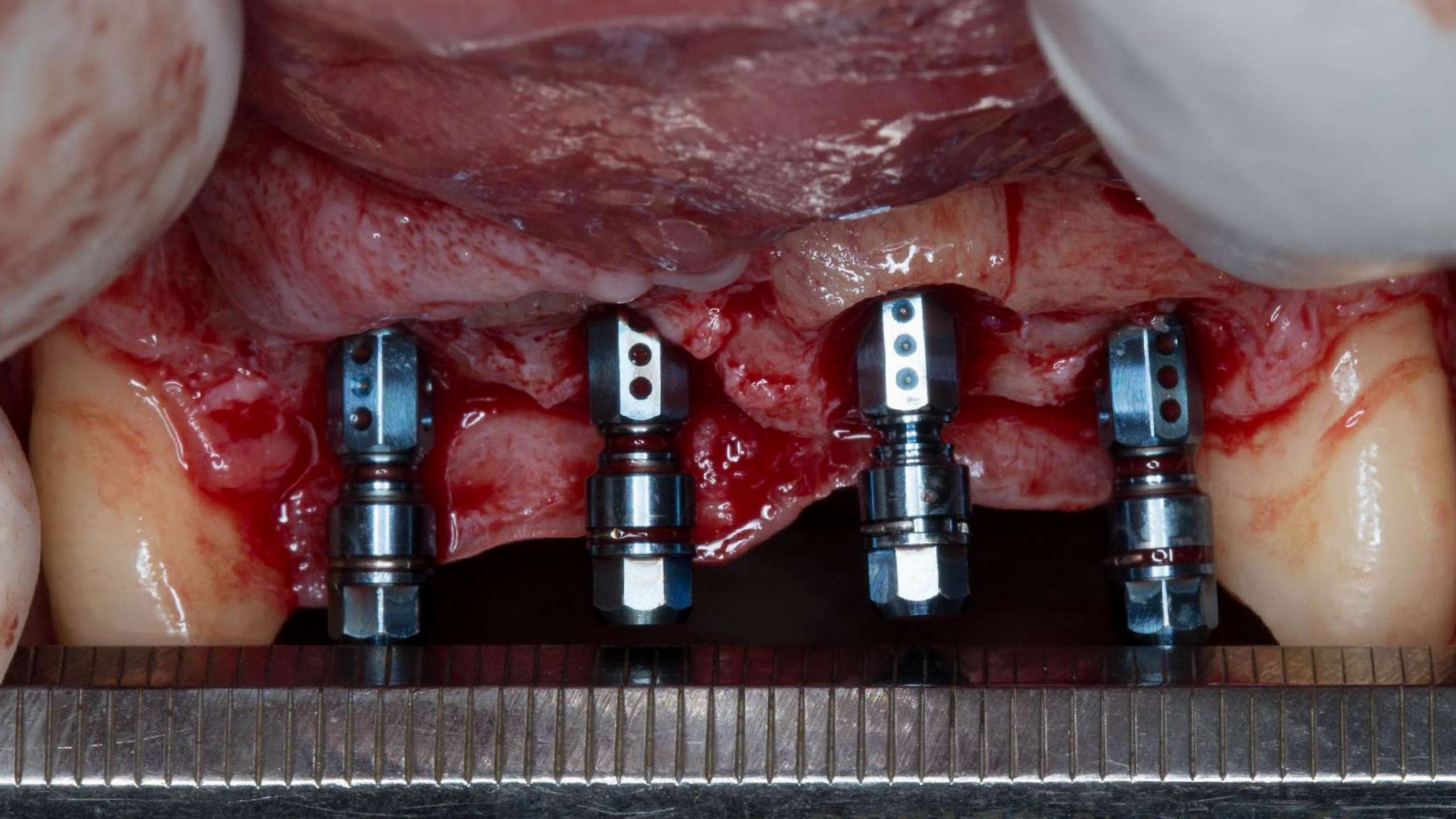


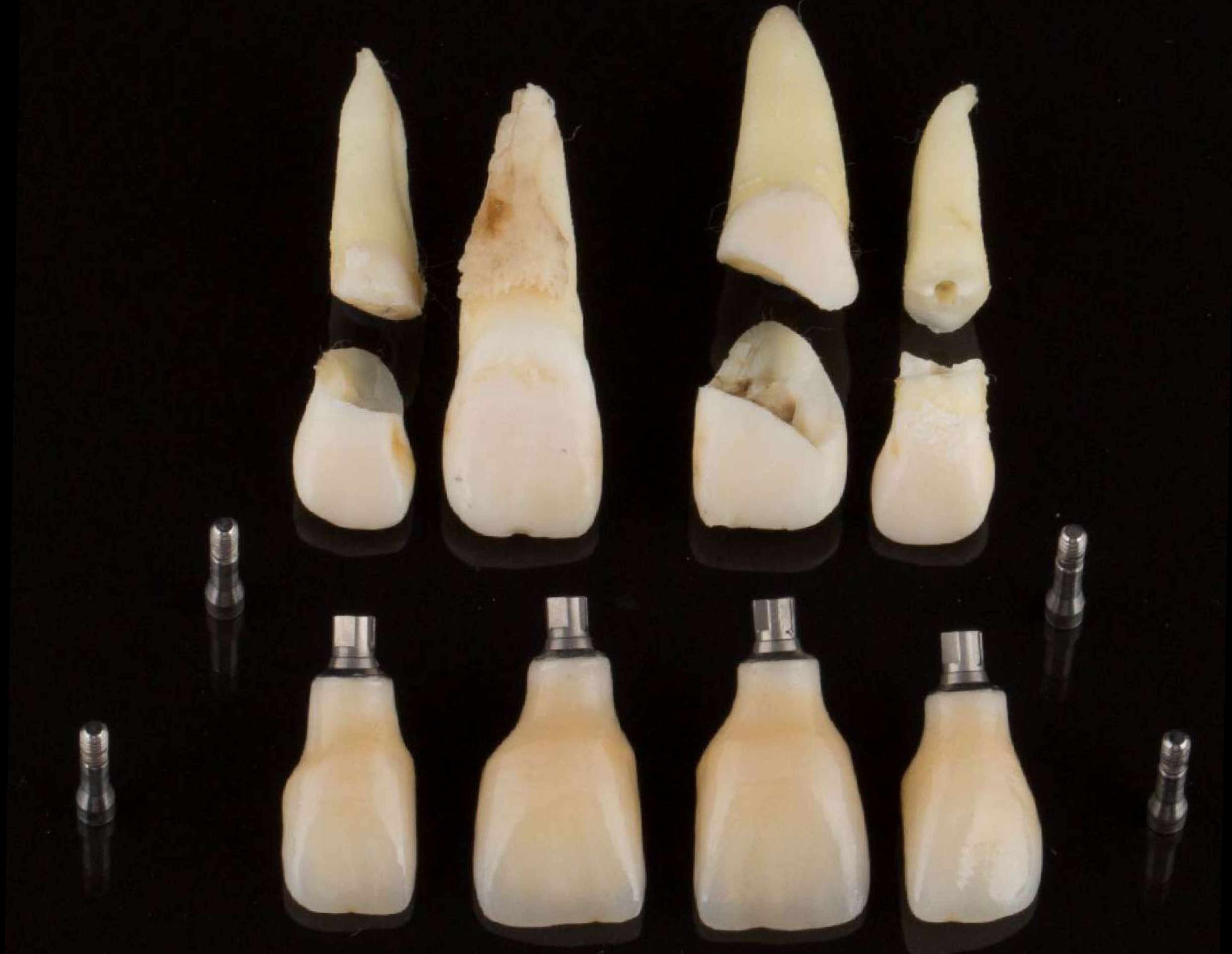


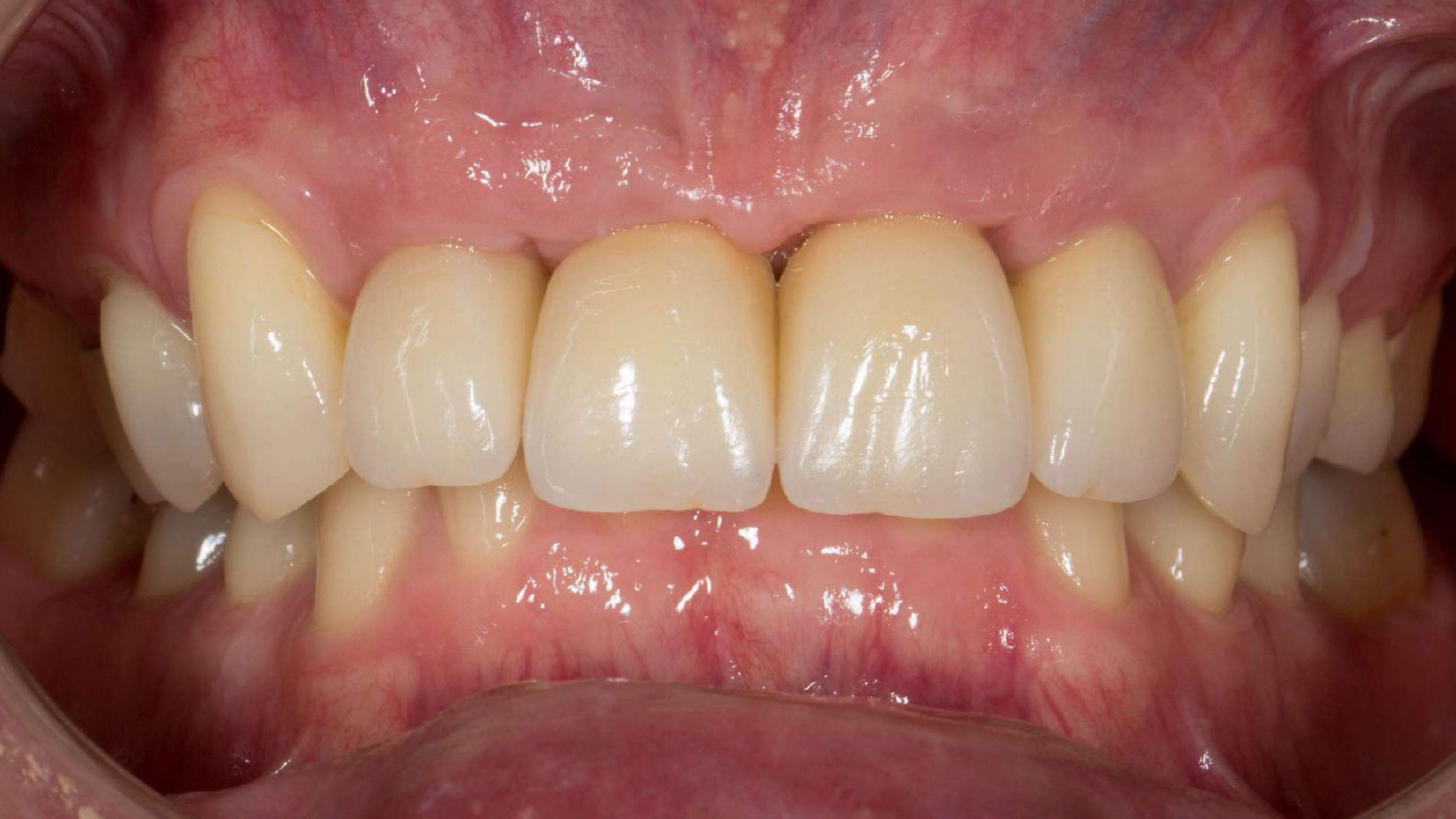


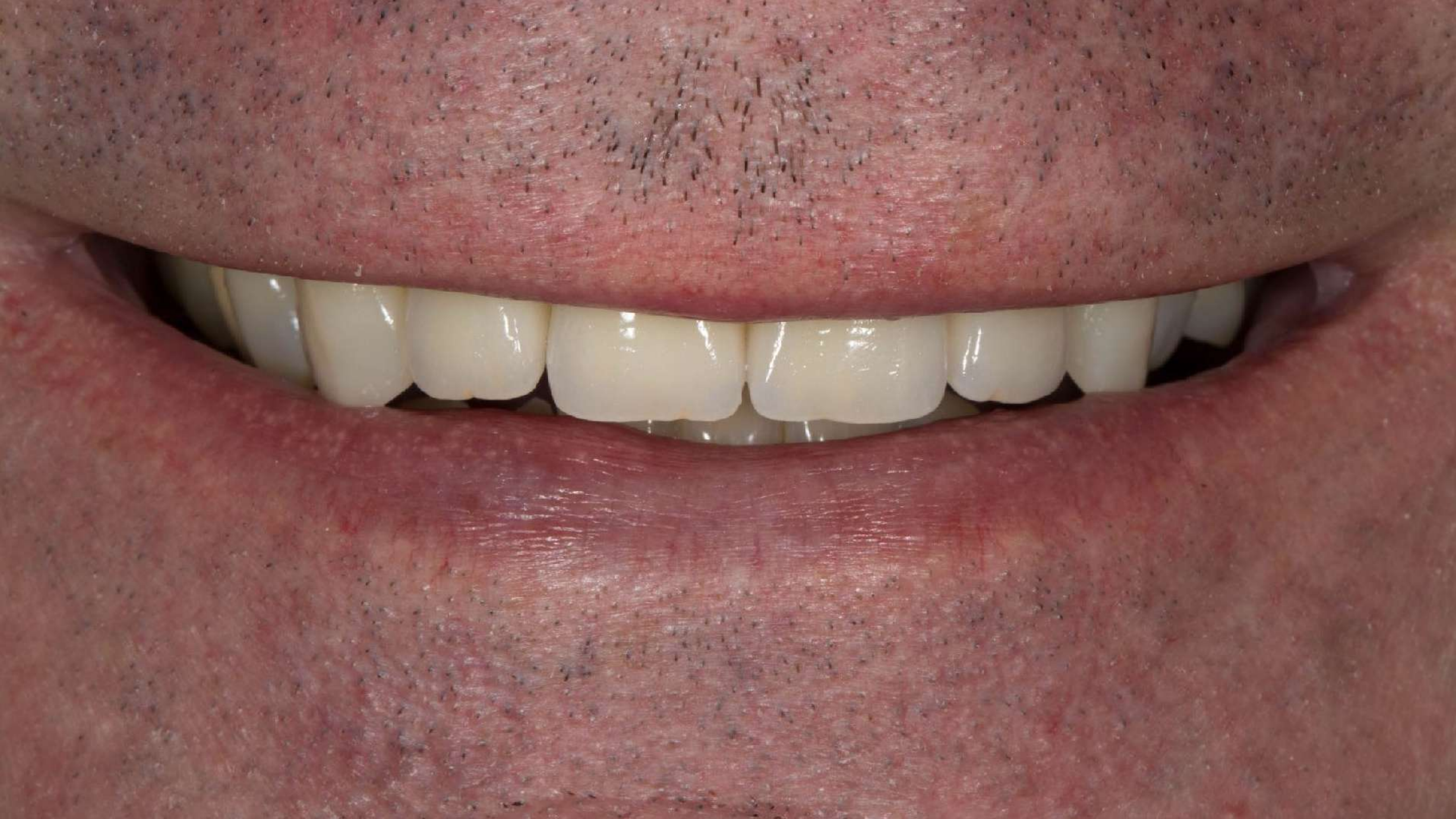




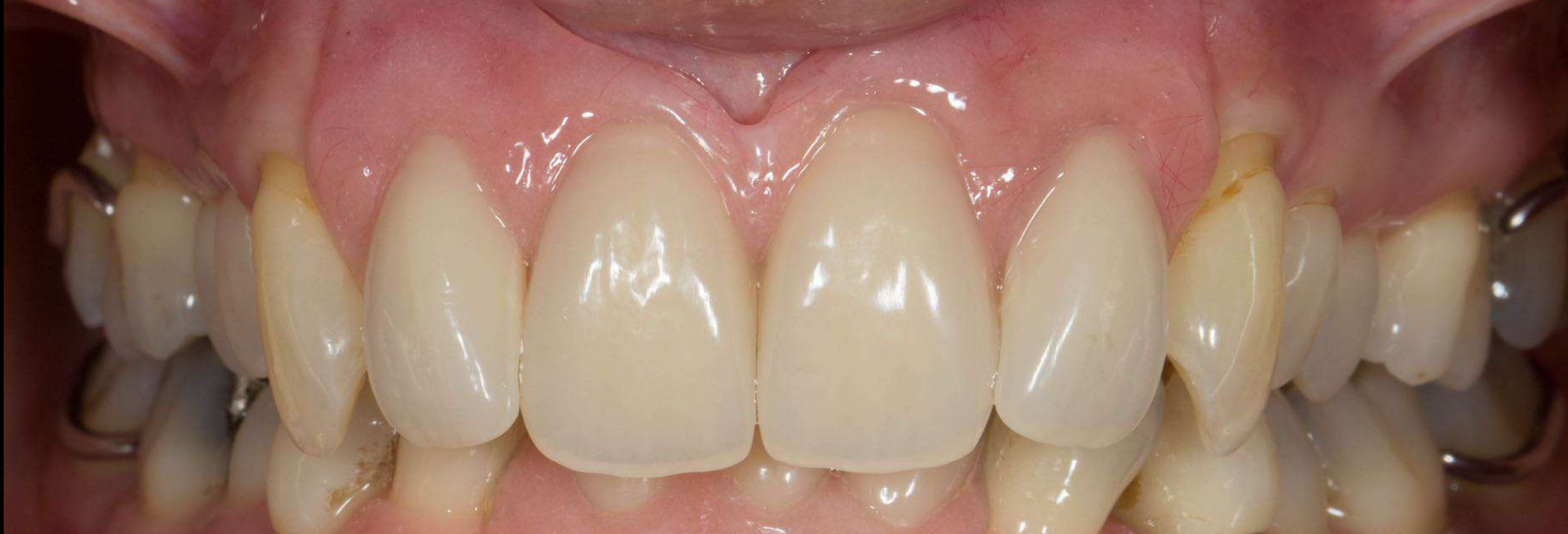




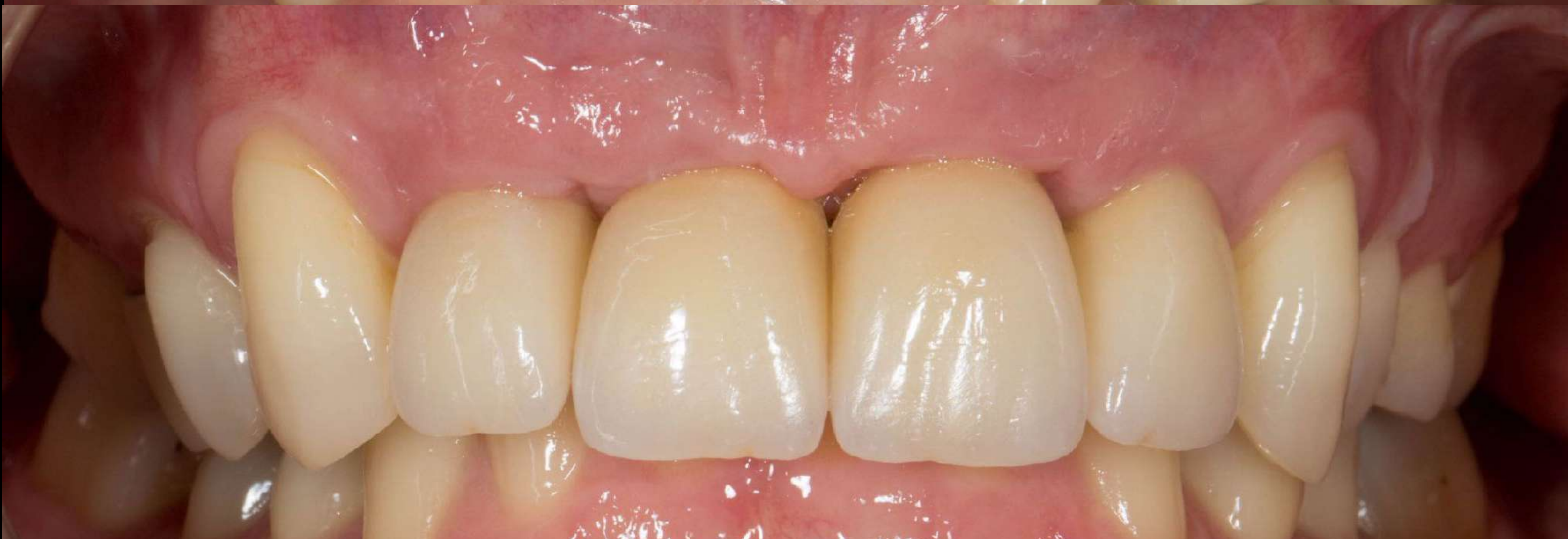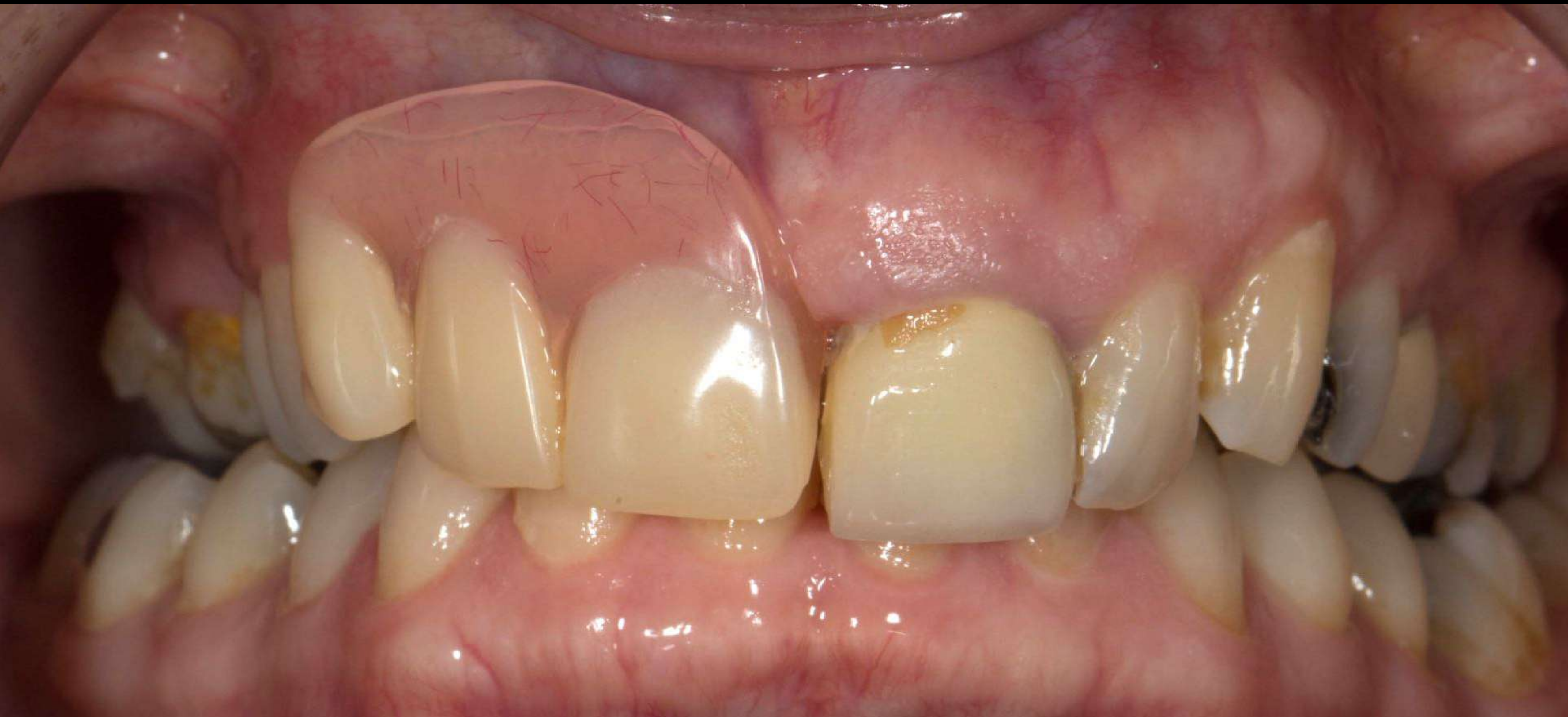Denture

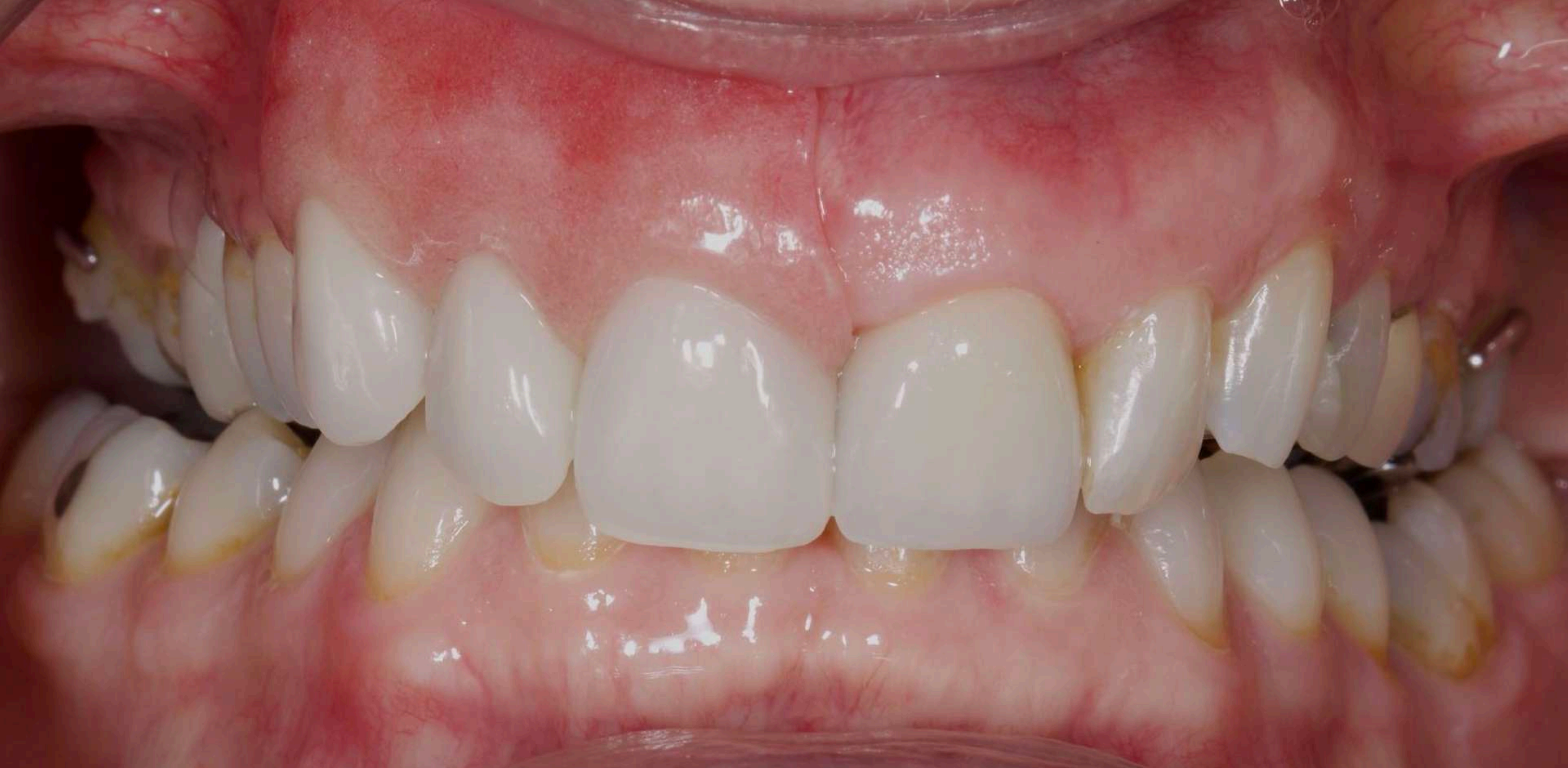

Implant
crowns



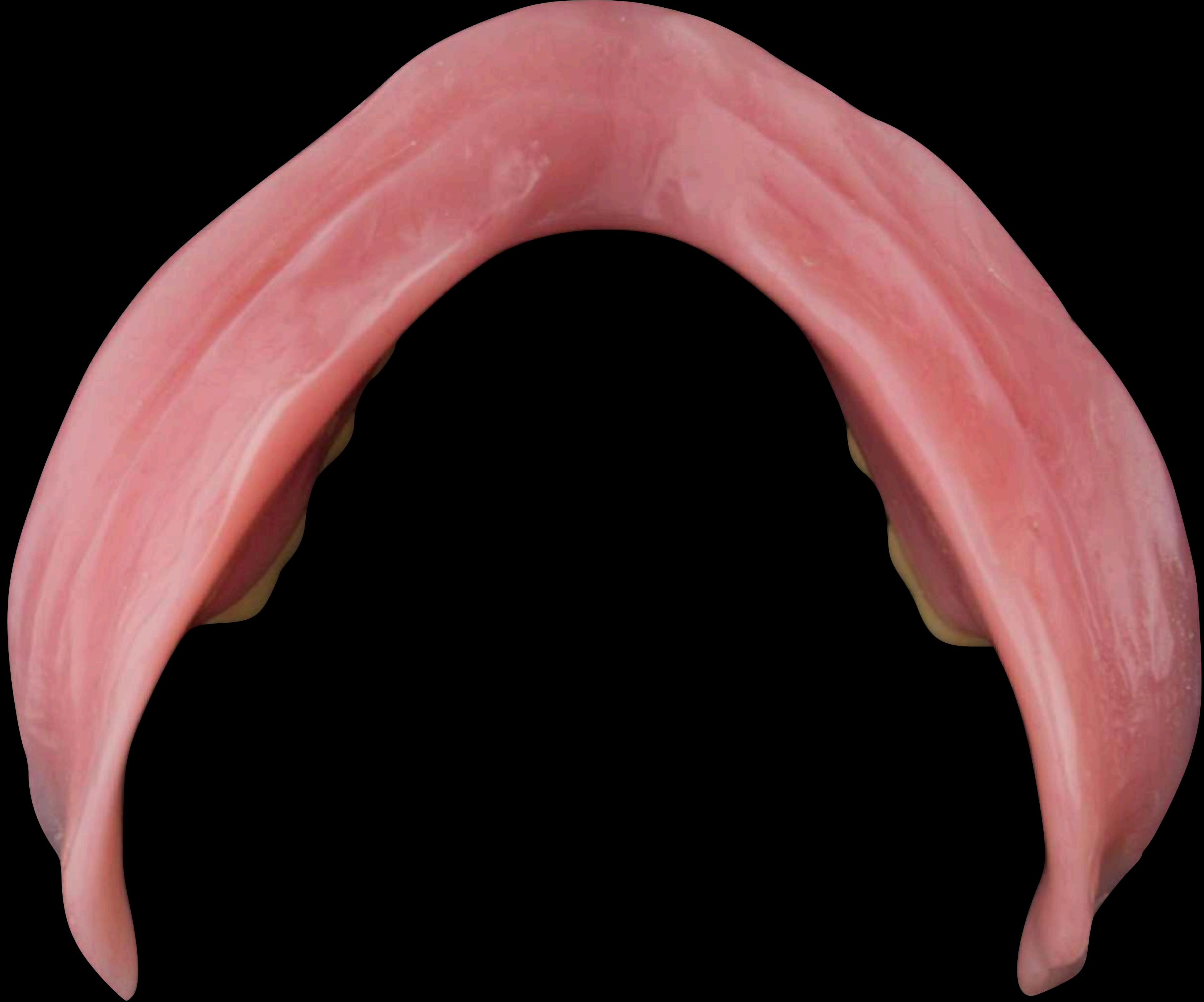

Old RPD



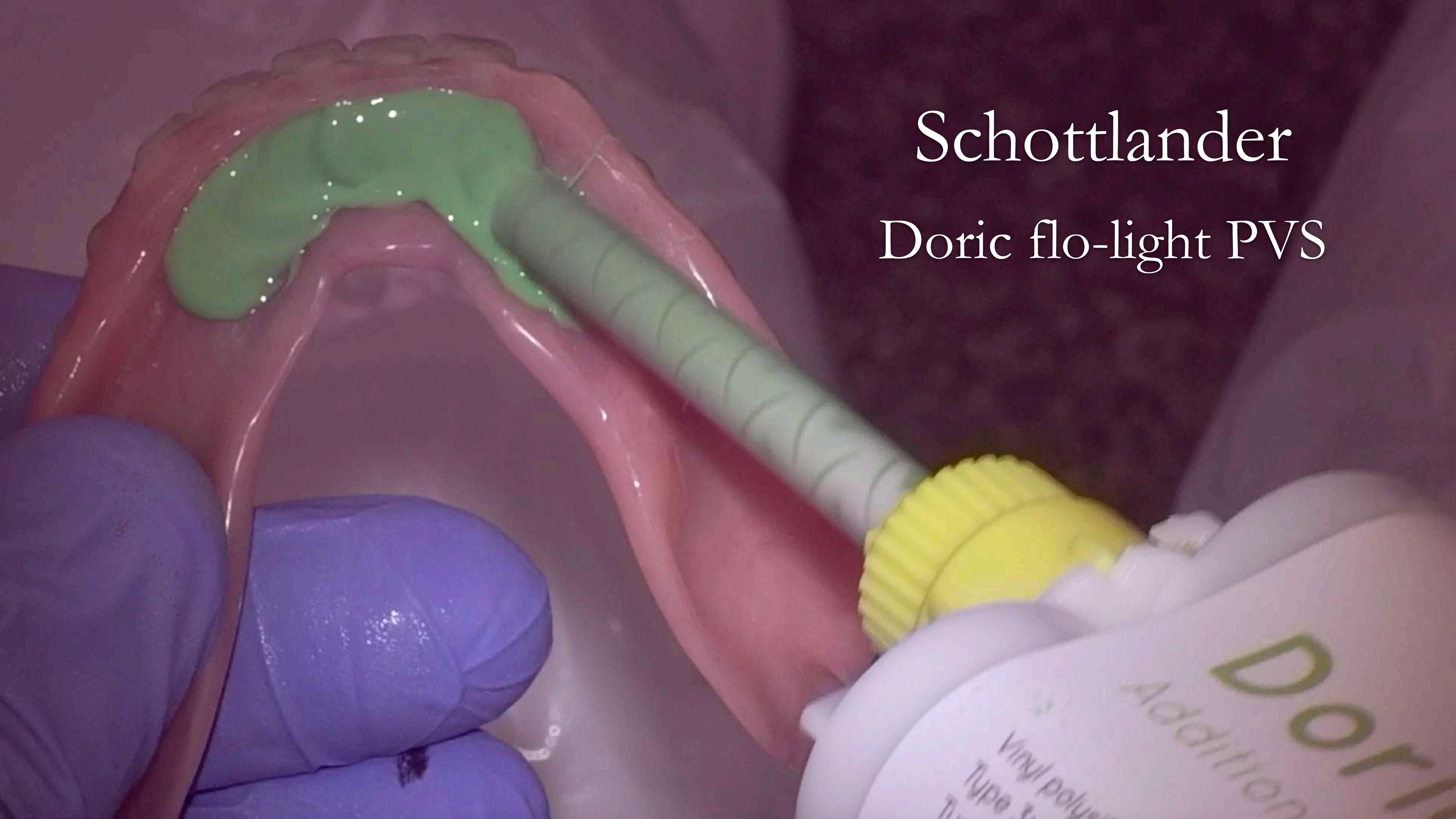
New RPD

Fitting

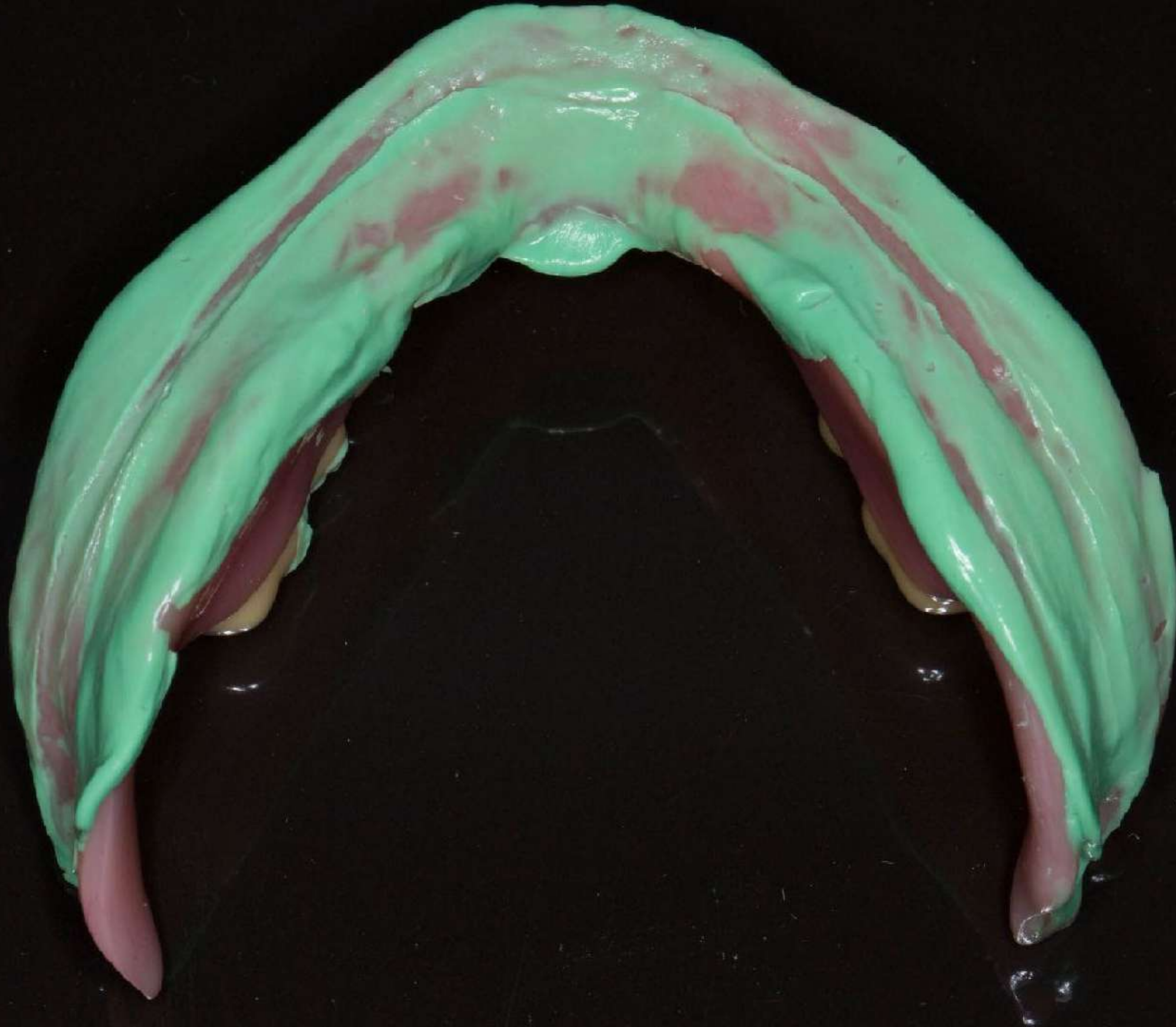


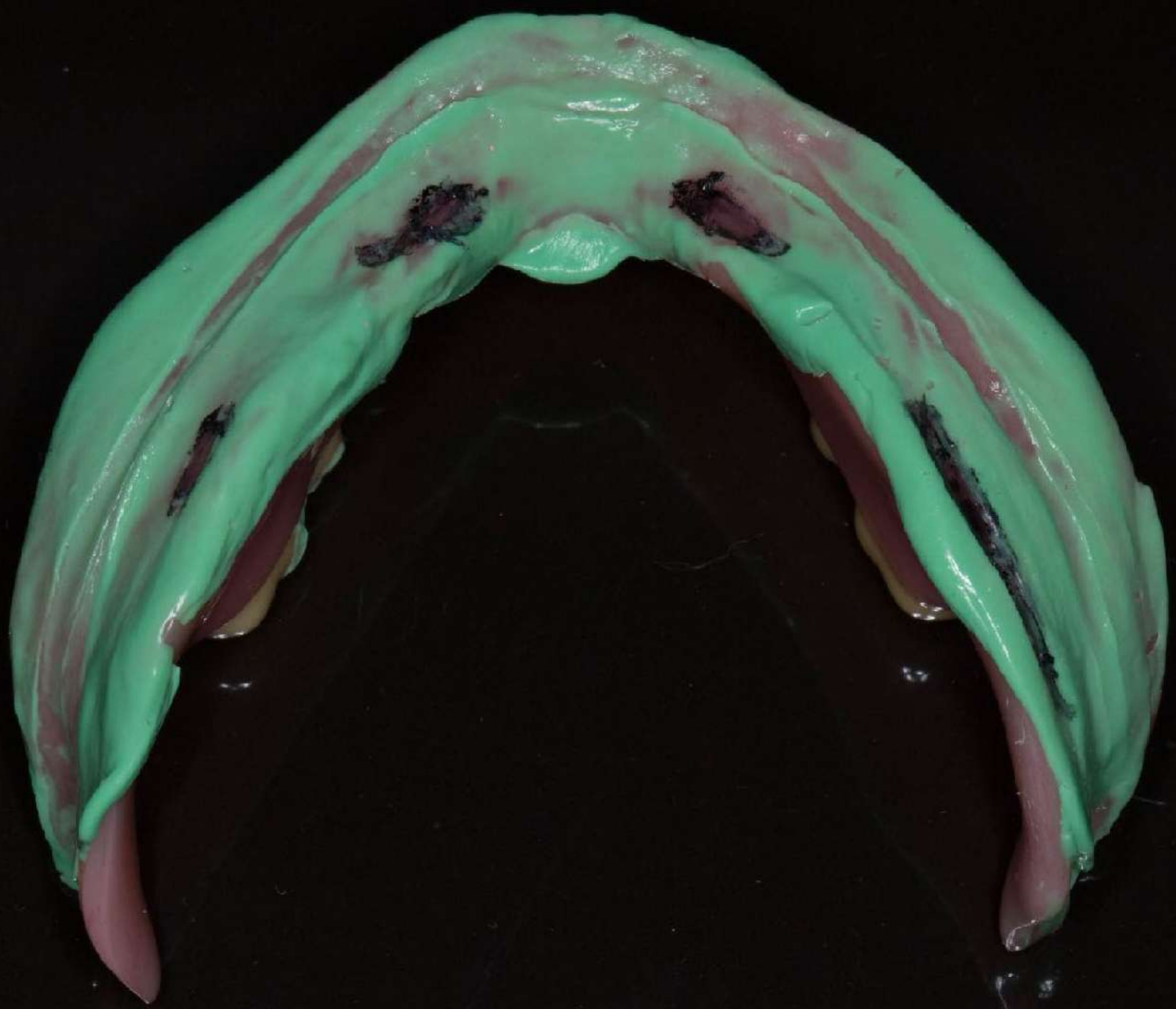Schottlander

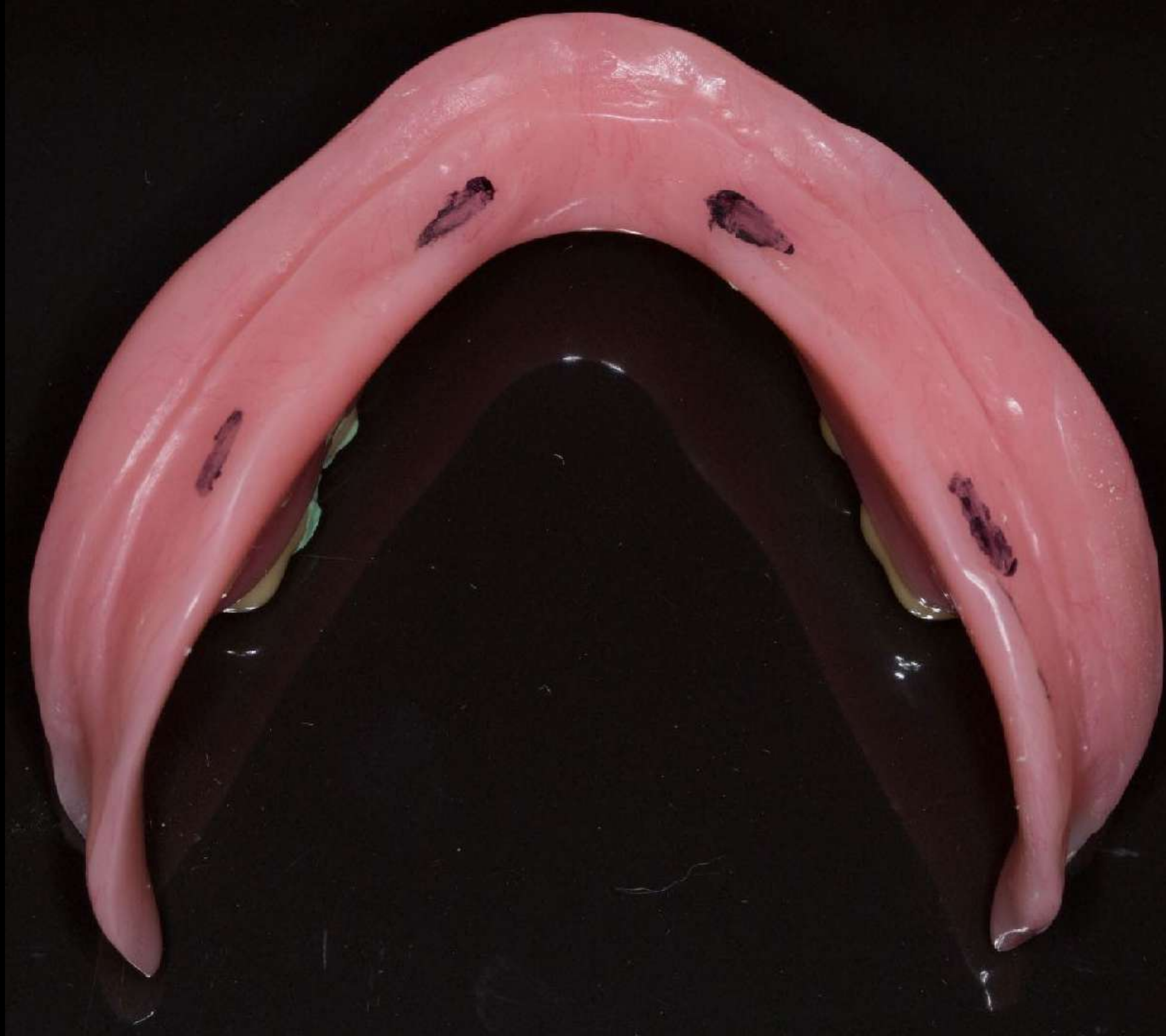Doric flo-light PVS

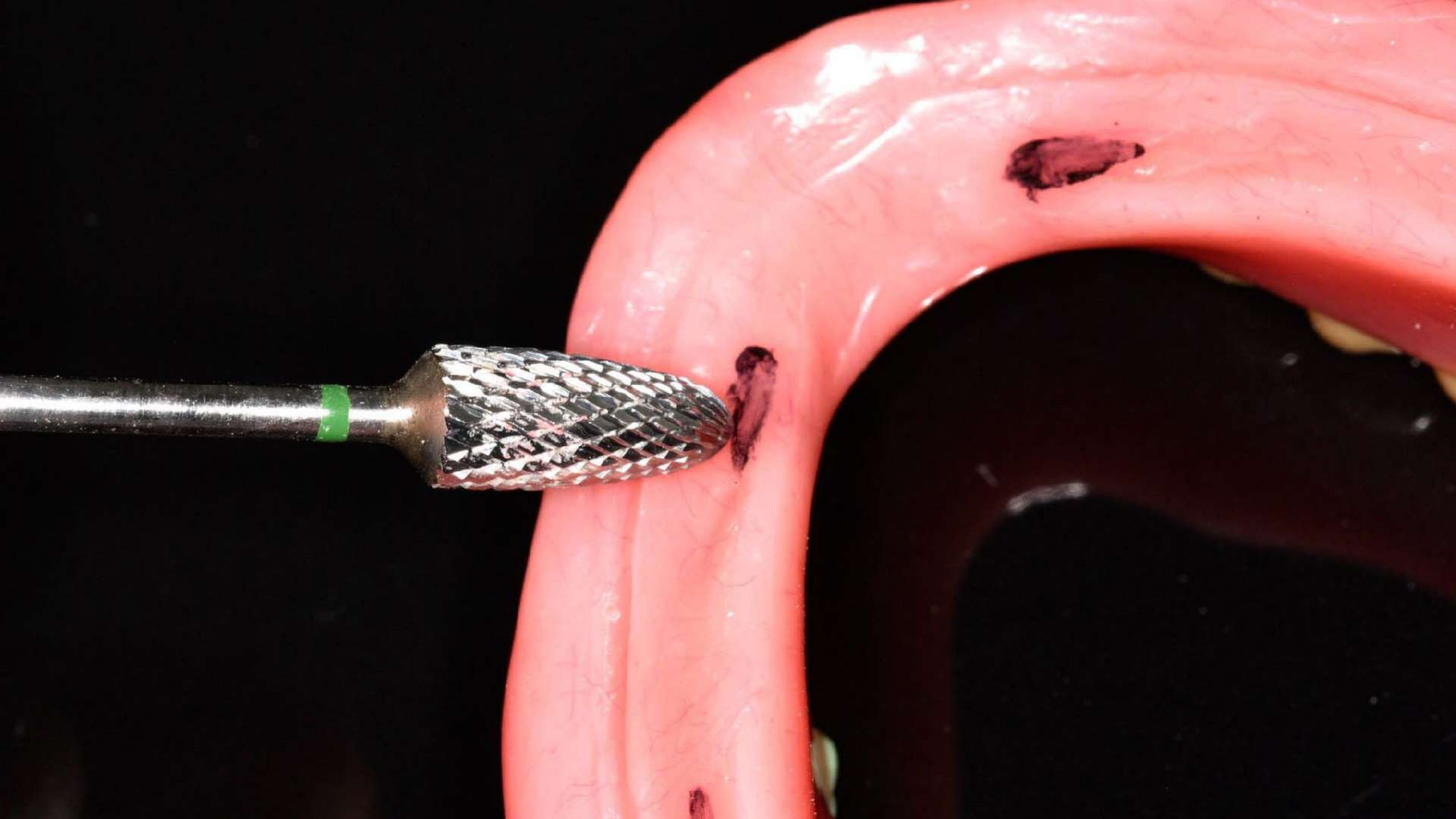


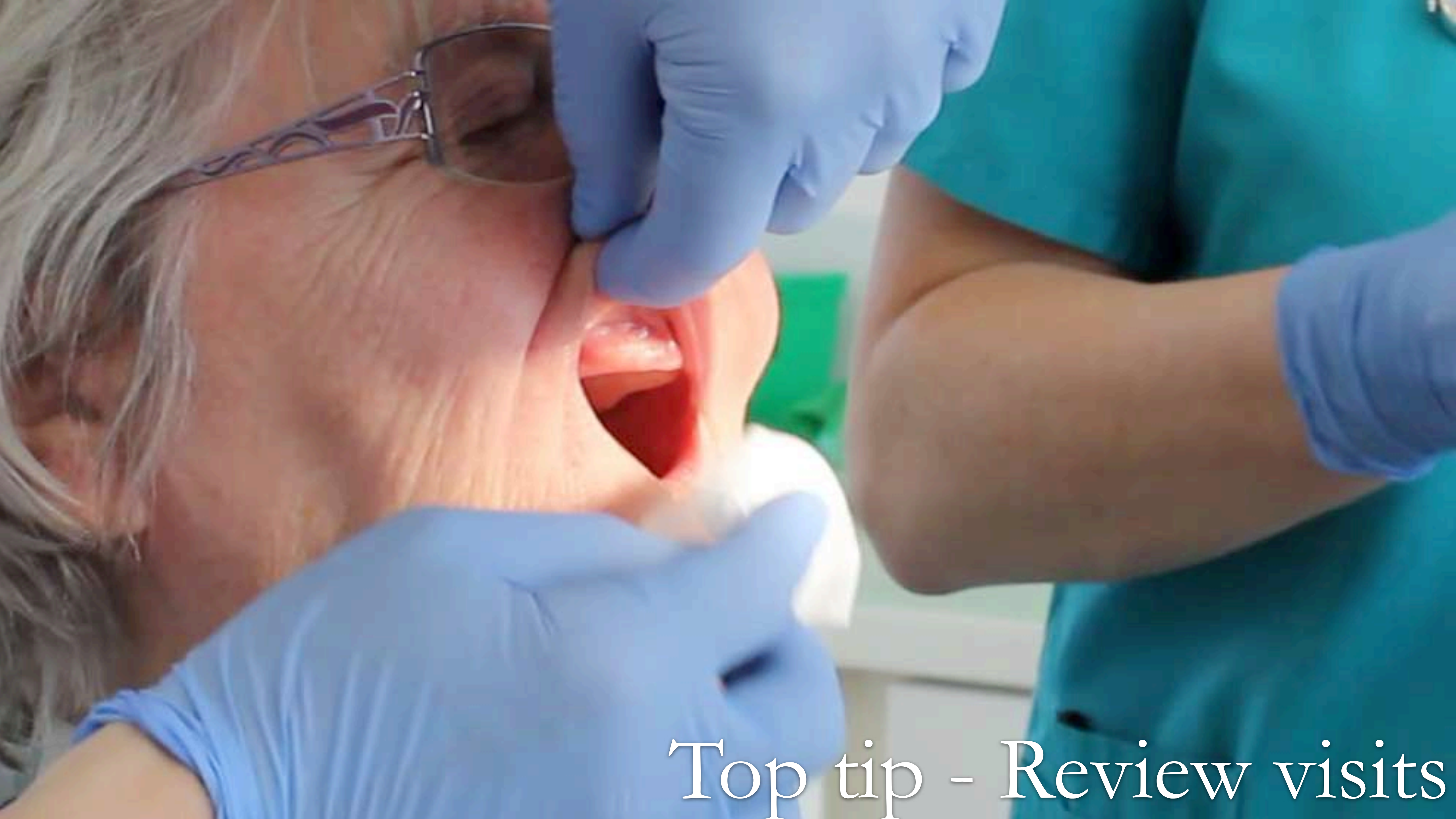Schottlander
Doric flo-light PVS



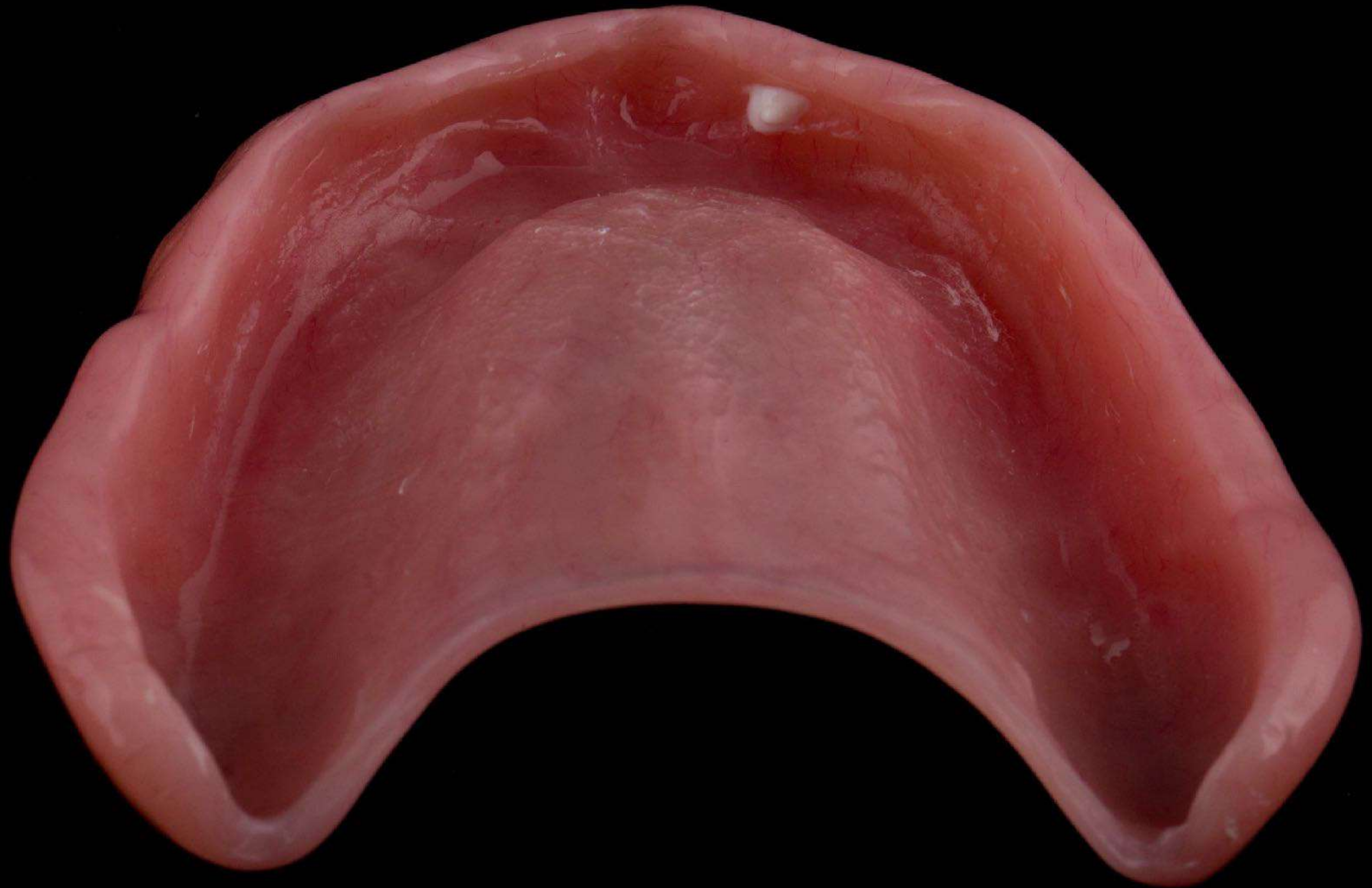

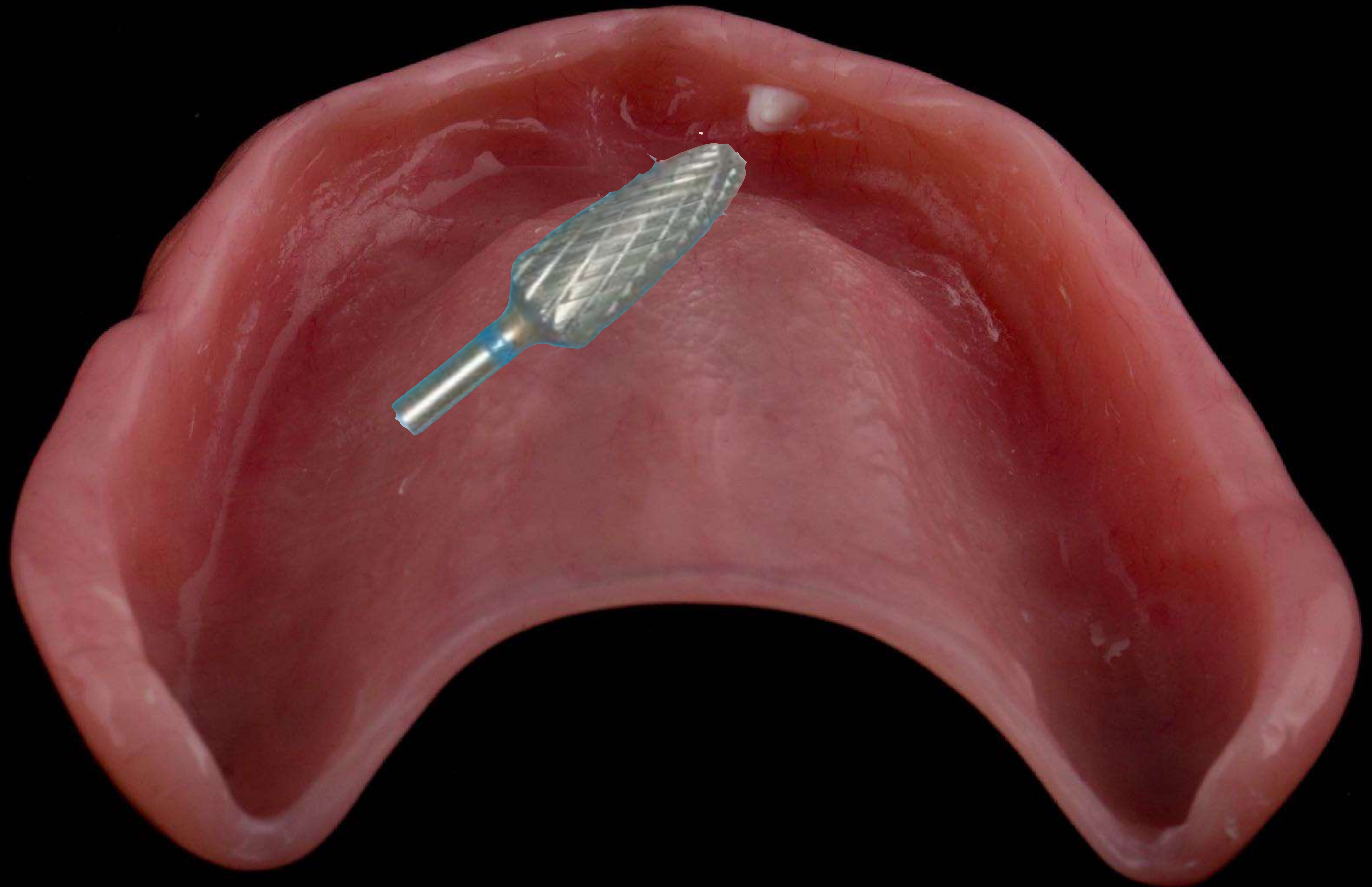





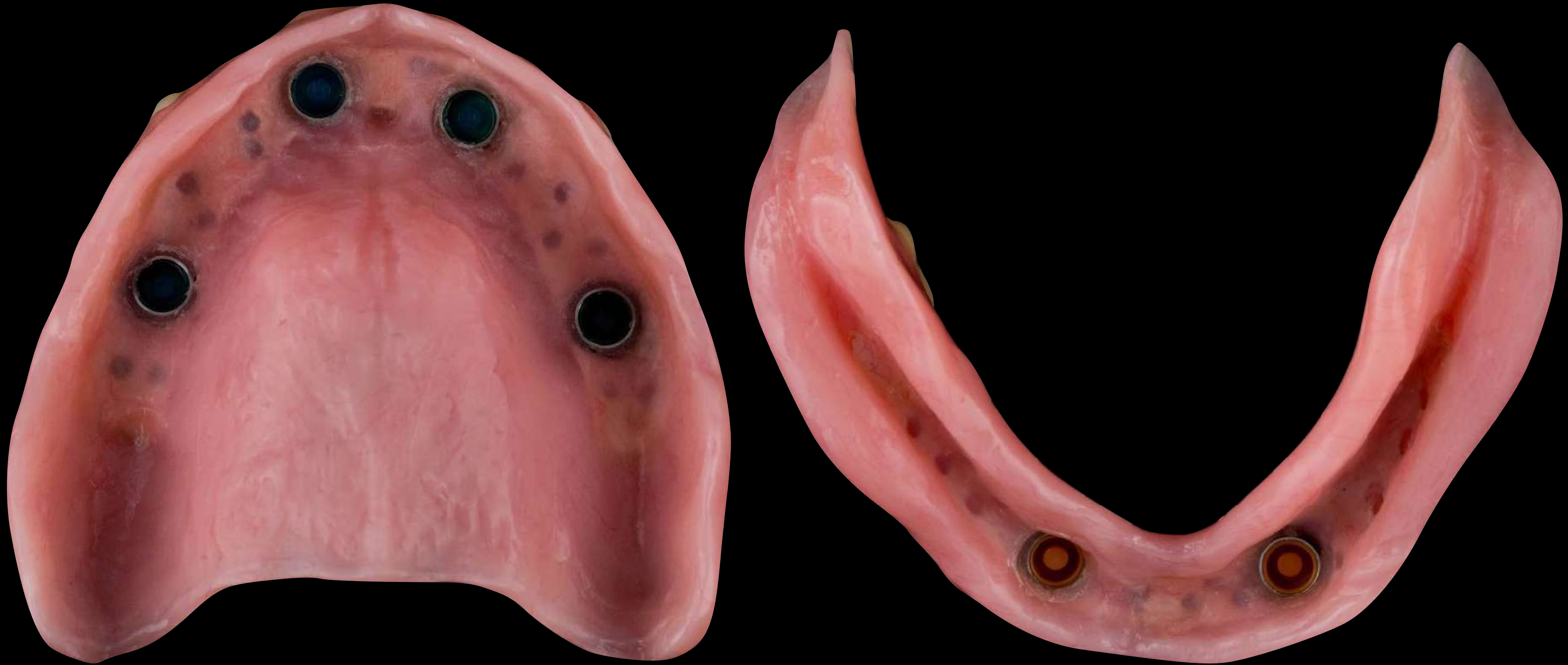
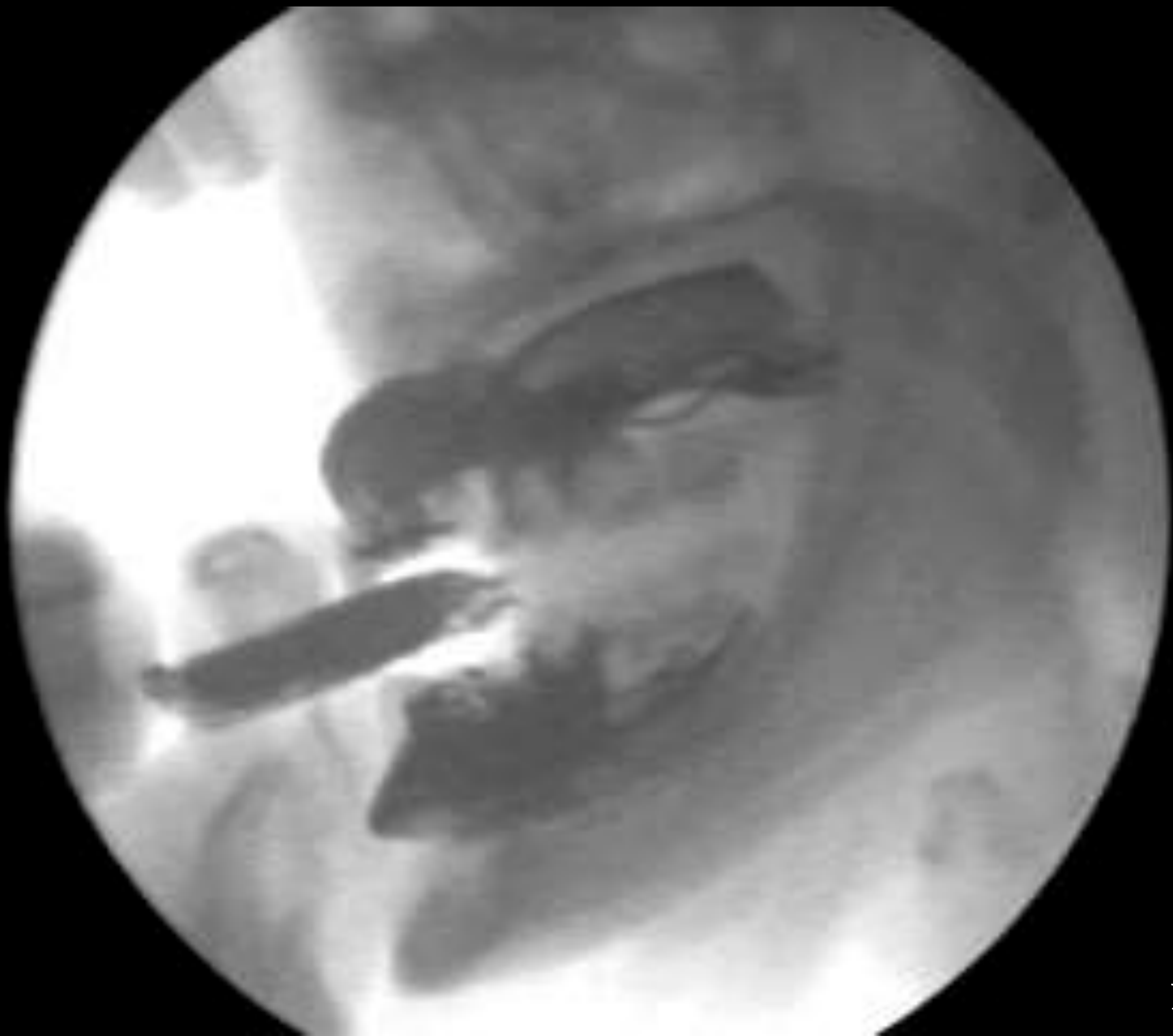
Top tip - Review visits





Implant supported dentures





Prof Roger Watson



Peter



Call to action

1. Dentures v bridges



Call to action

1. Dentures v bridges

2. finlaysutton.co.uk/resources



Call to action

1. Dentures v bridges
2. finlaysutton.co.uk/resources
3. Visit Schottlander



Thank you!



education@finlaysutton.co.uk